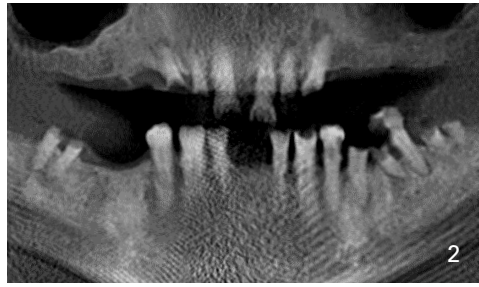
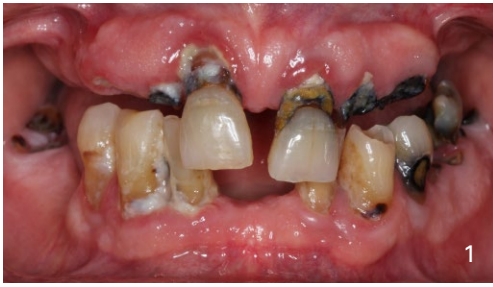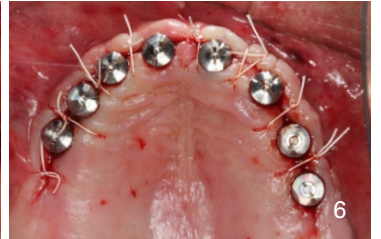
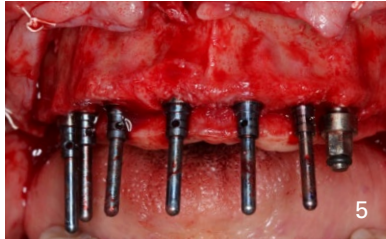
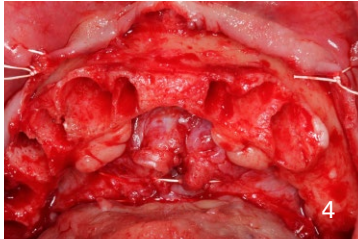
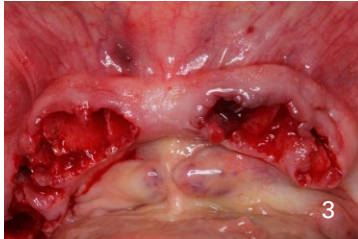


# Treating the Terminal Dentition

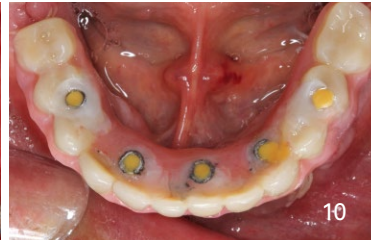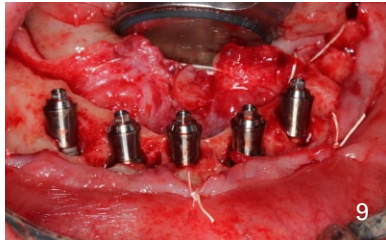
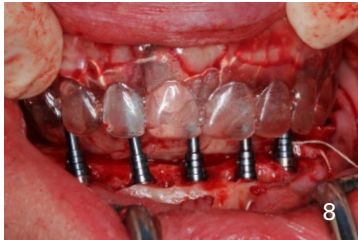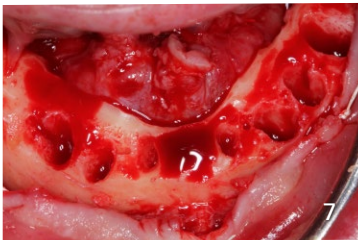
## A Life Transformation



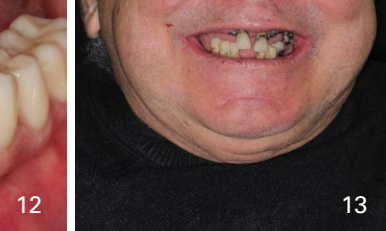
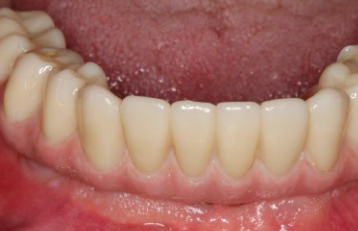
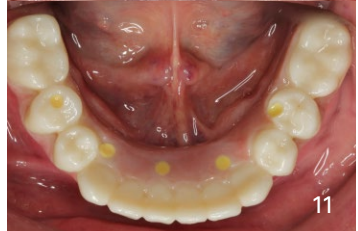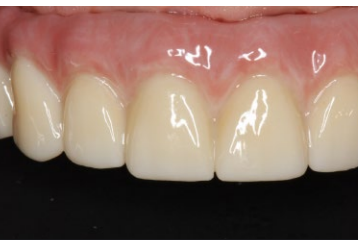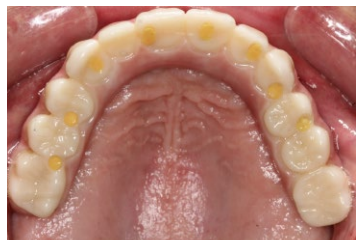1, 2. An otherwise healthy 70-year-old male patient presents with generalized decay and multiple missing teeth. All remaining teeth had poor prognosis and treatment plan was formulated for extractions and implant-supported prostheses in the maxillary and mandibular arches.



3, 5. Under IV sedation, all maxillary teeth were extracted. Sockets were degranulated and grafted with bone allograft.  
6. After five months, implants were placed and later uncovered.



7, 8. Concurrent with the maxillary extractions, the mandibular teeth were removed and an alveolectomy was performed.  
9, 10. Five implants were immediately placed and loaded that day.



11, 12. Three months later the final restoration was placed-maxillary and mandibular zirconia hybrid prostheses.  
13, 14. Restoring dental health led to a return to function and esthetics. The result – a very happy and healthy patient.

Surgical treatment performed by **Dr. Michael Sonick**  
Restorative dentistry performed by **Dr. Min Yoon**

Watch his testimonial here:  
<https://qrco.page.link/RNDbS>



**Fairfield County Implants & Periodontics**  
**Dr. Michael Sonick, Dr. Rui Ma, Dr. Stephanie Koo & Associates**  
*Creating Beautiful Healthy Smiles for a Lifetime*

1047 Old Post Road  
Fairfield CT 06824  
203-254-2006  
office@sonickdmd.com  
www.sonickdmd.com