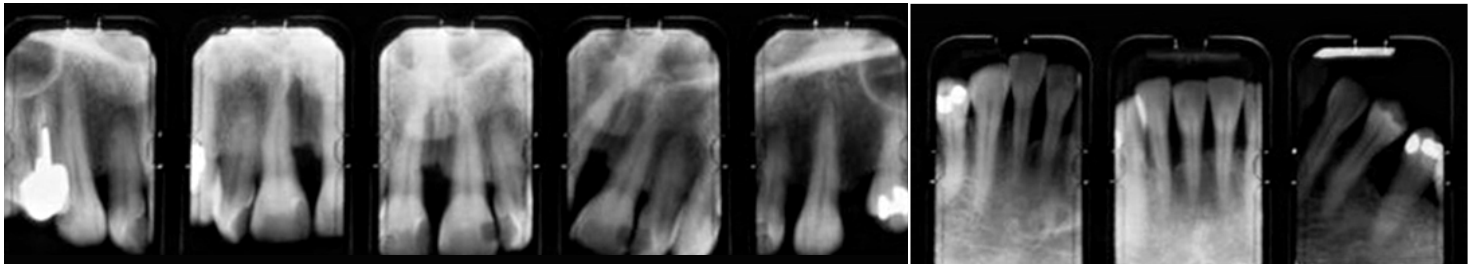
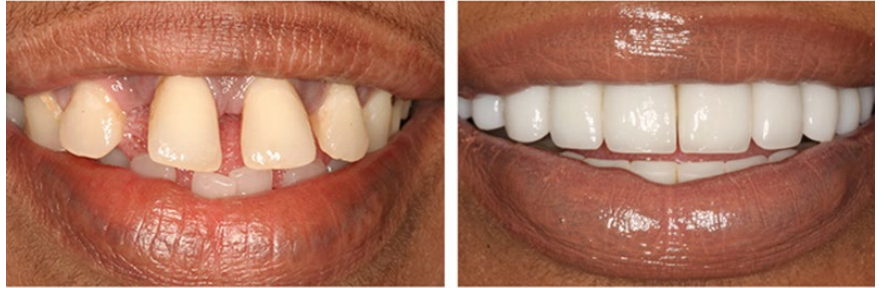

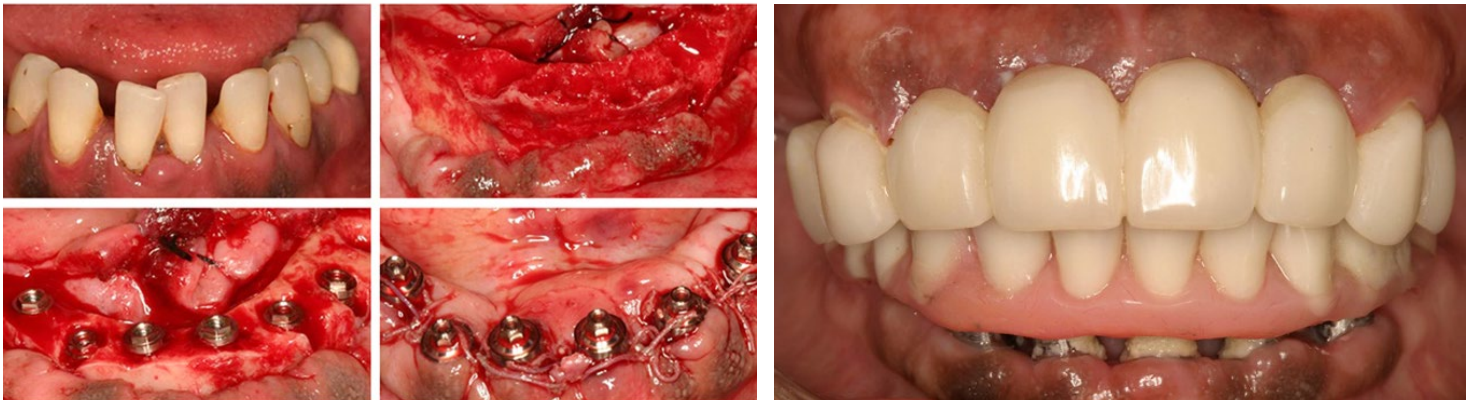
Full Mouth Dental Rehabilitation

Transitional Maxillary Implant Restoration with Immediate Loading of the Mandible - Page 1

The transition of the hopeless dentition into an immediate implant supported fixed restoration is now a predictable clinical reality. Ten years of published clinical data reveal a success rate approaching 95%. Patients crippled by dental disease, poor function and fear can now be provided with a fixed non-removable restoration within a few hours.

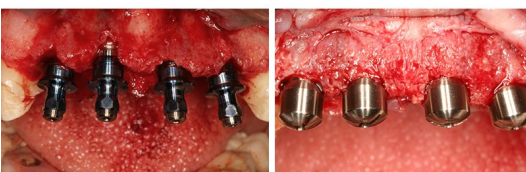


A 42-year-old female patient presents with a hopeless dentition. Dentally phobic, the patient has not visited the dentist often. Radiographs reveal 80 - 90% bone loss and prognosis for remaining teeth is poor. A decision to restore the maxilla with fixed PFM was made. In the mandible it was elected to extract all teeth, place and immediately load implant the same day.



Under IV sedation all the mandibular teeth were extracted and the sites degranulated. Following alveolectomy, 6 implants were placed. Transitional abutments were then placed onto the implants and torqued to 20 N-cm. Closure of the flap was completed with interrupted synthetic absorbable sutures.

In the mandible, temporary cylinders were then screwed into the abutments and hand tightened with laboratory screws. A previously made mandibular complete denture was then secured to the temporary cylinders with acrylic and secured to the abutments with gold retaining screws. All maxillary teeth were removed and bone grafted except for teeth 6 and 11. A metal reinforced 8-unit bridge was secured to the maxillary canines and the patient could heal.

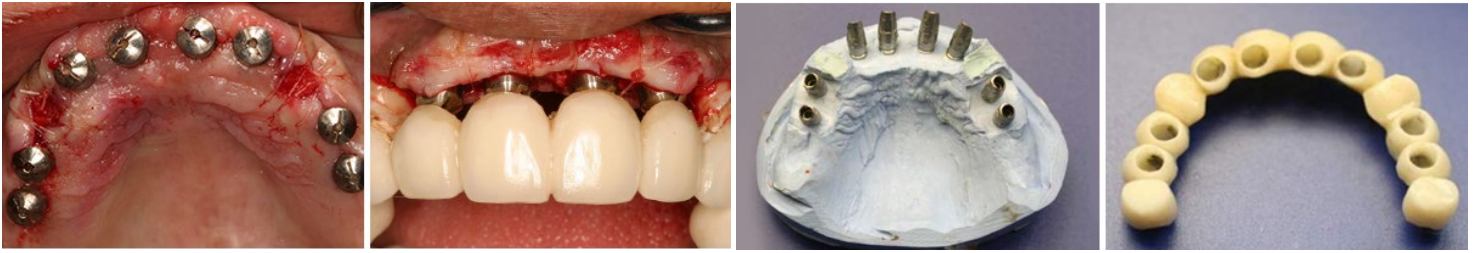


Six months following extraction 8 maxillary implants were placed and grafted with bone allograft, autogenous bone and bovine membranes. Six months later the implants were uncovered and temporary healing abutments placed. Note the excellent bone regeneration which has become routine in implant dentistry.

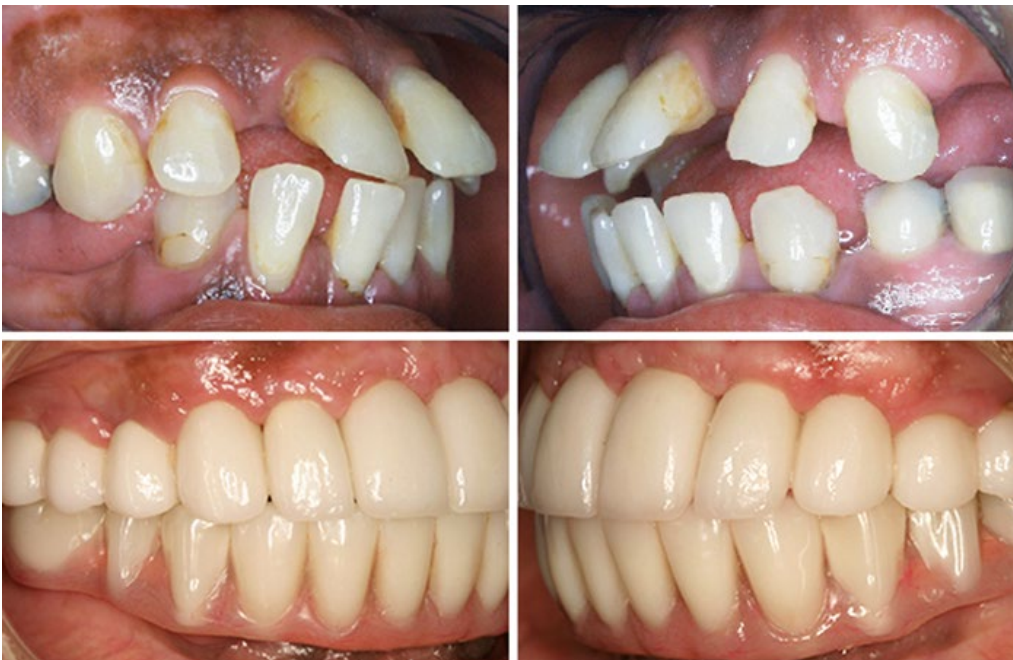

Full Mouth Dental Rehabilitation

Transitional Maxillary Implant Restoration with Immediate Loading on the Mandible - Page 2

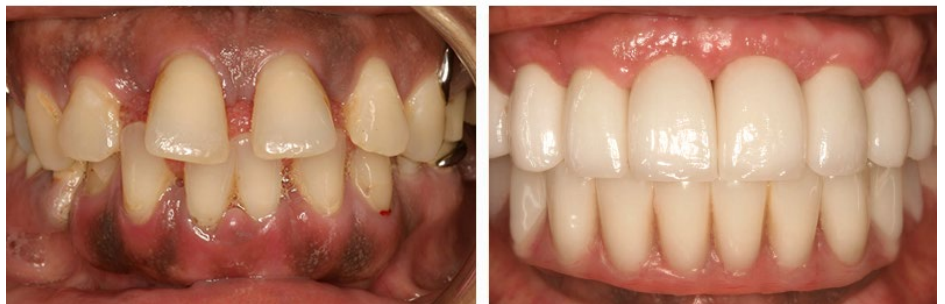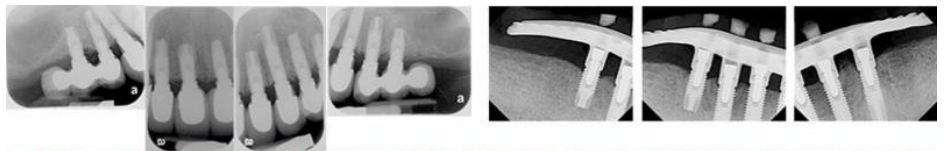


The canines were then extracted and immediate implants placed. The previously placed 8 maxillary implants were then provisionally loaded. Four months later the canines will be incorporated into the prosthesis.



Lateral views of the initial and final restorations

THIRTEEN years following treatment, radiographs reveal well integrated implants and an intimate fit of the one-piece bar and abutments to the implants. Final restoration of the maxilla, with individual anterior PFM implant supported crowns and the mandible with a fixed hybrid restoration reveal esthetic harmony and excellent occlusion and function.



Surgical treatment performed by
Dr. Michael Sonick

Restorative dentistry performed by
Dr. Mark Samuels



Fairfield County Implants & Periodontics
Dr. Michael Sonick, Dr. Rui Ma & Associates
Creating Beautiful Healthy Smiles for a Lifetime

1047 Old Post Road
Fairfield CT 06824

203-254-2006

office@sonickdmd.com

www.sonickdmd.com

