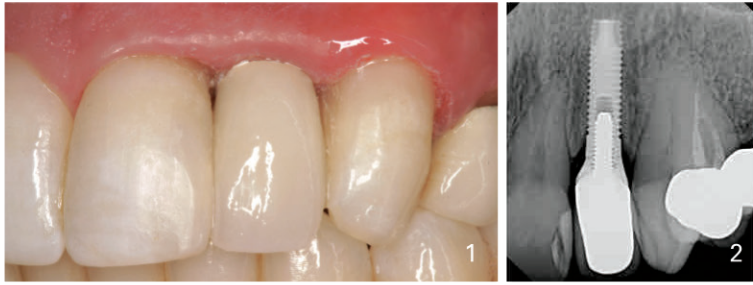
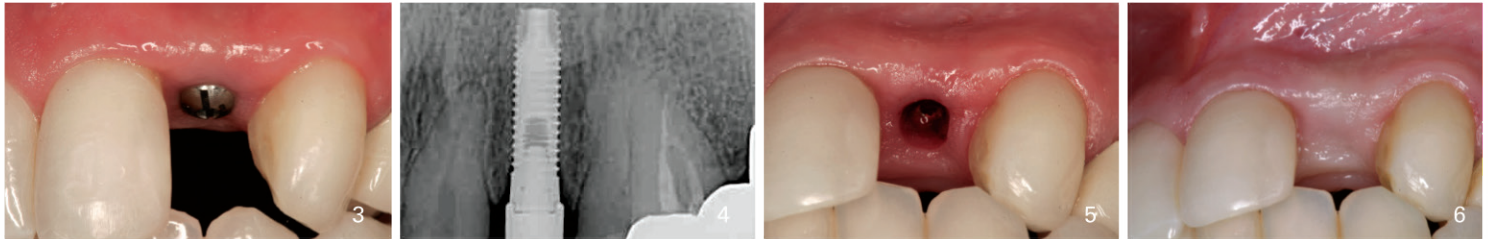


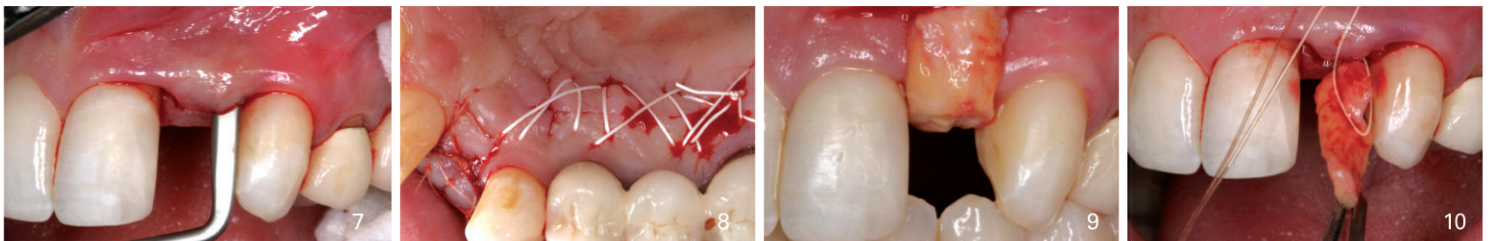
Rescue Therapy for an Esthetically Compromised Maxillary Anterior Implant



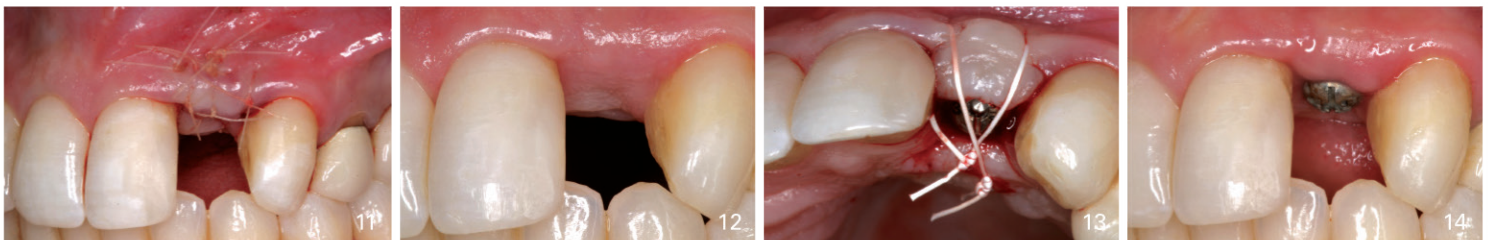
This 42 year old dental assistant was unhappy with the final esthetics of the dental implant replacing tooth N°10. Papillary loss and buccal recession is present (1,2).



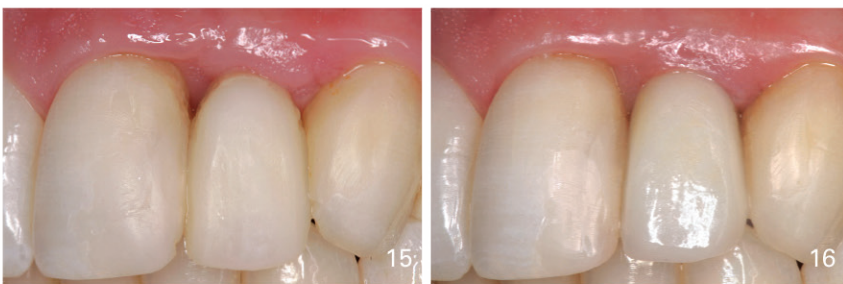
A decision was made to bury the dental implant and attempt to regenerate the soft tissue. A temporary healing abutment was placed (3,4) followed by the placement of a cover screw (5). Four weeks later soft tissue close was present (6).



A split thickness flap was elevated over the buccal of the dental implant (7) and a connective tissue graft was harvested from the palate (8). Utilizing a purse string suture the CTG was placed buccally and coronal to the dental implant (9, 10).



5-0 gut sutures were used to stabilize the CTG (11). Eight weeks following CTG an increased soft tissue volume is noted (12). A second stage surgery utilizing guided gingival growth was performed to further augment the soft tissue (13, 14).



The patient was placed into a screw retained provisional restoration for 12 weeks in order to guide the soft tissue profile and establish ideal esthetics (15). Completed final restoration. Papilla has been regenerated and the buccal soft tissue margin is more coronal resulting in a more pleasing smile (16). Compare to the original image (1).

Surgical treatment performed by **Dr. Michael Sonick**
Restorative dentistry performed by **Dr. Marilyn Geni**

