

Papillary Retention Flap Design for Pocket Reduction/Regeneration: Case Series With Long-Term Follow-Up

Michael Sonick, DMD; Rui Ma, DMD; and Debby Hwang, DMD

Abstract: Many papillary preservation flap techniques exist for both resective and regenerative purposes. This article describes a papillary retention design based on palatal access showing a successful long-term outcome. The papilla preservation approach detailed here, which is a modification of Friedman's beveled flap for the palate, circumvents any manipulation of interproximal or buccal tissue, leaving papillary tissue untouched. Indications for this approach are very specific and its application is somewhat limited. However, the aim of the papillary retention flap as discussed is to eradicate pocket depths exceeding 5 mm and possibly regenerate hard and connective tissue in these exclusive locations. This strategy may permit access to the labial portion of the interproximal root in particular cases.

The treatment of periodontitis ideally involves pathogen removal, modification of the host immune response, and regeneration of lost hard- and soft-tissue structures. Fully realizing any, let alone all, of these objectives may be unattainable whether using nonsurgical or surgical treatment. However, a relatively acceptable clinical compromise exists: If the practitioner achieves at least pocket reduction, then the patient, using adequate oral hygiene methods and adhering to a stringent professional maintenance schedule, can sustain those shallower pockets, thus avoiding further deterioration. Of course, pocket reduction often occurs because of retraction (or resection) of inflamed gingiva during or after treatment rather than a tangible gain in connective tissue attachment. In a patient with a compromised maxillary anterior sextant, treatment, including scaling and root planing (SRP) alone, can cause the "black triangle disease" of papillary reduction even as it manages periodontal disease.

Patients need to be made aware of potential soft-tissue recession and its consequences (eg, food retention, speech difficulties, cosmetic issues) after initial nonsurgical therapy. Clinicians are able to influence to a certain extent the level of mucosal revision during surgery by designing flaps that minimize changes in papillary anatomy. Many papillary preservation flap techniques exist for both resective and regenerative purposes.¹⁻¹⁰ A systematic review and meta-analysis of access-flap surgery from 2012 suggested that papilla preser-

vation flaps statistically gained more clinical attachment and better curbed marginal recession than conventional designs, though no study included directly compared the two approaches.¹¹ A 2017 randomized control trial weighed traditional access flaps against the modified papilla preservation technique (MPPT) and did so in the long term; there were no significant differences in clinical attachment level after 20 years between the groups when titanium-reinforced expanded polytetrafluoroethylene (ePTFE) membranes were used in both settings (access flaps without membrane lost more attachment over time than both regenerative groups).¹² A separate case study documented results of MPPT use with interproximal alloplastic grafting over 22 years.¹³ The authors recorded stable papillary morphology during that period but noted mid-facial recession that they attributed to toothbrush abrasion.

The two reports cited above^{12,13} notwithstanding, very few long-term follow-up studies of papilla preservation methods are in the literature. This article introduces a papillary retention design based on palatal access with a 28-year outcome. A modification of Friedman's beveled flap for the palate, the papilla preservation approach detailed here avoids any manipulation of interproximal or buccal tissue.¹⁴ Therefore, there are very specific indications and limitations for its application. Indications include palatal-only suprabony defects, palatal-only infrabony defects, and interproximal infrabony defects with an intact buccal wall. For esthetic areas, a contraindication would be buccal pocketing >4 mm (suprabony defects), and SRP would need to

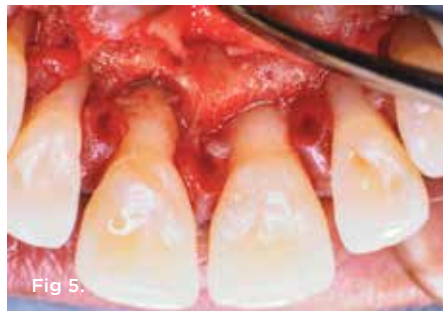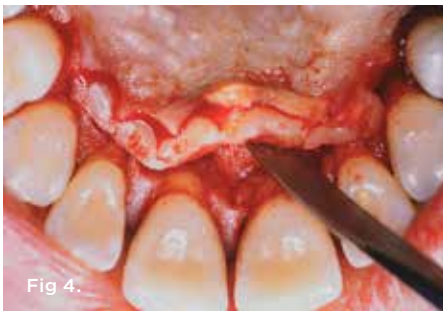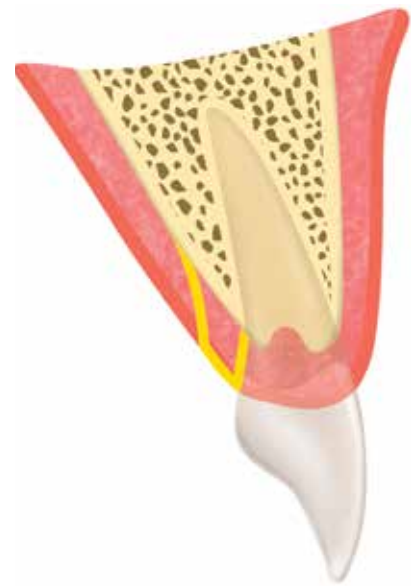
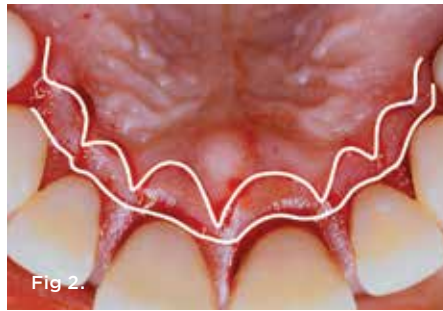


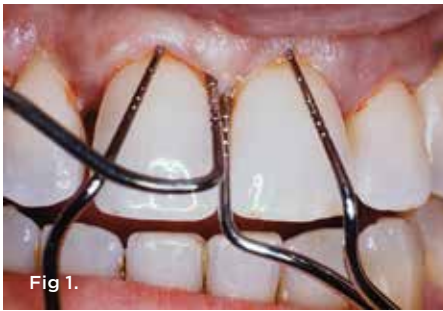Fig 3.

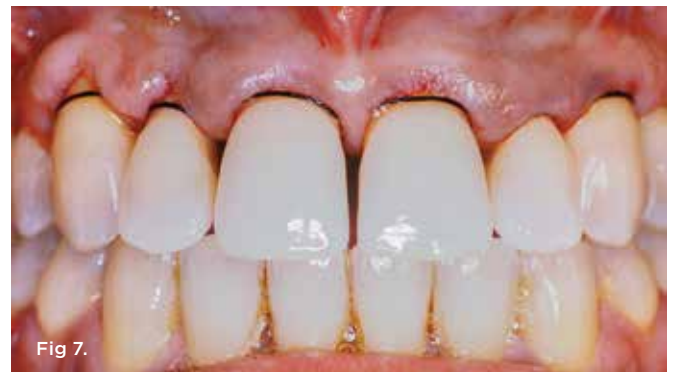
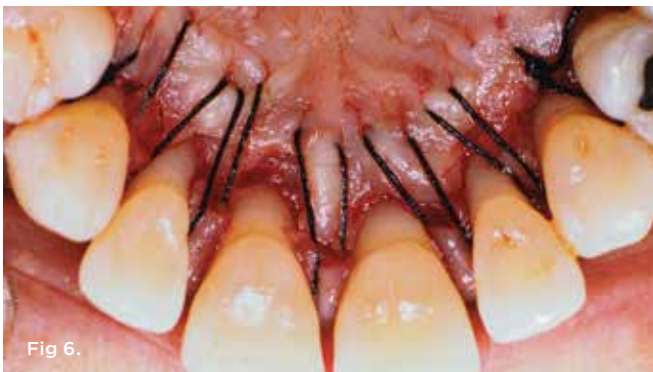
Fig 1. After SRP, pocket depths greater than 5 mm remained. **Fig 2.** The initial incision, as shown by the inner line drawing, is internally beveled and scalloped. Designed to thin the palatal flap enough so that it lies passively at the crest of alveolar bone, this incision is carried laterally to the line angles of the most distally involved teeth and ends palatally on bone. A secondary parallel incision is made sulcularly but does not include interproximal tissue and extends to the alveolar bone. **Fig 3.** Diagram showing the initial internal bevel palatal incision and the sulcular incision. Note that the tissue to be excised is still attached to the palatal alveolar bone. **Fig 4.** A full-thickness flap extending between the two parallel incisions is raised. This wedge of tissue is removed. **Fig 5.** The palatal wedge of tissue is removed, thus allowing access for root planing, osseous contouring, and/or bone regeneration. The excised mucosa may be used as connective tissue graft donor material. **Fig 6.** Palatal view after suturing. After root planing and treatment of the bony defects, the palatal flap is repositioned. Horizontal mattress sutures used in conjunction with a continuous sling can achieve close approximation of the palatal tissue to the bone. Note that the palatal aspect of the interproximal papillae may heal by secondary intention, though further tissue thinning could be performed to achieve primary closure. **Fig 7.** Buccal view after suturing. Sutures did not pass through buccal tissue in this case.

be completed presurgically. For palatal pocketing >5 mm (suprabony defects), a contraindication would be infrabony defects involving buccal surfaces, and excellent oral hygiene would be required presurgically. For infrabony defects limited to the palatal side or interproximal tooth aspects with an intact buccal wall, a contraindication would be a need for facial prosthetics and subsequent crown lengthening, while a presurgical requirement would be that the patient commit to a strict periodontal maintenance regimen, eg, every 3 months.

The aim of the papillary retention flap is to eradicate pocket depths exceeding 5 mm and, if possible, regenerate hard and connective tissue in these exclusive locations. This strategy may permit access to the labial portion of the interproximal root in particular

cases but will not be able to treat buccal-only bony defects. Also, to reiterate, another contraindication involves restorative-driven crown lengthening that obligates a facial prosthetic margin.

Technique

The technique, which is illustrated both overall and in three separate cases in Figure 1 through Figure 25, consists of a nonsurgical phase and a surgical phase. The nonsurgical phase comprises SRP, which must be completed prior to surgery. Establishment of non-edematous gingiva and strict plaque control at this initial treatment stage is imperative. Without presurgical control of inflammation, postsurgical recession becomes unpredictable.

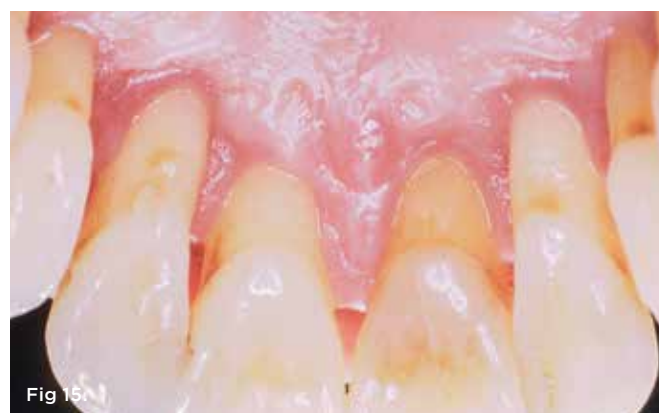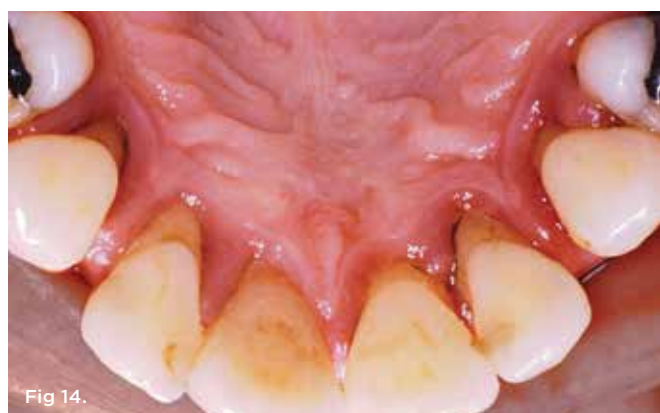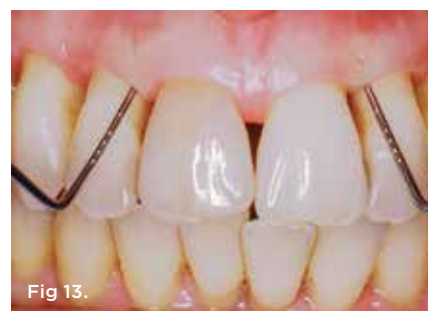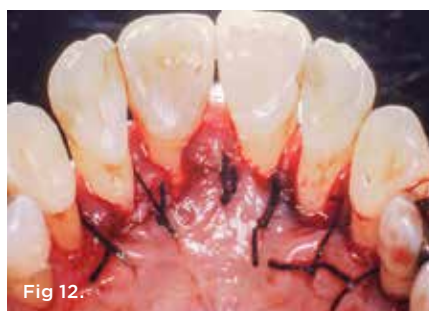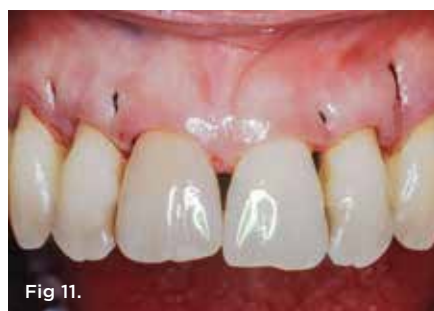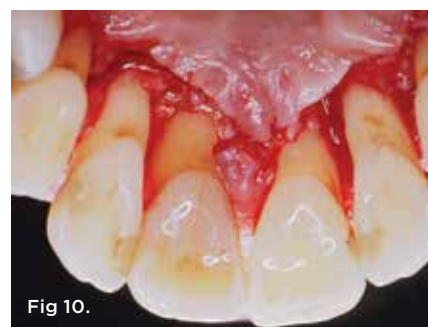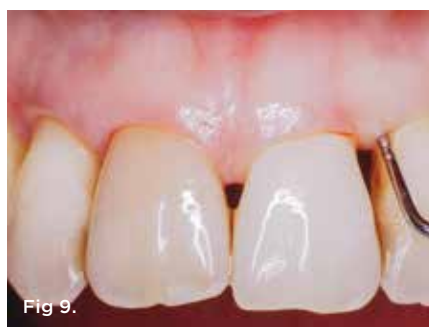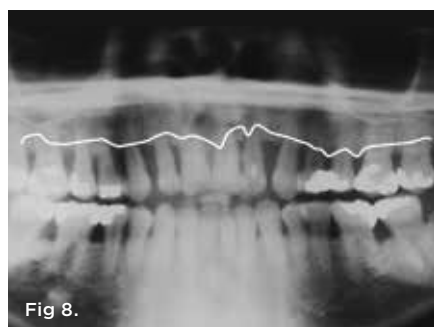


Fig 8. This 34-year-old woman presented with generalized aggressive periodontitis. She had experienced rapid attachment loss with up to 50% loss of alveolar bone as evidenced by this panoramic radiograph. **Fig 9.** The patient after customized oral hygiene instructions were given and SRP was performed. Note the quality of the soft tissue and minimal visible inflammation. However, 8 mm interproximal probing depths still remained on the day of surgery. **Fig 10.** Palatal flap was elevated using the papillary retention design. The buccal flap and papillae were not elevated. **Fig 11.** Use of individual interproximal vertical mattress sutures enabled a more tension-free closure, which minimized papillary recession. **Fig 12.** The knots of the sutures were placed palatally to avoid further cosmetic compromise during healing. Silk sutures were used in this case, but the authors recommend 5-0 or 6-0 ePTFE or polyglactin sutures for periodontal surgery to prevent bacterial wicking. **Fig 13.** Three years after surgery, pocket depths were 2 mm to 3 mm. **Fig 14 and Fig 15.** Palatal view at initial presentation (Fig 14) and 3 years post-surgery (Fig 15). At initial presentation, note heavy calculus, gingival inflammation, rolled gingival margin, and palatal gingival recession. At 3 years post-surgery, note the improved gingival health and maintenance of the interproximal papillae with apical positioning of the palatal tissues.

Once the clinician has re-evaluated the patient after implementing infection control and selected the papillary retention treatment based on the conditions outlined above, the surgical phase proceeds. Use of the papillary retention flap completely avoids the need to manipulate the interproximal mucosa coronal to the cemento-enamel junction (CEJ). Repositioning only the palatal tissue generates pocket elimination. The initial horizontal, internally beveled incision is made at approximately half the depth of the palatal pockets (Figure 1 through Figure 4), depending on the depth of the palatal vault. A palate with a deeper vault (and, accordingly, a greater amount of palatal mucosa) will require that the incision line start 1 mm to 2 mm coronal to the

depth of the pockets. The initial incision line in a shallower palate begins at 50% the depth of the palatal pockets. In either case, the initial incision ends at the distal line angles of the most distally involved teeth and remains a scalloped, nonsulcular design.

A second, parallel and coronally oriented incision is created that is sulcular and angled toward the bony crest (Figure 2 through Figure 5). Again, the interproximal tissue (at least coronal to the CEJ) is left untouched. Once this second incision is completed, the soft tissue between the scalloped and sulcular incisions is elevated to full thickness and removed (Figure 4 and Figure 5). Degranulation reveals any palatal or interproximal osseous

defects, which may then be treated with root planing in combination with recontouring or regeneration, as needed. Access to the buccal aspect of the proximal root surface is possible contingent on the type of defect present. Regeneration of amenable vertical defects may proceed with the use of the clinician's materials of choice; the authors typically use freeze-dried bone allograft and an absorbable collagen membrane. Root conditioning may be applied to debrided and exposed root surfaces prior to grafting, as desired. Biologic modifiers such as enamel matrix derivative, platelet-rich fibrin, platelet-rich plasma, bone morphogenetic protein, or other bioinductive agents may be mixed into the graft.

The palatal flap is sutured to the intact interproximal and buccal mucosa using horizontal or vertical mattress sutures and sling sutures (knotted palatally) to provide close adaptation of the flap to bone as illustrated in Figure 6 and Figure 7, Figure 10 and Figure 11, and Figure 19. Because the palatal soft tissue is thinned by internally beveling the incisions and excising mucosa in between the incision lines, primary closure can be attained for regeneration (further thinning of the palatal mucosa or bony prominences may be required for edge-to-edge flap approximation); however, often secondary intention healing is expected and sufficient to realize surgical goals.

Case 1: Generalized Aggressive Periodontitis With 3-Year Follow-Up

A medically healthy, nonsmoking 34-year-old woman presented with significant horizontal and vertical bone loss. The periodontal diagnosis was generalized aggressive periodontitis. The panoramic radiograph showed at least 50% loss of alveolar bone generally (Figure 8). Initial interproximal pocket depths were 6 mm to 9 mm with facial probing of 3 mm to 4 mm. Initial therapy consisting of oral hygiene instructions and four visits of SRP was completed.

After initial phase healing, the gingiva appeared less inflamed with proximal recession (Figure 9). Surgical therapy was undertaken utilizing a papillary retention procedure from the mesial of tooth No. 5 to the mesial of tooth No. 12 (Figure 10 through Figure 12). The palatal and interproximal root surfaces, including the buccal aspect of the proximal root, were debrided. Suturing was performed using simple interrupted and vertical mattress methods (Figure 11 and Figure 12). Use of vertical mattress sutures helped to prevent further black triangle-type retraction post-surgery by minimizing tension at the incisal tips of the papillae.

Healing was uneventful, and the patient kept to a 3-month periodontal maintenance schedule. Three years following surgery, the patient continued to be periodontally stable with probing depths of 3 mm or less (Figure 13). There appeared to be no significant facial or papillary recession over time and the gingival margin on the palatal tissue remained at an apical level (Figure 14 and Figure 15).

Case 2: Generalized Severe Chronic Periodontitis With 31-Year Follow-Up

This medically healthy, nonsmoking 42-year-old male patient presented with generalized severe periodontal disease (Figure 16 and Figure 17). Initial mobility of the maxillary anterior teeth was grade 1 to 2 with interproximal pocket depth ranging from 7 mm to 9 mm. Initially, the palatal pocketing was 8 mm. Facial pocketing was 2 mm to 3 mm. The patient

noticed that his teeth were moving and flaring buccally. Diastemata became apparent, and the patient was concerned about esthetics.

Along with providing the patient oral hygiene instructions, initial therapy consisting of full-mouth SRP was completed. Facial pocketing was 1 mm to 2 mm. However, palatal pocketing remained 8 mm (Figure 18). After initial therapy, the anterior maxillary sextant was treated with a palatal papilla retention procedure (Figure 19). Following periodontal therapy, minor orthodontic treatment was performed to correct spacing issues and malocclusion.

The patient faithfully adhered to a 3-month periodontal maintenance schedule over 31 years. His dental hygiene remained excellent while probing depths stayed shallow. Pre-intervention and post-treatment probing measurements demonstrated significant and preserved improvement post-surgery (Figure 20 and Figure 21). Thirty-one years after periodontal surgery, the radiographic bone appeared to improve in density and volume despite having no regenerative procedures performed (Figure 22).

Case 3: Maintained "Hopeless Dentition" With 28-Year Follow-Up

This patient, a medically healthy, nonsmoking 38-year-old man, presented for periodontal analysis after being informed that he required full-mouth extraction. The diagnosis was generalized severe aggressive periodontitis (minimal local factors detected) with 60% to 70% radiographic bone loss (Figure 23). Interproximal and palatal periodontal pocketing ranged from 6 mm to 9 mm with minimal facial pocketing. Generalized mobility was present.

The patient was given oral hygiene instructions and treated with full-mouth SRP. Pocketing greater than 6 mm persisted after initial therapy, and surgical treatment was elected to further decrease pocketing to facilitate maintenance. Posteriorly, conventional modified Widman flap surgery was performed.¹⁵ In the maxillary anterior sextant, the papillary retention procedure was implemented without guided tissue regeneration. The patient was placed on a 2- to 3-month maintenance protocol.

Twenty-eight years later the patient had retained all of his teeth except for one, which failed endodontically. No further alveolar bone loss was apparent, and attachment levels stayed stable (Figure 24 and Figure 25).

Conclusion

The beveled flap design for palatal pocket correction introduced by Friedman involved a primary sulcular incision that included interproximal papillae followed by full-thickness flap elevation of both interproximal and palatal mucosa; debridement of root surfaces; osseous recontouring; creation of a secondary, parallel, scalloped, reverse-beveled incision at the level of the remaining alveolar crest; and suturing, in that order.¹⁴ The papillary retention flap presented here alters the sequence of Friedman's flap design and, most meaningfully, leaves the papillary tissue untouched, accomplishing pocket reduction/regeneration without ancillary retraction of cosmetically important mucosa.

As attested to by the examples shown herein, the esthetic and periodontal stability outcomes obtained by papillary retention treatment may be sustained in the long term in patients who conform with professional recall every 3 months and practice metic-

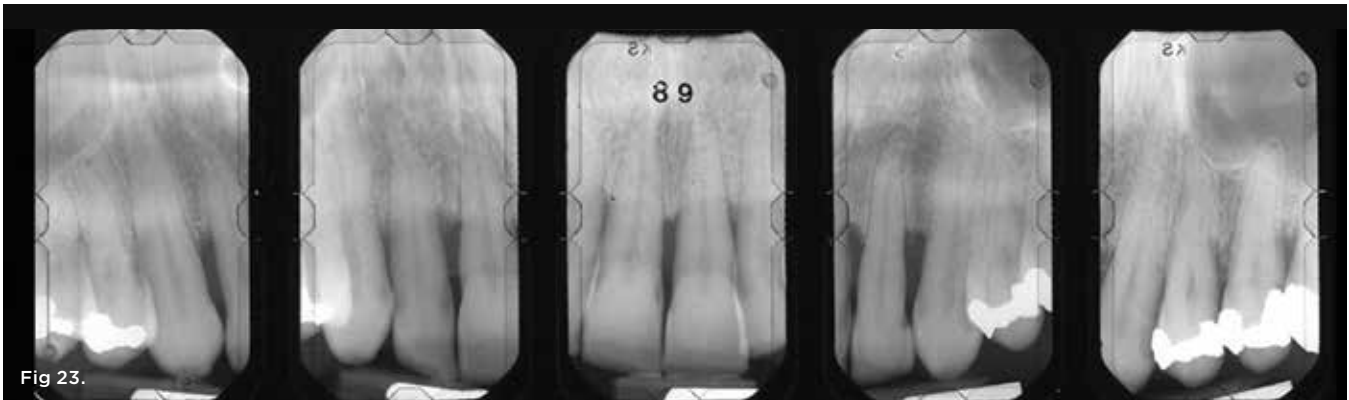


Fig 23.

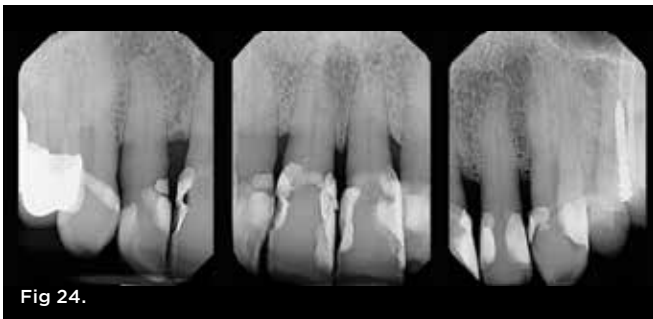


Fig 24.

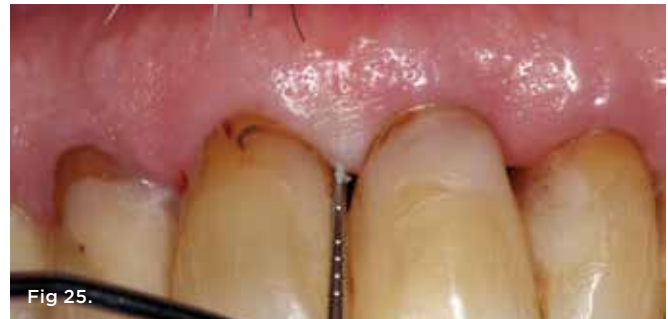

Fig 25.

Fig 23. Initial radiographs in 1989 of the patient in Case 3, who presented with more than 60% alveolar bone loss. Full-mouth SRP followed by full-mouth flap surgery, including maxillary anterior papillary retention treatment, was performed. **Fig 24.** Radiographs taken 28 years later revealed bone-level stability and maintenance of all maxillary anterior teeth. One posterior tooth was extracted due to endodontic failure. **Fig 25.** The patient had interproximal probing depths of 1 mm to 3 mm 28 years after surgical therapy.

ulous home care. Per usual, clinicians should carefully screen patients prior to surgery to select those who will be, or who may be trained to become, compliant and hygiene-oriented. Surgical results in these types of patients may be sustained for many years.

ABOUT THE AUTHORS

Michael Sonick, DMD

Private Practice specializing in implants and periodontics, Fairfield, Connecticut

Rui Ma, DMD

Private Practice specializing in implants and periodontics, Fairfield, Connecticut

Debby Hwang, DMD

Private Practice specializing in implants and periodontics, Ann Arbor, Michigan

REFERENCES

1. Frisch J, Jones RA, Bhaskar SN. Conservation of maxillary anterior esthetics: a modified surgical approach. *J Periodontol.* 1967;38(1):11-17.
2. Newell DH, Brunsvold MA. A modification of the curtain technique; incorporating an internal mattress suture. *J Periodontol.* 1985;56(8):484-487.
3. Evian CI, Corn H, Rosenberg ES. Retained interdental papilla procedure for maintaining anterior esthetics. *Compend Contin Educ Dent.* 1985;6(1):58-64.
4. Takei H, Yamada H, Hau T. Maxillary anterior esthetics. Preservation of the interdental papilla. *Dent Clin North Am.* 1989;33(2):263-273.
5. Cortellini P, Prato GP, Tonetti MS. The modified papilla preservation technique. A new surgical approach for interproximal regenerative procedures. *J Periodontol.* 1995;66(4):261-266.
6. Cortellini P, Prato GP, Tonetti MS. The simplified papilla preservation

flap. A novel surgical approach for the management of soft tissues in regenerative procedures. *Int J Periodontics Restorative Dent.* 1999;19(6):589-599.

7. Zucchelli G, Mele M, Checchi L. The papilla amplification flap for the treatment of a localized periodontal defect associated with a palatal groove. *J Periodontol.* 2006;77(10):1788-1796.

8. Zucchelli G, De Sanctis M. A novel approach to minimizing gingival recession in the treatment of vertical bony defects. *J Periodontol.* 2008;79(3):567-574.

9. Azzi R, Etienne D, Takei H, Carranza F. Bone regeneration using the pouch-and-tunnel technique. *Int J Periodontics Restorative Dent.* 2009;29(5):515-521.

10. Aslan S, Buduneli N, Cortellini P. Entire papilla preservation technique in the regenerative treatment of deep intrabony defects: 1-year results. *J Clin Periodontol.* 2017;44(9):926-932.

11. Graziani F, Gennai S, Cei S, et al. Clinical performance of access flap surgery in the treatment of the intrabony defect. A systematic review and meta-analysis of randomized clinical trials. *J Clin Periodontol.* 2012; 39(2):145-156.

12. Cortellini P, Buti J, Pini Prato G, Tonetti MS. Periodontal regeneration compared with access flap surgery in human intra-bony defects 20-year follow-up of a randomized clinical trial: tooth retention, periodontitis recurrence and costs. *J Clin Periodontol.* 2017;44(1):58-66.

13. Checchi L, Montevecchi M, Checchi V, Bonetti GA. A modified papilla preservation technique, 22 years later. *Quintessence Int.* 2009;40(4):303-311.

14. Friedman N. Mucogingival surgery. The apically repositioned flap. *J Periodontol.* 1962;33:328-340.

15. Ramfjord SP, Nissle RR. The modified widman flap. *J Periodontol.* 1974;45(8.2):601-607.