

Fixing a Gummy Smile *from irregular to beautiful results*

- Surgical treatment by **Rui Ma, DMD**
- Restorative dentistry by **Min Yoon, DDS**

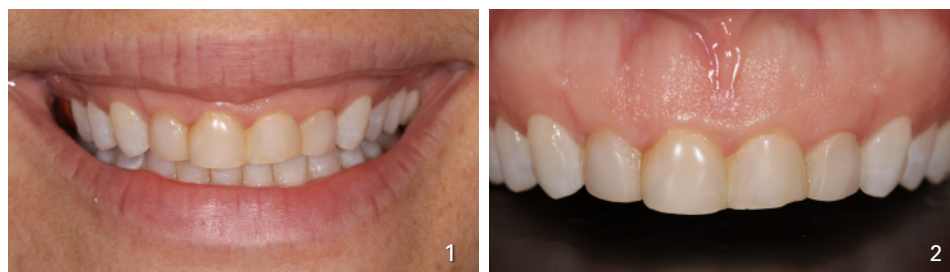

Fig. 1. Patient presented with worn-out teeth and uneven gingival margin on maxillary anterior teeth. She expressed she wants to fix her smile and showing less gingiva. **Fig. 2.** Retracted view shows robust and thick gingival phenotype and buccal bone.

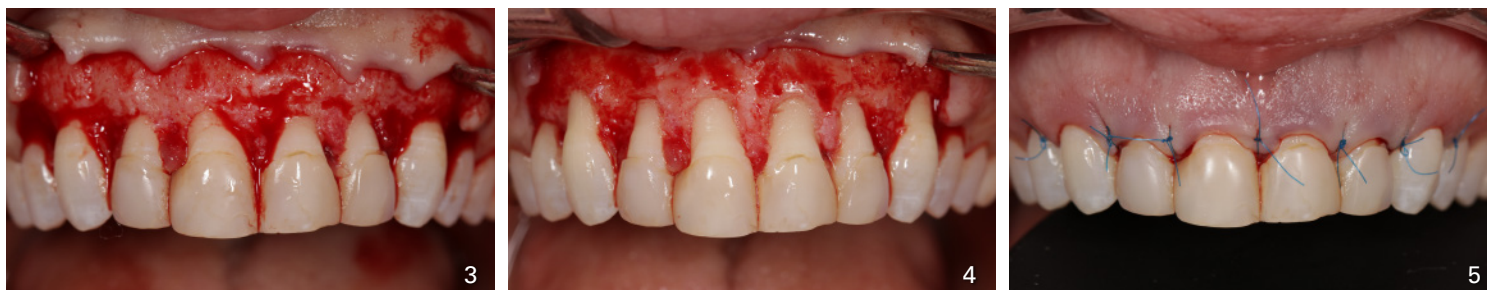

Fig. 3. After gingival flap, buccal bone was noted in close proximity to the CEJs. Discrepancies between the margins of the existing restorations and anatomical CEJs were noted. **Fig 4.** Osteoplasty and ostectomy were performed to keep buccal bone at least 3 mm away from the anatomical CEJs which will be the margins of future final restorations. Thick buccal bone was also reduced. **Fig 5.** Flap was closed with sutures in a simple interrupted fashion. No gingival reduction was done at this stage of the surgery.

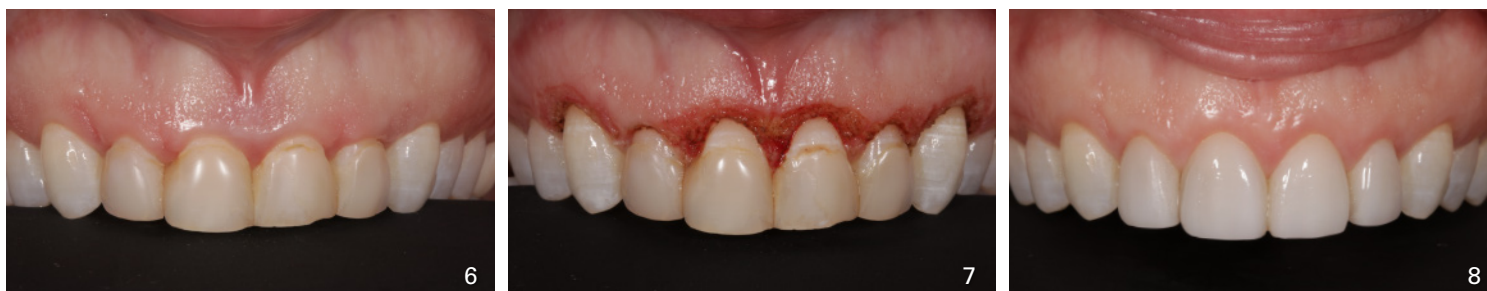

Fig. 6. Healing at 8 weeks. The buccal contour has smoother transition and flatter profile. Notice slight gingival recession over the existing restorations even without gingival reduction. **Fig. 7.** Gingivectomy with Diode LASER to recontour the gingival margin to exposure anatomical CEJs. **Fig 8.** 2 years follow up with final restorations. Gingival tissues are in harmony with restorations without any signs of irritation or inflammation.

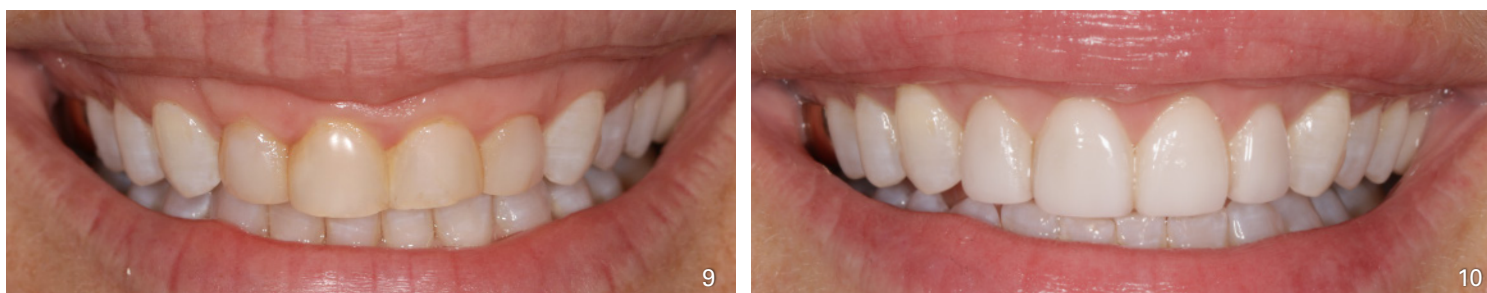


Fig .9-10. Before and after photos. Esthetic cases like this typically involve an esthetic wax-up by the restorative dentist, who will fabricate a surgical guide for the esthetic crown lengthening procedure, allowing the periodontal surgeon to reduce bone and gingiva with extreme precision for the restorations. The patient's smile has been transformed for a lifetime in a short time of 3-4 months.



Fairfield County Implants & Periodontics
Dr. Michael Sonick, Dr. Rui Ma, Dr. Stephanie Koo & Associates
Creating Beautiful Healthy Smiles for a Lifetime

1047 Old Post Road
 Fairfield CT 06824
 203-254-2006
 office@sonickdmd.com
 www.sonickdmd.com