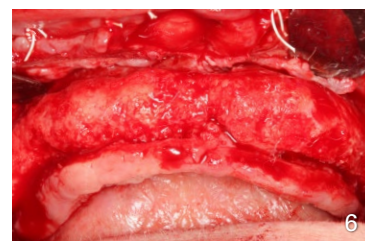
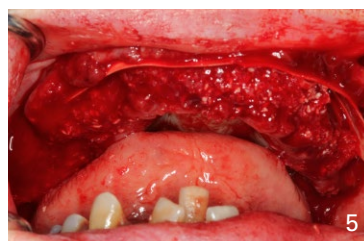
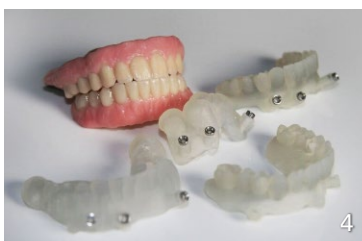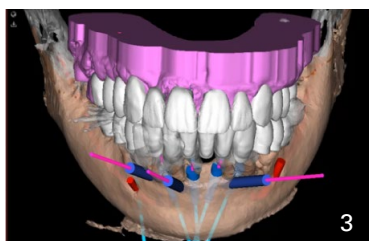

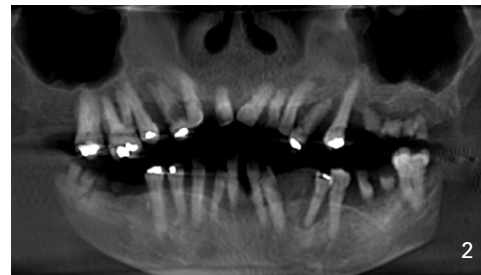
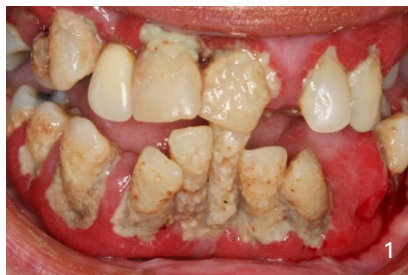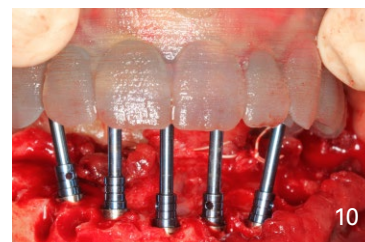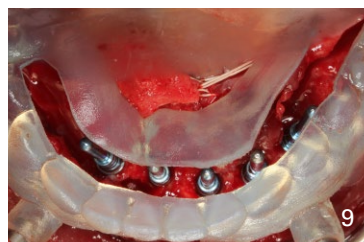
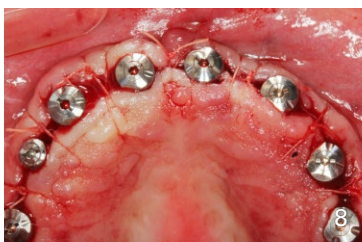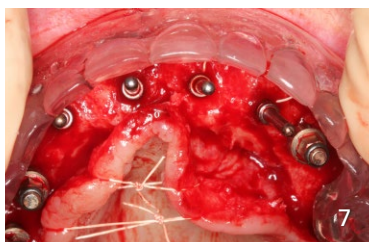
Restoring Hope
Immediate Implant and Alveolar Reconstruction

Surgical treatment by **Dr. Michael Sonick**
Restorative dentistry by **Dr. Michael Reynolds**

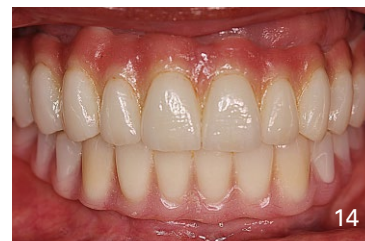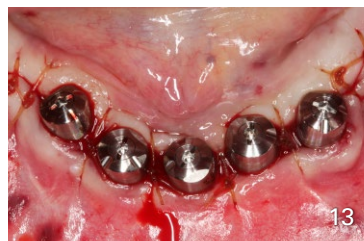
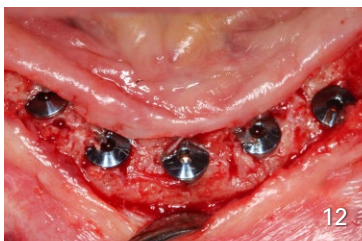
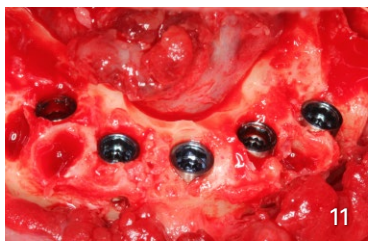1, 2. After years of dental avoidance, this 65 year old female presented with generalized severe periodontitis and gross decay – a terminal dentition.



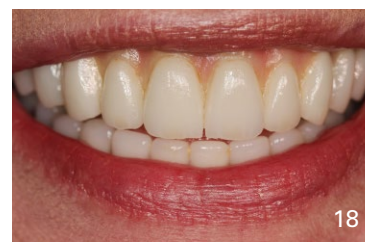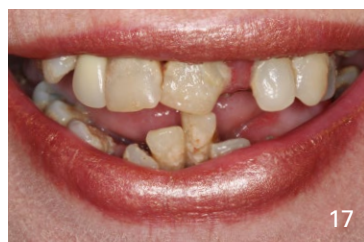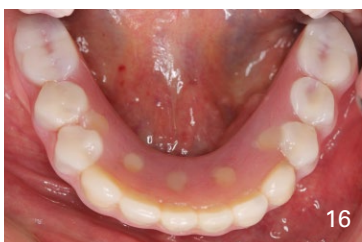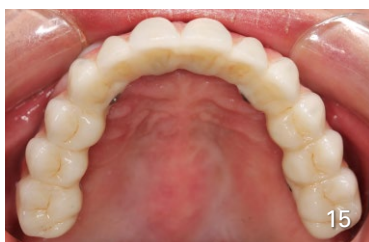3. Digital scanning and treatment planning were done for complete dentures (conventional impressions were not possible due to tooth mobility) and full arch maxillary and mandibular implant supported prostheses. 4. Surgical guides were 3D printed. 5. Maxillary extractions and ridge augmentation with cancellous allograft, growth factors and resorbable bovine membranes were performed. 6. Four months following grafting, an excellent 10 mm wide alveolar ridge is ready to receive dental implants.



7. Four months post extraction, a CBCT generated stent was fabricated and 8 maxillary implants were placed ideally. 8. Following 4 months of healing, second stage surgery was performed and abutments placed. 9, 10. All mandibular teeth were extracted and utilizing a computer generated surgical guide, 5 implants were immediately placed.



11. Immediate mandibular implant placement following extraction and alveolectomy. 12. Second stage surgery 4 months later (note regenerated bone). 13. Abutment placement. (note band of adequate keratinized tissue buccally and lingually).



14 - 16. Final implant supported hybrid zirconia prostheses. 17. Initial "smile" shot. 18. Final smile – patient is healthier, happier and much more confident.



Fairfield County Implants & Periodontics
Dr. Michael Sonick, Dr. Rui Ma, Dr. Stephanie Koo & Associates
Creating Beautiful Healthy Smiles for a Lifetime

1047 Old Post Road
Fairfield CT 06824
203-254-2006
office@sonickdmd.com
www.sonickdmd.com