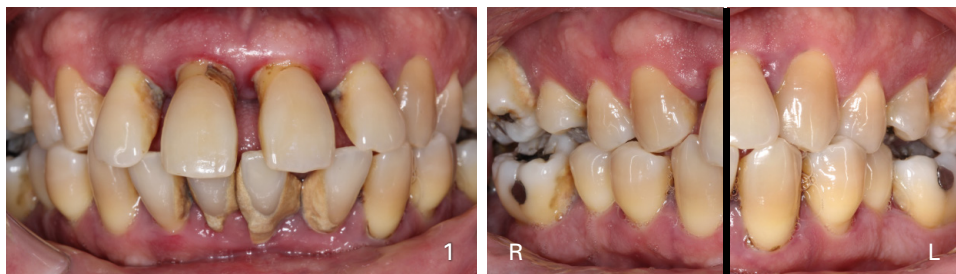

Comprehensive Rehabilitation of a "Hopeless" Dentition



- Surgical treatment by **Michael Sonick, DMD**
- Orthodontist: **Dr. Cass Burrell**

Fig. 1. This 38-year-old, male Type II Diabetic with an A1c of 8.0 presented with Generalized Severe Periodontal Disease. Mobility was Class 2 -3 and mastication was challenging (R.L).

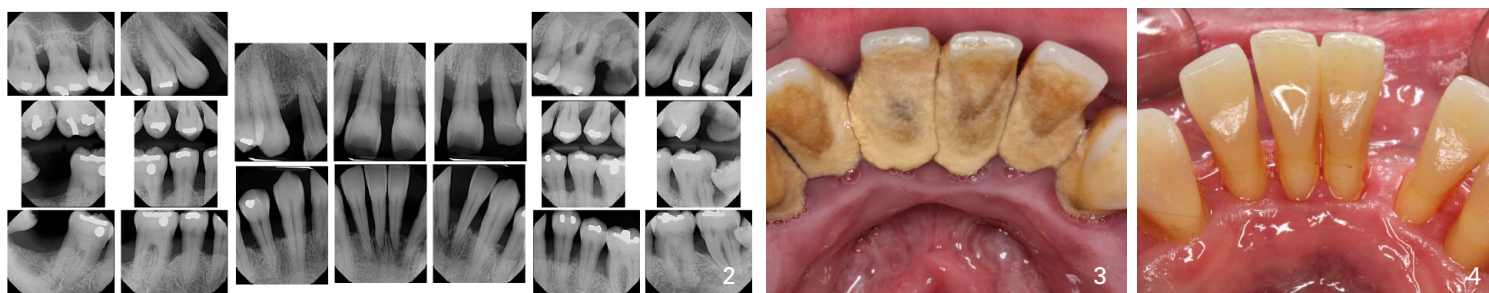


Fig. 2. FMX reveals 60 -90% alveolar bone loss. Prognosis was questionable. **Fig. 3.** Poor OH and significant lingual inflammation. **Fig. 4.** Soft tissue health following SRP and guided tissue regeneration.

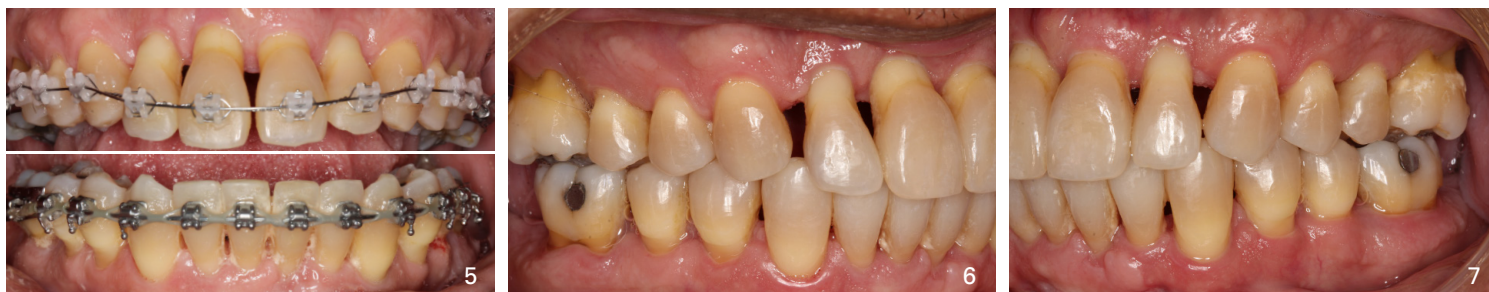

Fig. 5. Six month post perio surg and bone regeneration ortho was commenced **Fig. 6-7.** Post ortho and perio, ideal occlusion is established. Note gingival health, tissue is firm, pink and stippled.

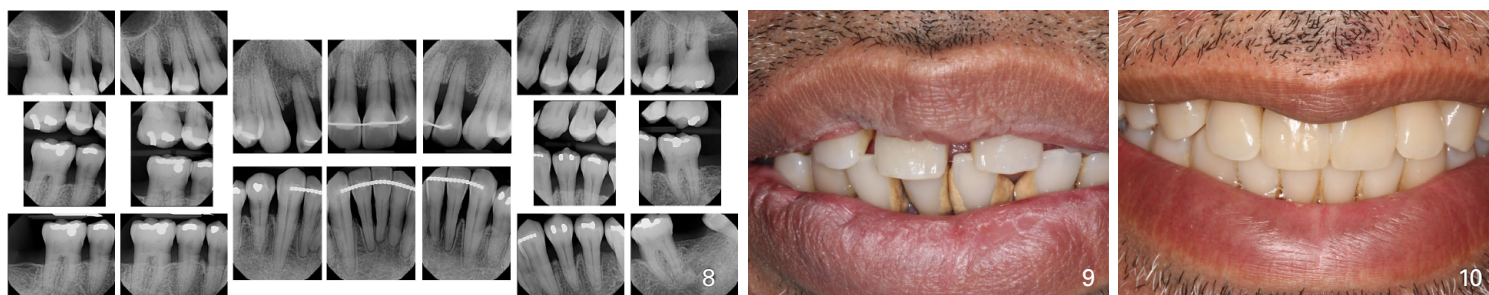

Fig. 8. FMX 5 years post op (compare to Fig 2). Bone is regenerated and stable. **Fig. 9.** Smile pre op with poor esthetics. **Fig. 10.** Smile post op. Excellent health orally and systemically as diabetes is now under control, and self-esteem is improved.

