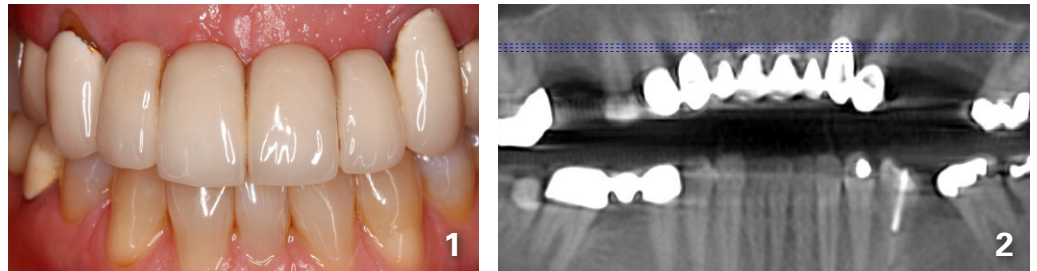
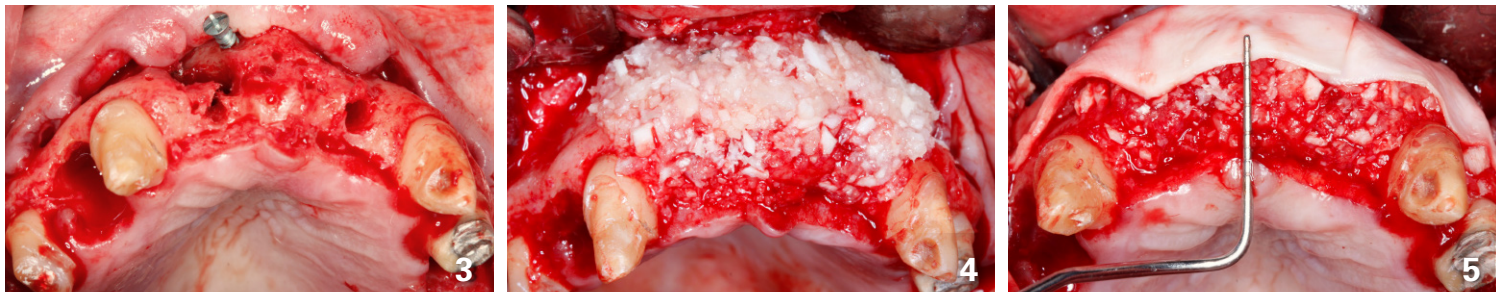

## Esthetic Ridge Augmentation in the Anterior Maxilla

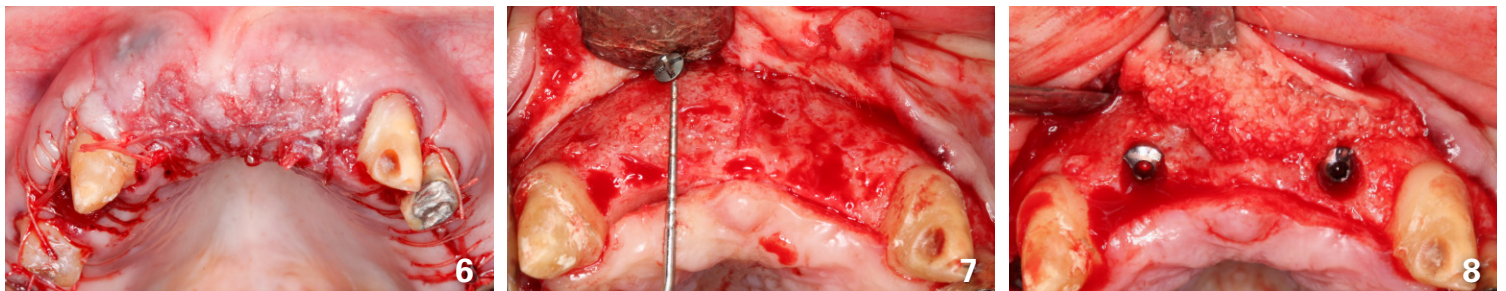
- Surgical treatment by **Michael Sonick, DMD**
- Restorative dentistry by **Min Yoon, DDS**



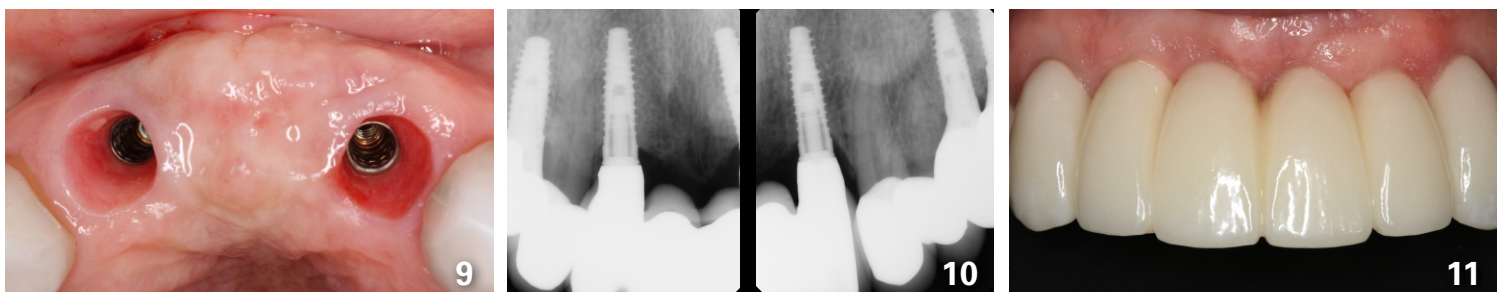
**Fig. 1.** 52-year-old female presented with a failing fixed bridge from teeth 5 through 12. **Fig. 2.** Initial panoramic radiograph



**Fig. 3.** A full-thickness flap was elevated from tooth 4 through 12, tooth 7 was extracted, and a tenting screw was placed to maintain space. **Fig 4.** A combination of Puros cortical-cancellous bone allograft and Regenerate DBM was mixed with rh-PRGF (Gem-21) and placed labially. **Fig 5.** Human pericardium allograft membrane was placed superior to the bone allograft. Note the increase in buccal palatal thickness. Compare this to Figure 3.



**Fig 6.** Labial flap was released and mobilized to achieve passive primary closure. **Fig 7.** Nine months following bone grafting, the patient was prepared for implant surgery. Compare this to Figure 3. **Fig 8.** Implant placement was performed in areas of teeth 7 and 10. Autogenous bone was harvested during osteotomy preparation with slow speed drilling (75 rpm), and placed labially with an Osseoguard membrane.



**Fig 9.** The patient was provisionalized for three months post-exposure. This allowed for tissue maturation. Labial bone and soft tissue thickness are excellent, leading to a predictable esthetic result and minimizing future recession. **Fig 10.** Final radiographs. **Fig 11.** Final restoration with ideal dental gingival esthetics. Compare this to Figure 1.

