

Implant Removal and Esthetic Anterior Reconstruction

- Surgical treatment by **Michael Sonick, DMD**
- Restorative dentistry by **Min Yoon, DDS**

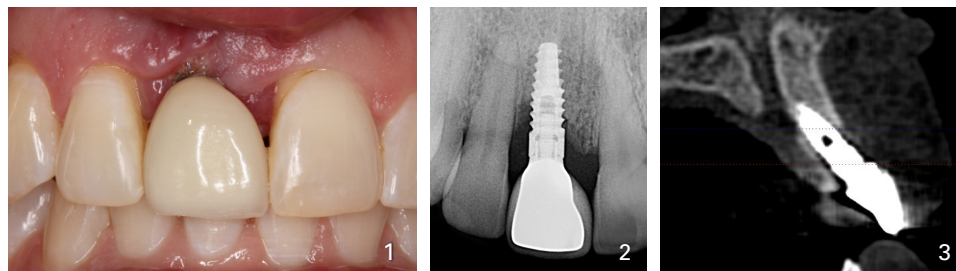


Fig. 1. A 33 yo female presented with a c.c. of an unesthetic dental implant. **Fig. 2.** Initial x-ray shows circumferential bone loss. **Fig. 3.** Initial CBCT exhibits buccal angulation and 60% loss of facial plate of bone.

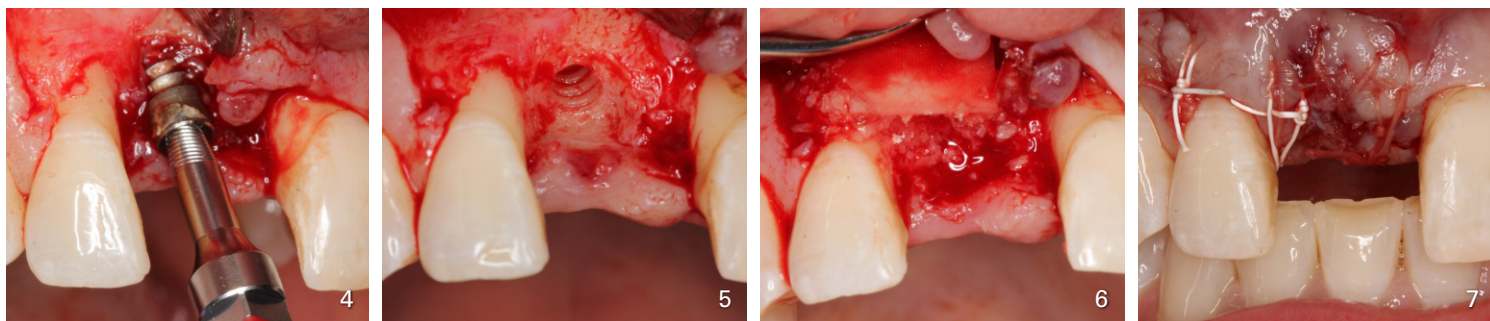


Fig. 4. Implant removal tool in place. **Fig. 5.** Implant was removed. Note bone loss on mesial of tooth 7 and distal of tooth 9. **Fig. 6.** Grafting with Puros cancellous bone allograft saturated in rh-PRGF(Gem-21) covered with a collagen membrane (Osseoguard). **Fig. 7.** Closure accomplished with Rapide, Gore-Tex and 5-0 gut sutures and a collagen plug.

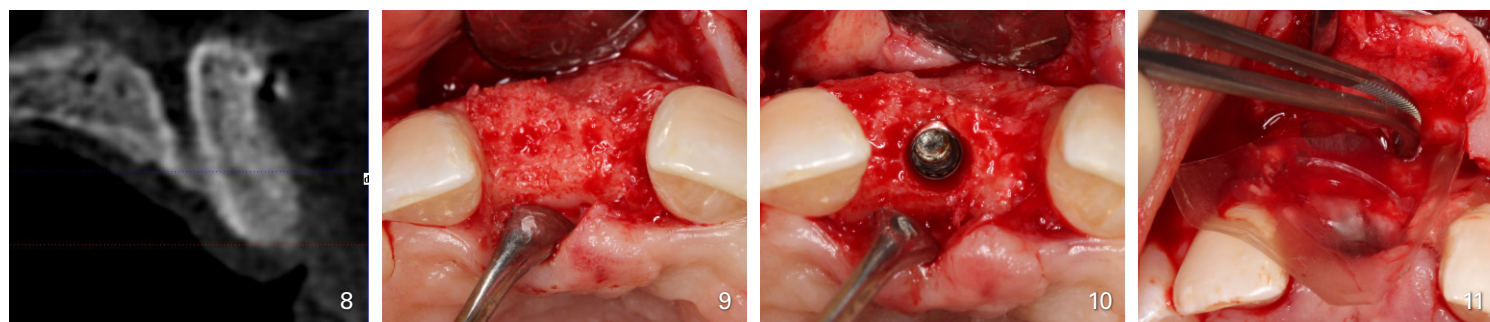


Fig. 8. CBCT, 6 months following grafting reveals complete bony regeneration. Compare to Fig. 3. **Fig. 9.** Implant placement day with excellent bone. Compare to Fig. 5. **Fig. 10.** Ideal placement with a 3.4 mm implant. Note 3 mm of bone is present facially. **Fig. 11.** Autogenous bone is placed buccally and covered with a placental membrane (BioXclude) to encourage additional labial bone.

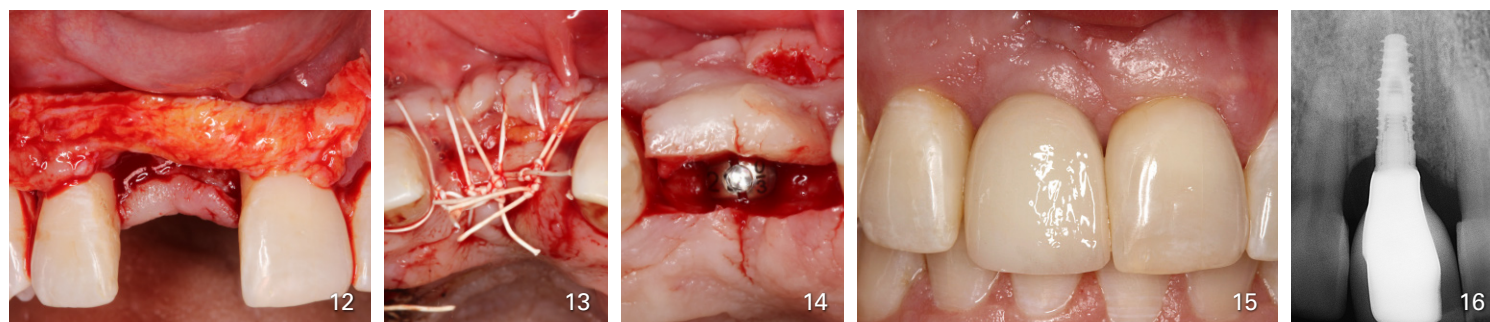


Fig. 12. A connective tissue graft is placed to ameliorate esthetics. **Fig. 13.** Improved labial profile and augmentation at closure. **Fig. 14.** Second stage surgery 4 month post implant placement. Palatal approach leads to enhanced buccal contour. **Fig. 15.** Final implant crown. Nice esthetics and a return to gingival health. Compare to Fig. 1. **Fig. 16.** Final x-ray. Note bone growth on mesial of # 7 and improvement of bone density. Compare to Fig. 2.

