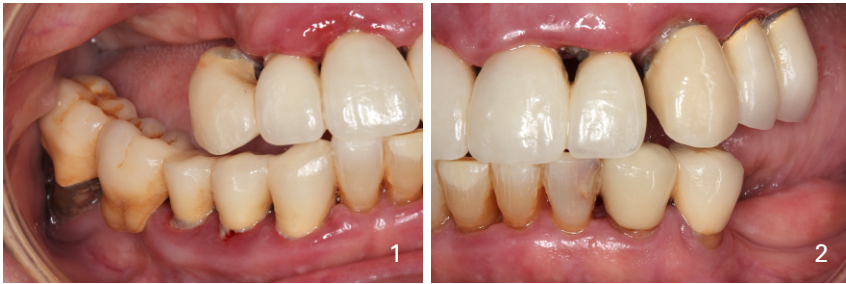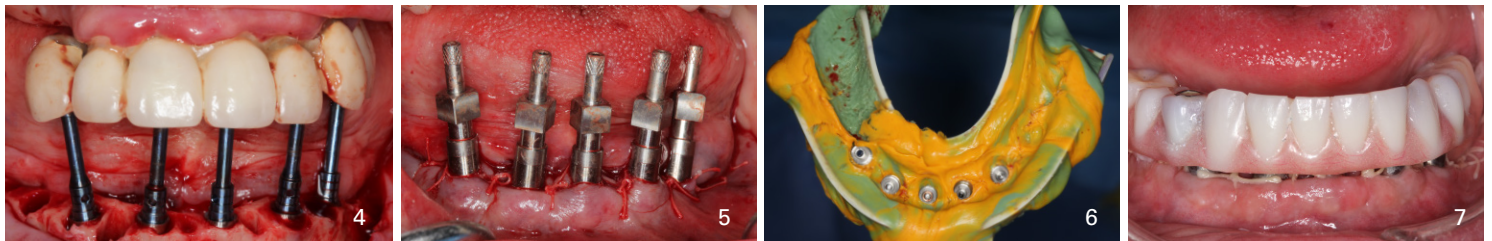
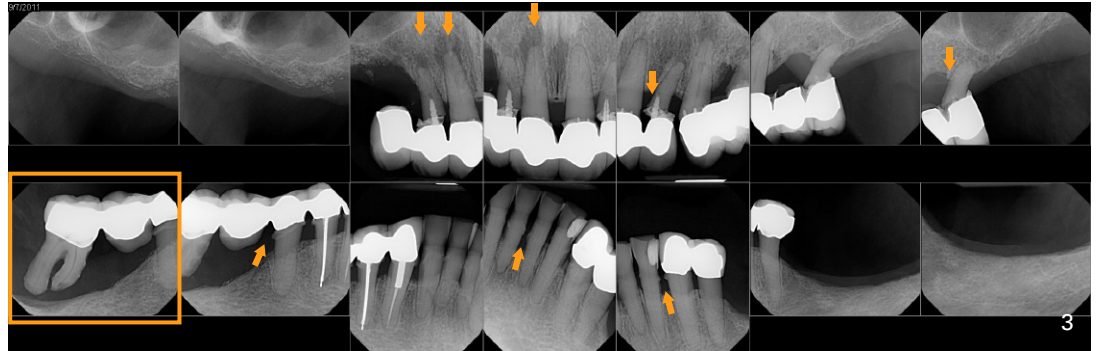


Returning a "Hopeless" Patient to Health and Esthetics

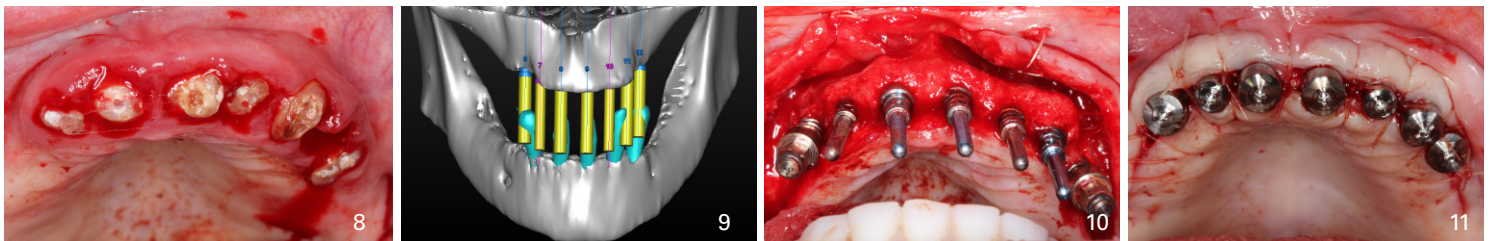


(1,2) This 78-year female patient and former fashion model was suffering from severe dental disease despite seeing her dentist for routine cleanings.

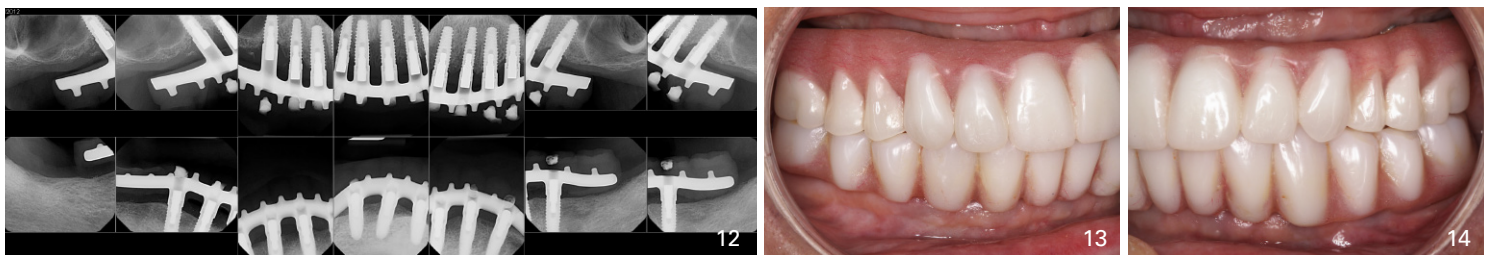
(3) Full mouth radiographs revealed severe periodontal disease, subgingival calculus, caries and a two unit distal "pontic" with the root still present. She was told that she was not a candidate for dental implants.



(4-7) Following a comprehensive exam which included a FMX, CBCT, and diagnostic casts – all teeth were removed, mandibular implants placed and loaded immediately.



In the maxilla (8), implant placement was delayed and grafting performed. Four months later (9-11), implants were placed and additional grafting performed to idealize bony architecture.



(12-14) The completed restoration returned the patient to function and health. Today, 6 years later, this 84-year-old woman is vital and active with her five children and many grandchildren. - Thanks to Dr. Mark Samuels for his restorative expertise.

