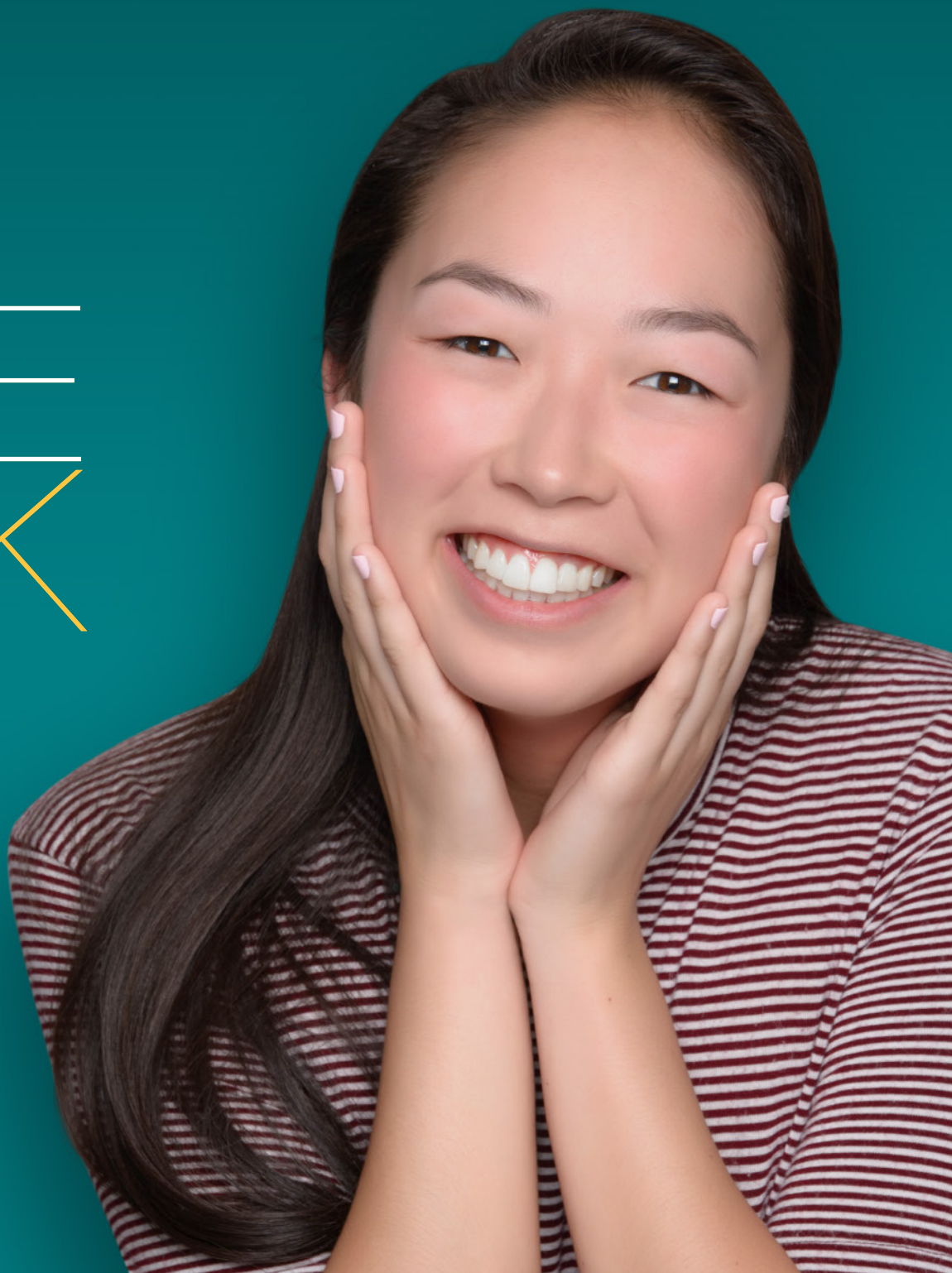

THE SMILE BOOK

Michael Sonick, DMD
Rui Ma, DMD



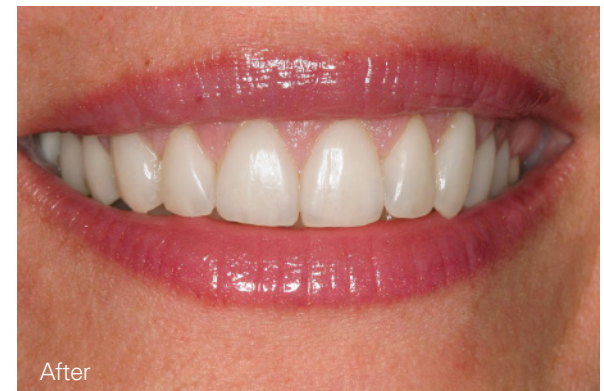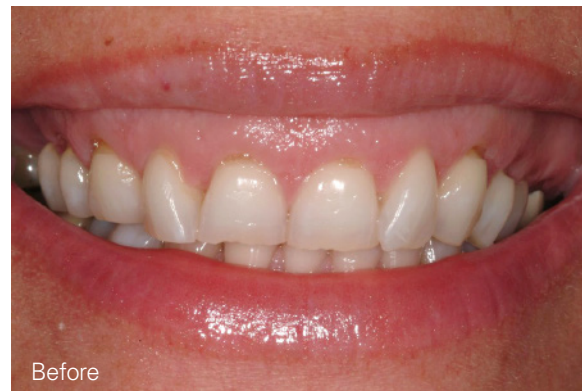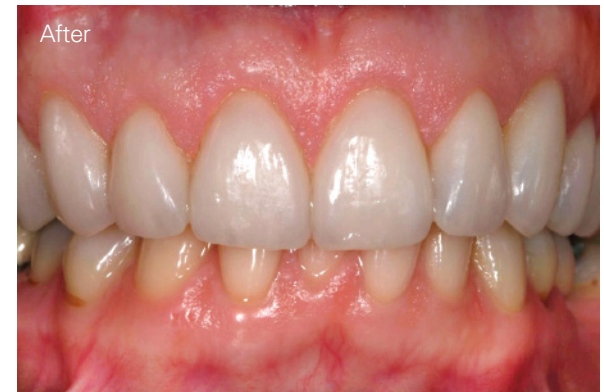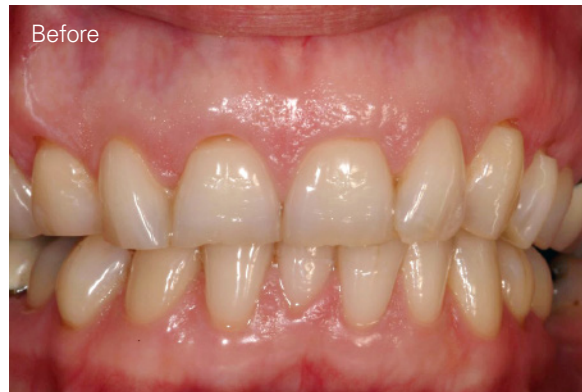Index

Gummy Smile Correction	4
Single Implant Tooth Replacement	10
Multiple Implant Teeth Replacement	18
Total Smile Makeover	24



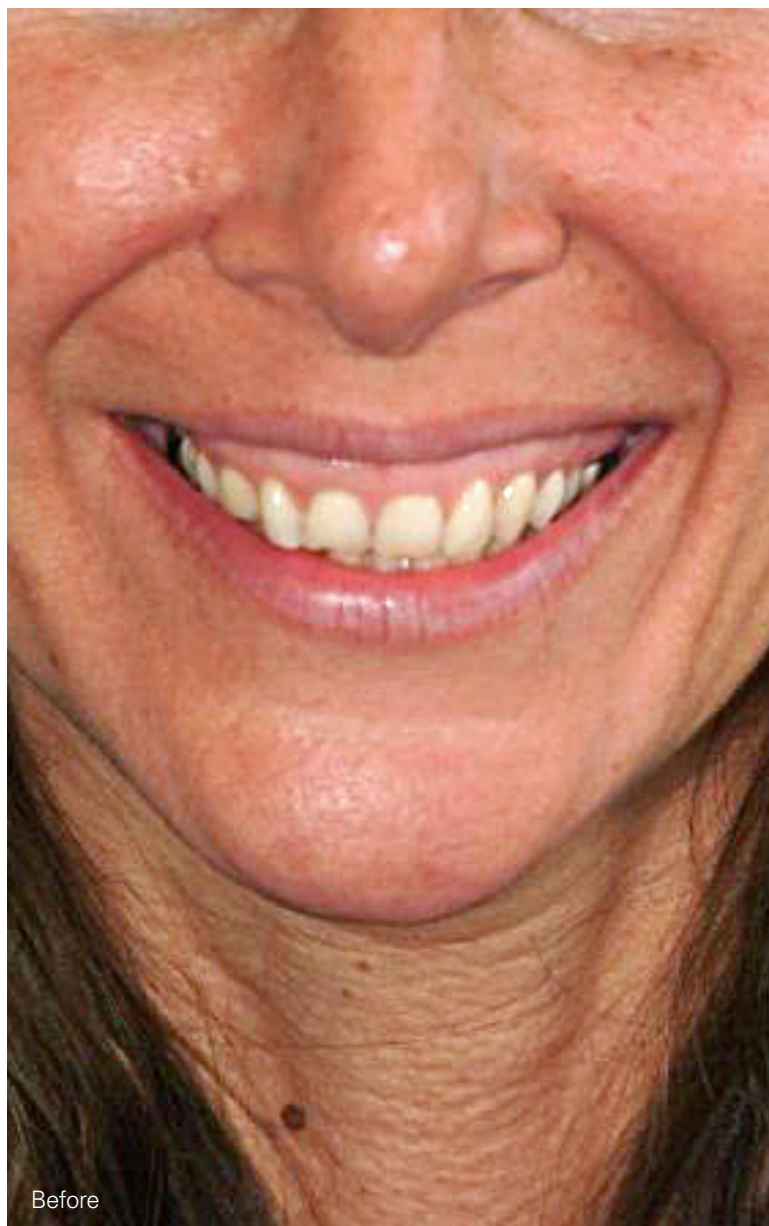

To improve the quality of our patients lives, through education, treatment and motivation in a comfortable, caring and friendly environment.

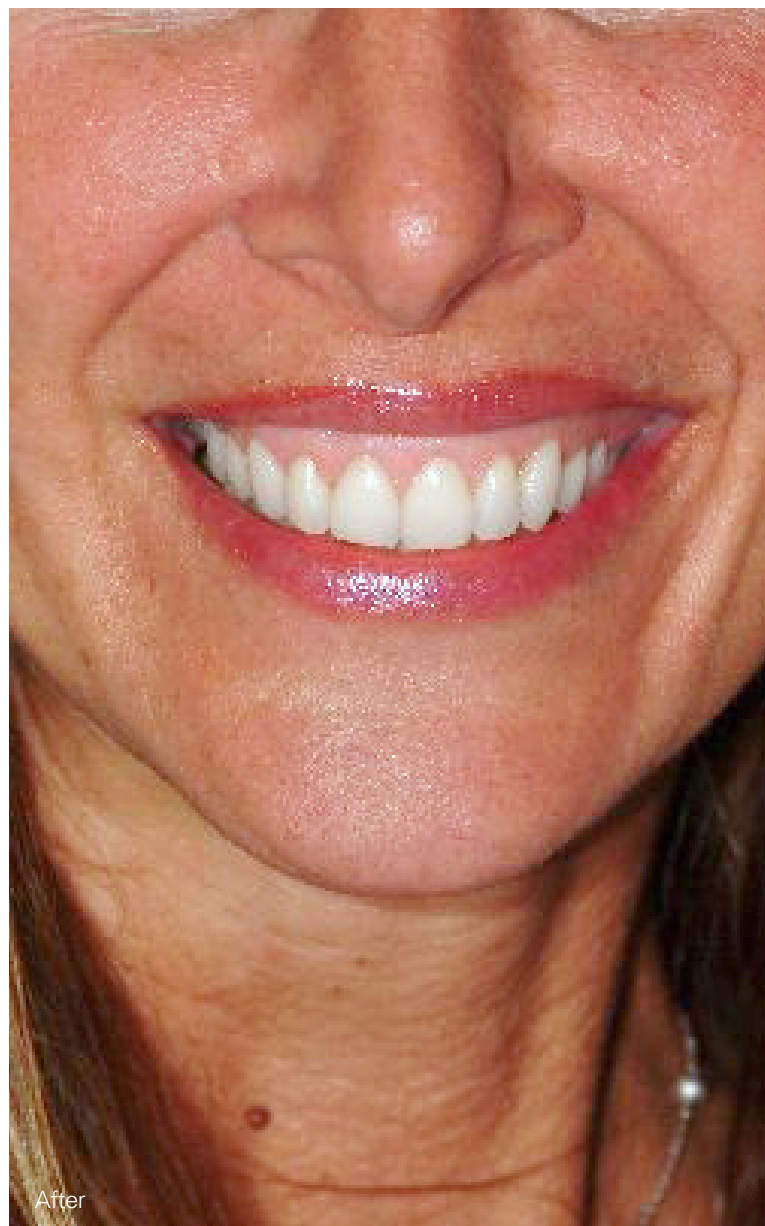

Gummy Smile Correction and Veneers

A combination of situations both genetic and environmental, led to tooth wear and excessive display of the gum tissue. The patient was concerned, "I show a lot of gum when I smile. How can this be fixed?" Following esthetic gum reshaping, the front teeth were restored with veneers. The patient's inner and outer beauty are reflected with a healthy confident smile. "I am so pleased with my bright smile. I look younger too," she commented.



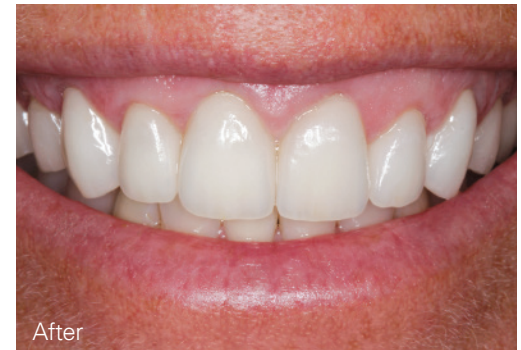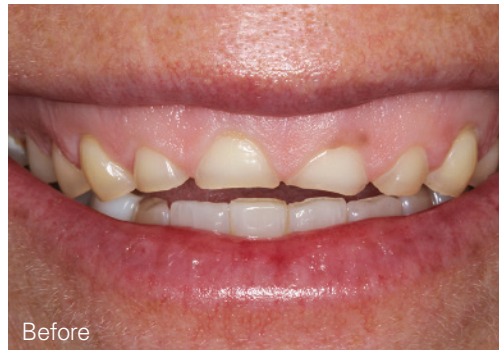Before



After

Gummy Smile Correction and Crowns

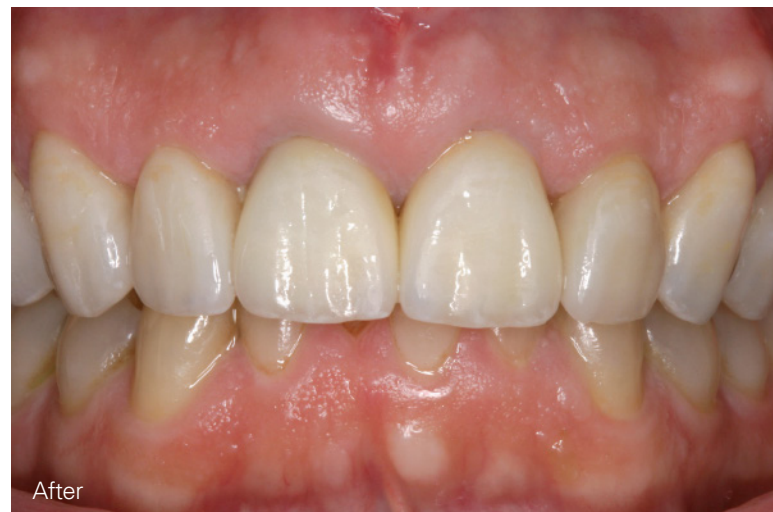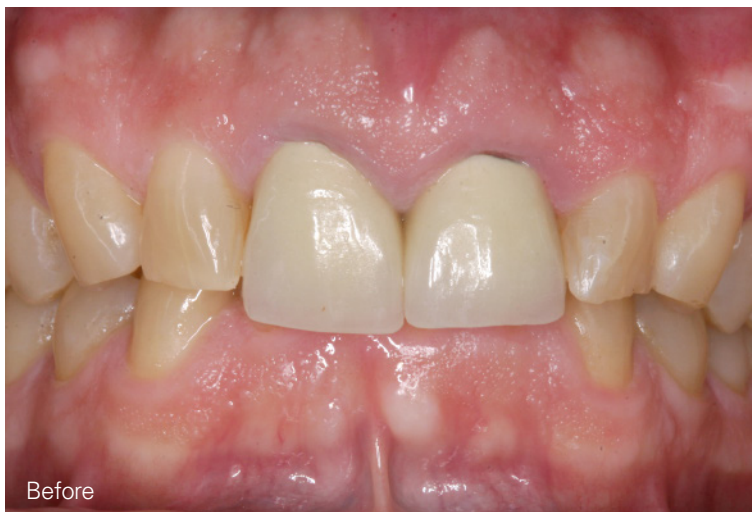This young female patient presented with severe wear of her teeth due to nightly grinding and clenching. She was not happy with her smile and had trouble eating. She was treated with a combination of therapy which included esthetic crown lengthening (gum reshaping), Invisalign, and porcelain crowns. The patient has been restored to health and can smile and chew with confidence.





This successful entrepreneur wanted a more youthful smile. Following diagnostic imaging and a full wax up, it was decided to replace his older crowns and restore him to ideal function and aesthetics. A combination of esthetic gingival reshaping techniques coupled with restorative dentistry resulted in a beautiful smile. "I have never smiled with more confidence!"

Gum Reshaping and New Crowns

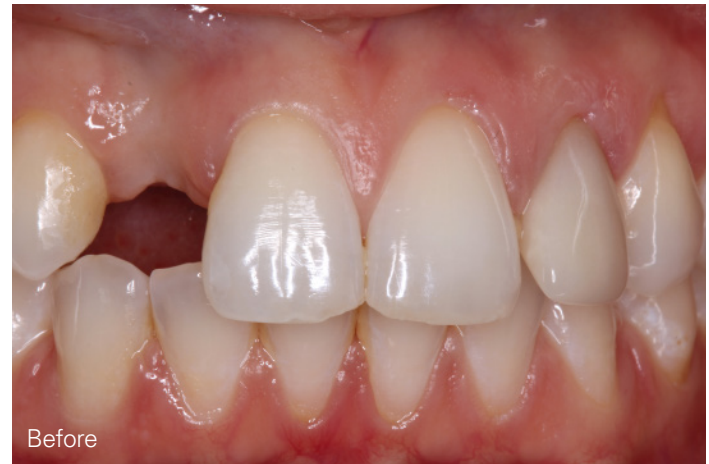



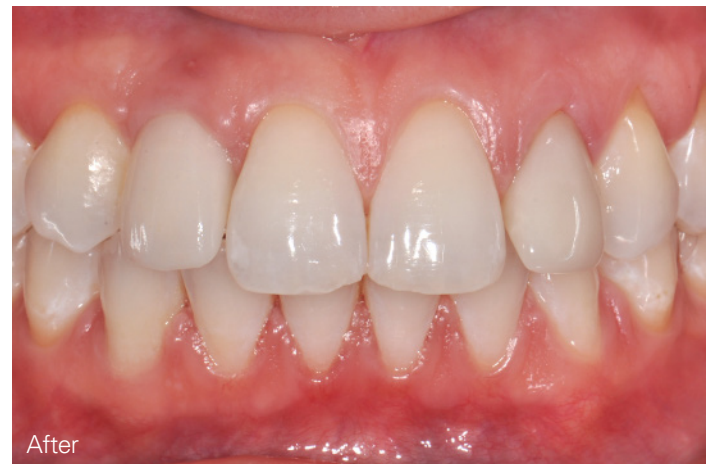Immediate Solution for a missing tooth

This attractive young female fractured her front tooth while eating lettuce at midnight in New York City. Quite upset, she called her aunt who lived in Connecticut and was referred to our office.

She was very healthy and had excellent bone enabling us to remove the fractured root and immediately place the front implant. A few months later she was restored to esthetics and complete health. Only she and her dentist knows she has a dental implant. The patient loved the result, and shared, "At last I have a solid and beautiful permanent front tooth. I don't have to worry about it anymore."



Before



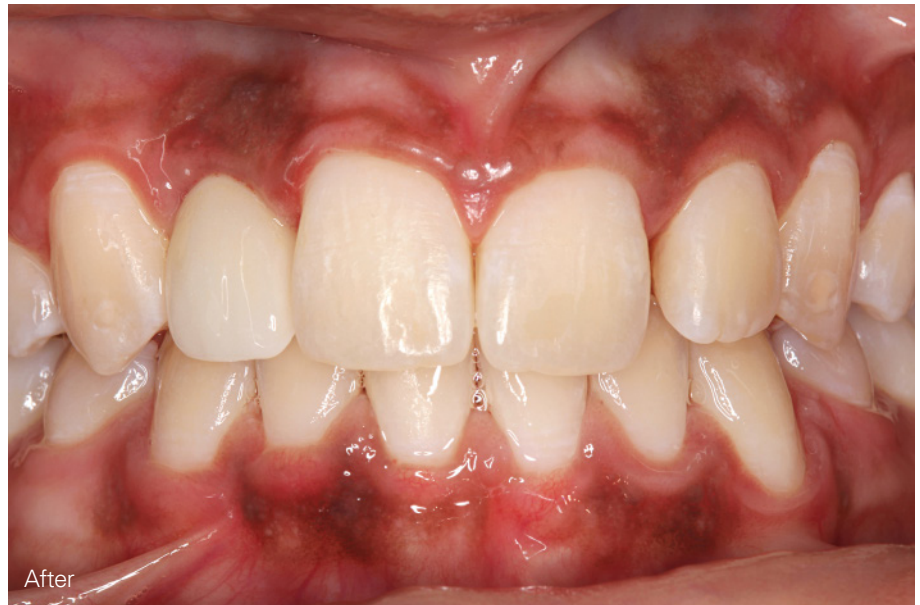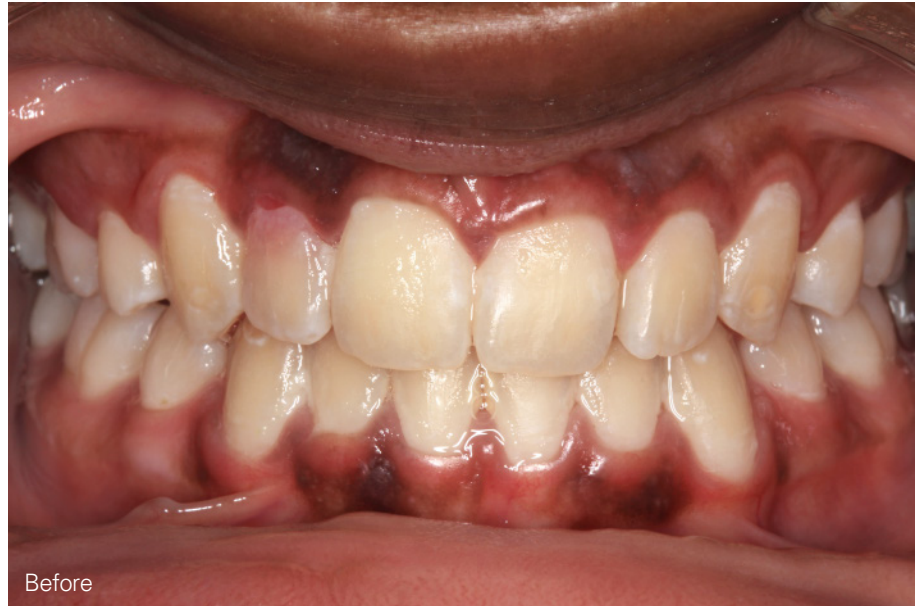After

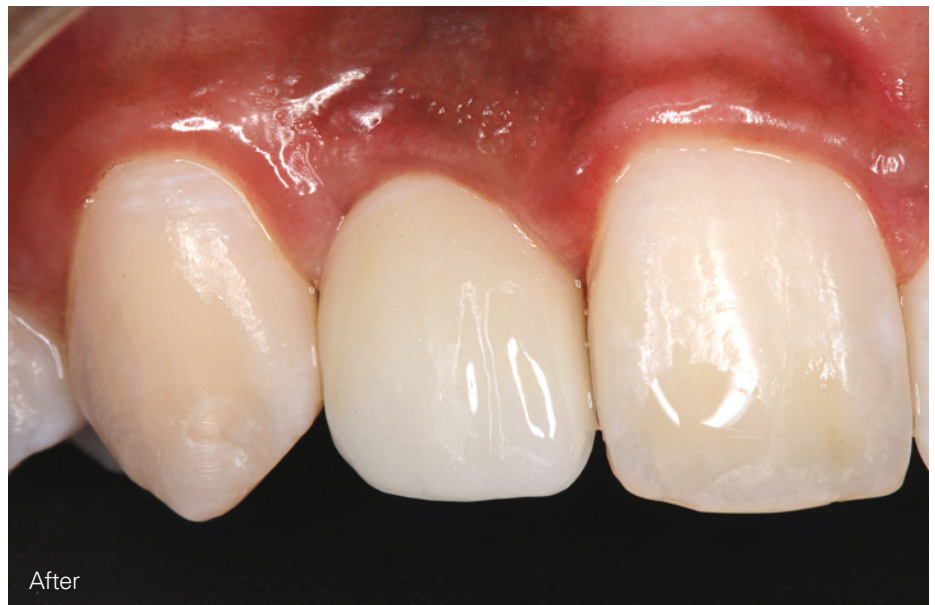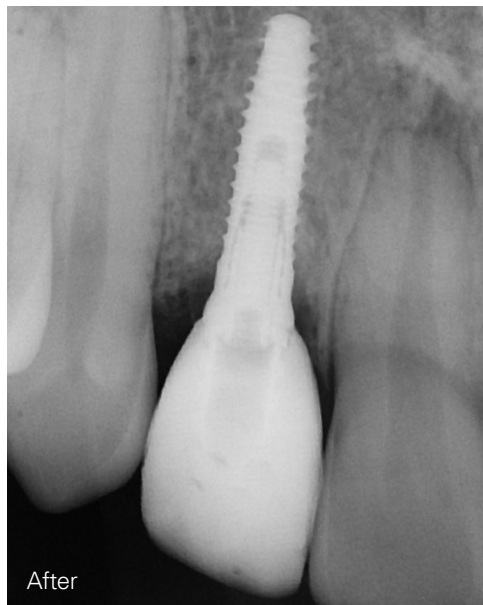

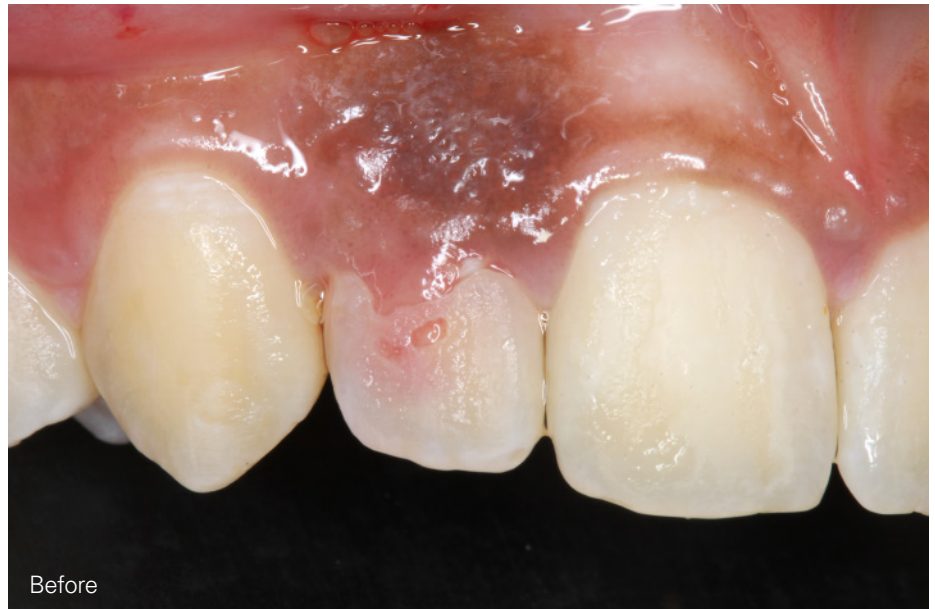
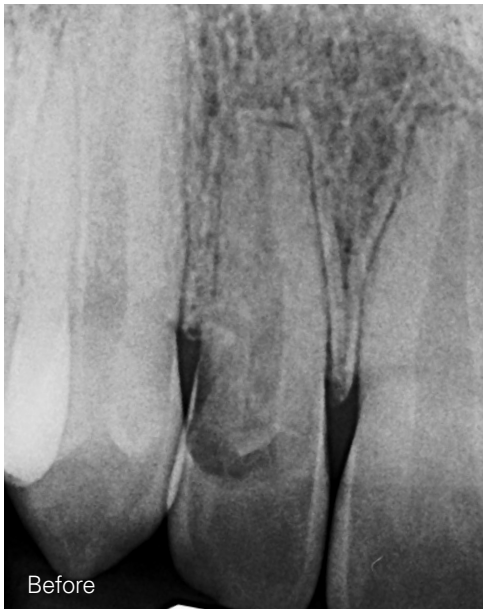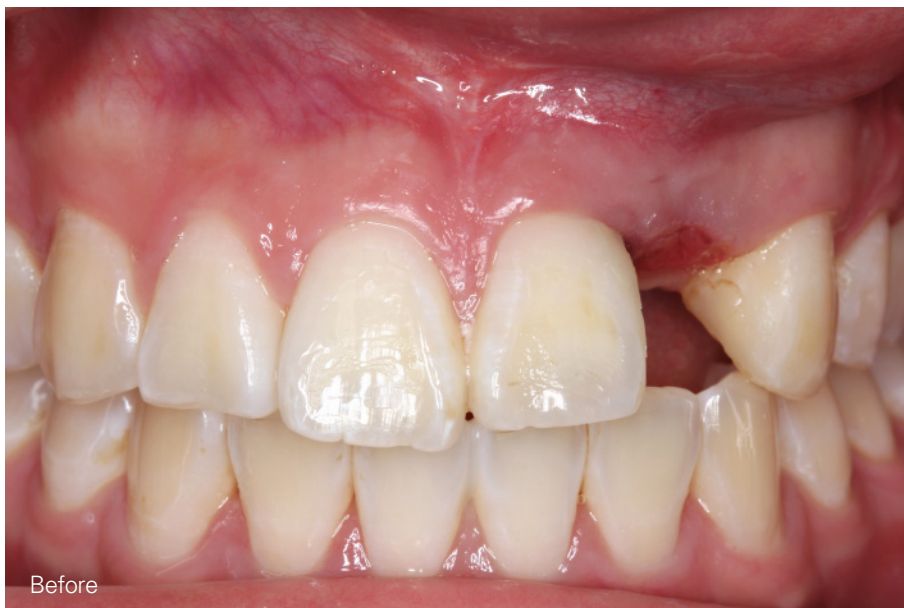"I am so embarrassed about my red front tooth that I try not to smile". This young high school female stated at her initial visit. She suffered trauma to her upper right tooth (lateral incisor) leading to internal resorption and a hopeless prognosis. The tooth was removed, the infection eliminated, and the bone regenerated in preparation for a dental implant.

Her high school graduation gift was a new front tooth supported by a dental implant. "I have never seen my daughter smile so much", her very pleased Mom explained.

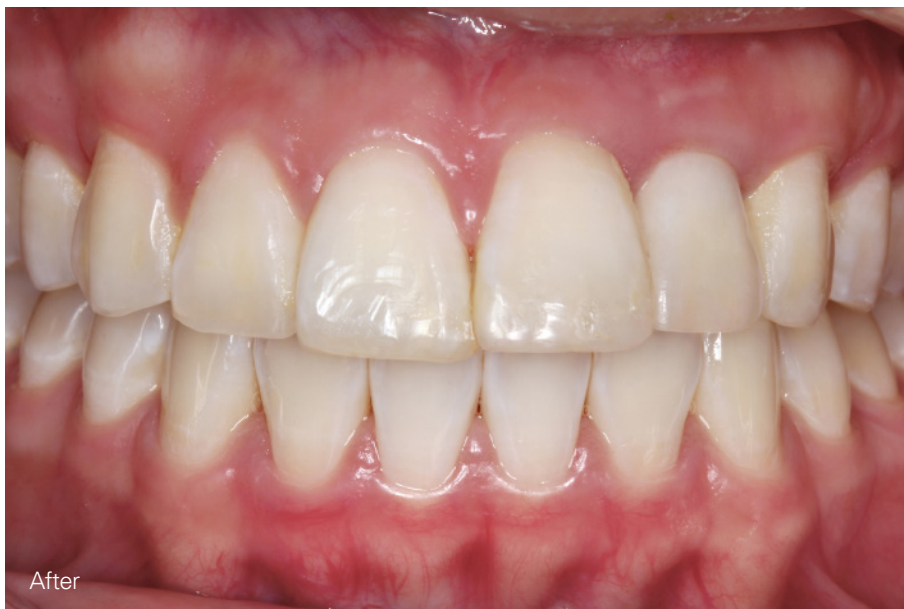Replacing a Hopeless Traumatized Front Tooth with a Dental Implant







Before



After

Congenitally Missing a Front Tooth



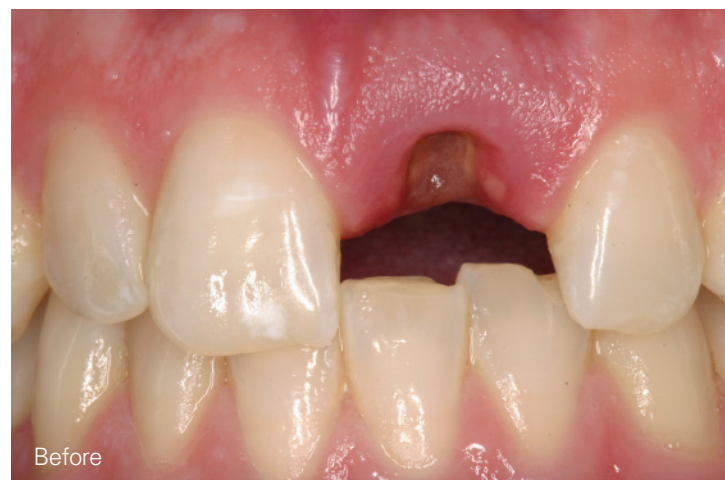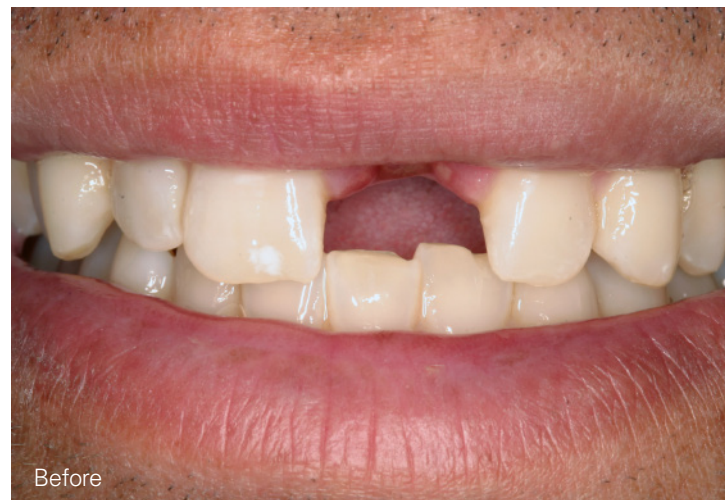We initially met this young girl at age 11, years before she was ready for her single tooth replacement (dental implant).

Working with her mom and dad and an excellent team of dental professionals, an orthodontist, restorative dentist and periodontist, a plan was developed to create an ideal pleasing smile.

Proper long-term treatment planning with an eye toward the future is essential to assure an esthetic predictable long-term result. A combination, of orthodontics, bone regeneration, implant placement and restorative dentistry all aided in the creation of a natural looking beautiful smile.

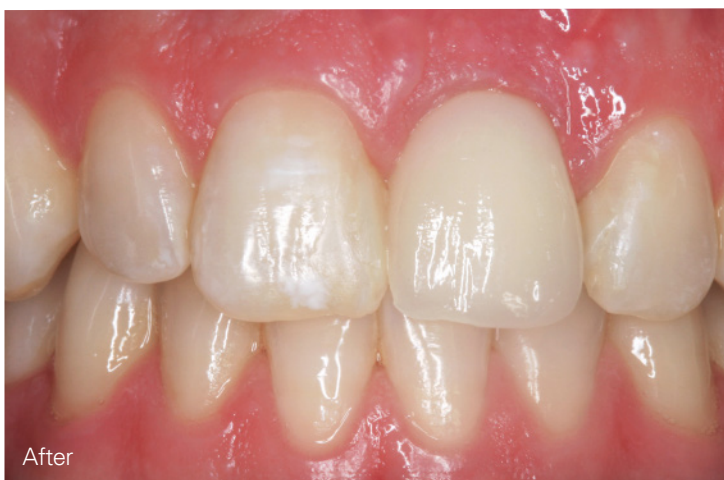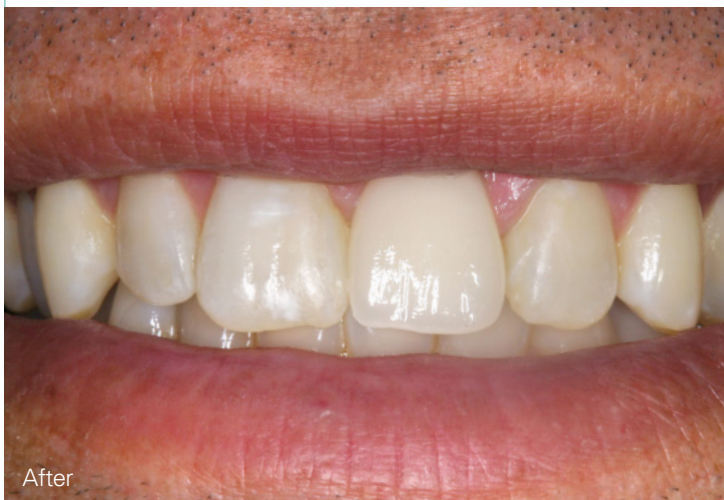One year following completion, the patient and her parents are ecstatic. "My teeth feel completely natural. I show all of my friends my dental implant and sometimes can't even remember which tooth is the replacement," she beamed during one of her college breaks.





“I Need a Dental Implant
and Want a Perfect Result”

Front teeth are a big deal. Nothing can be more devastating to a patient than the loss of a front tooth. The replacement of a central incisor with a dental implant is perhaps the most challenging of all restorations. Everything must be perfect – the bone, the implant position, the amount of gum tissue and the final restoration.

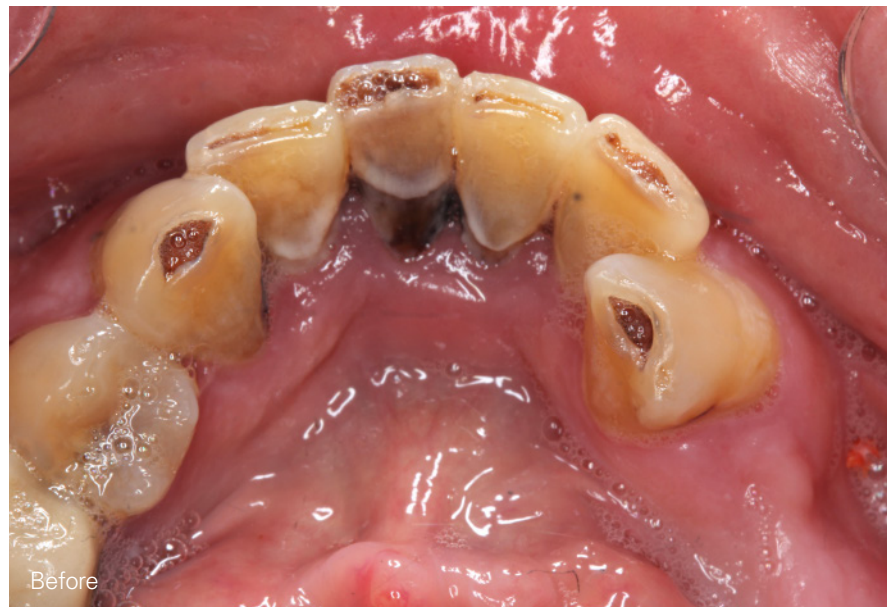
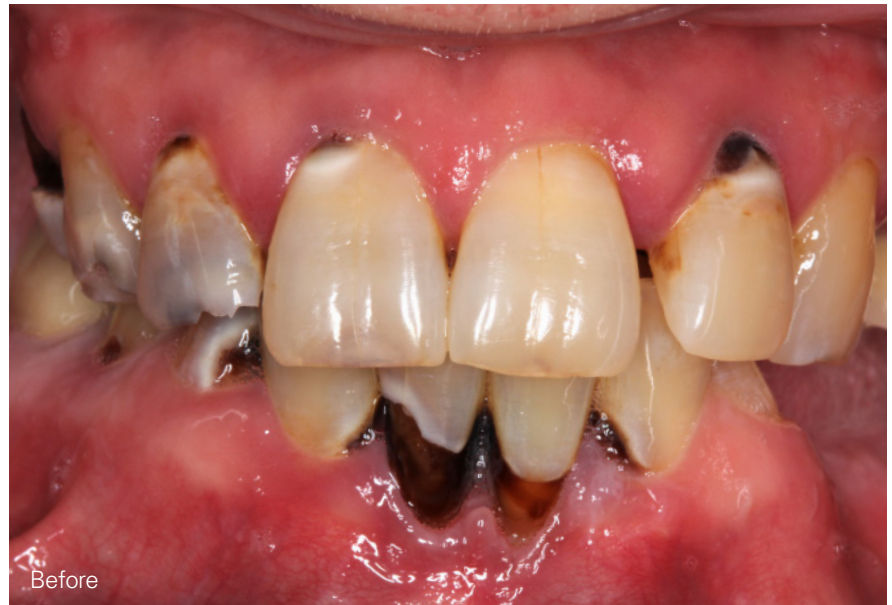

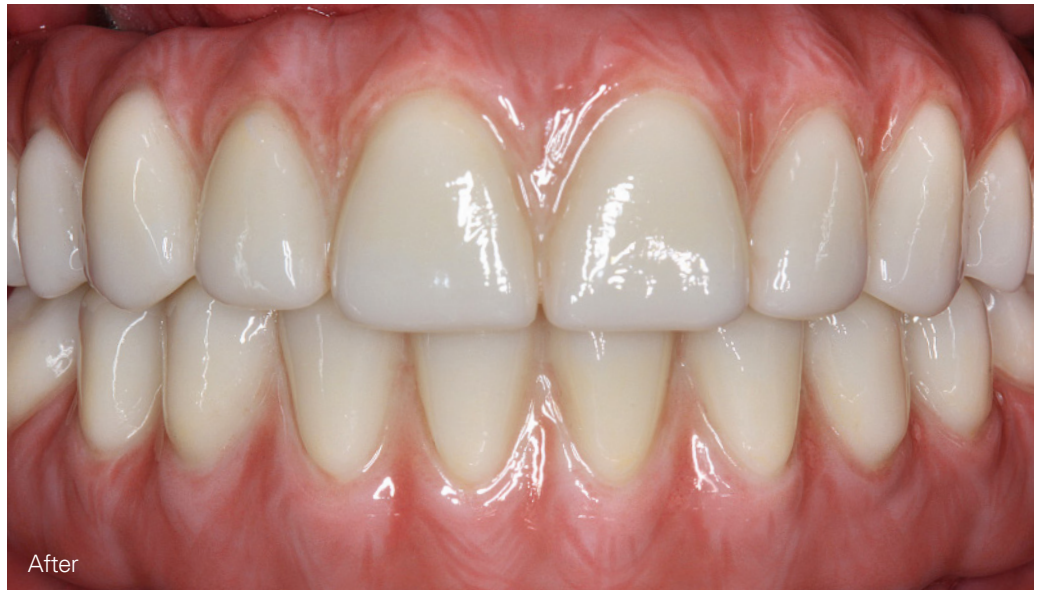Fortunately, today, with proper planning, all of this is possible. This young professional was very pleased with the final result, which is almost indistinguishable from the natural adjacent tooth.

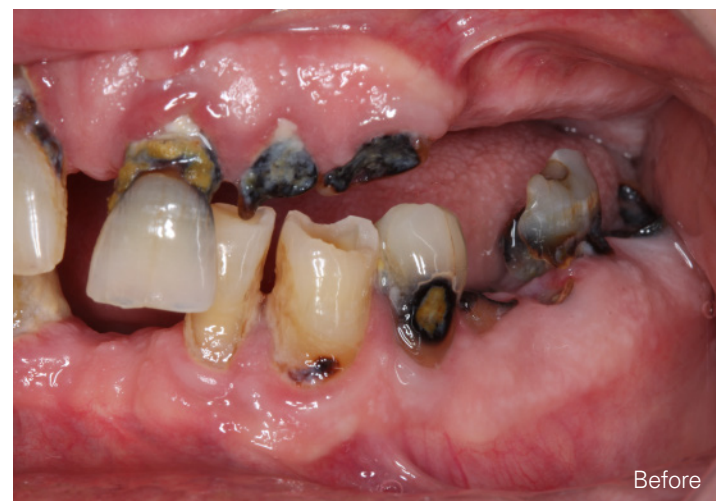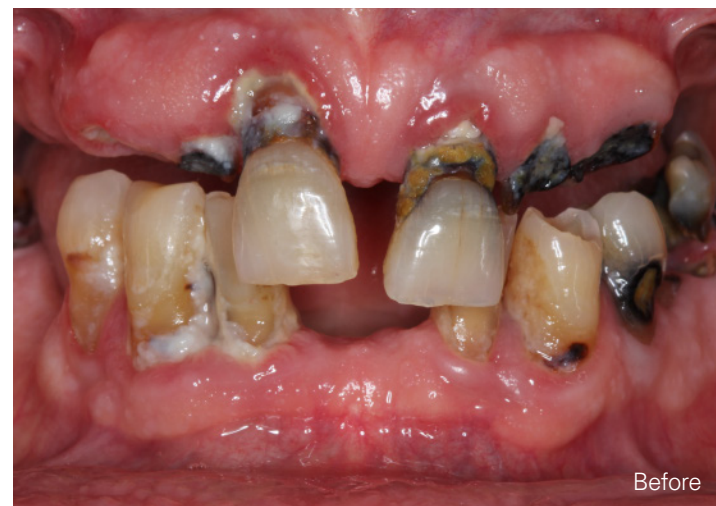Restoring Health, Function and a Return to Vitality

This gentleman suffered from a very dry mouth which led to rampant unmitigated decay. The result was tooth loss and constant pain. A plan was formulated to remove his missing teeth and to immediately replace them with dental implants. He left the office with teeth the day of teeth removal.

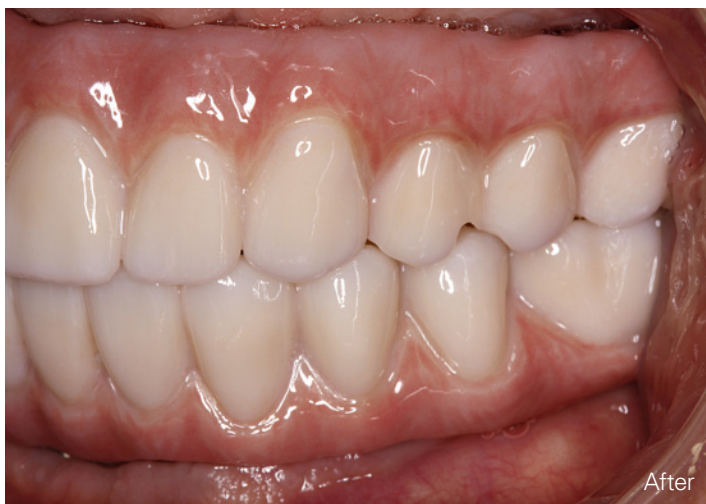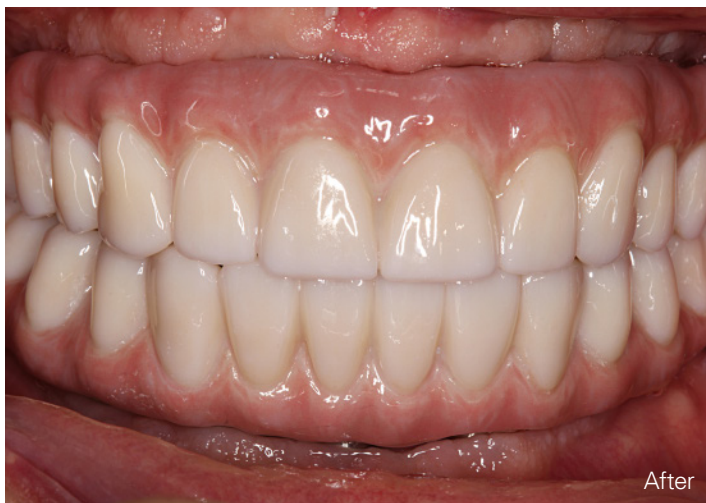The result is a healthy mouth, excellent esthetics and a very happy pain free patient. "I could not be happier with the result. My mouth is no longer a source of pain. I immediately felt healthier, and that was the day after surgery."





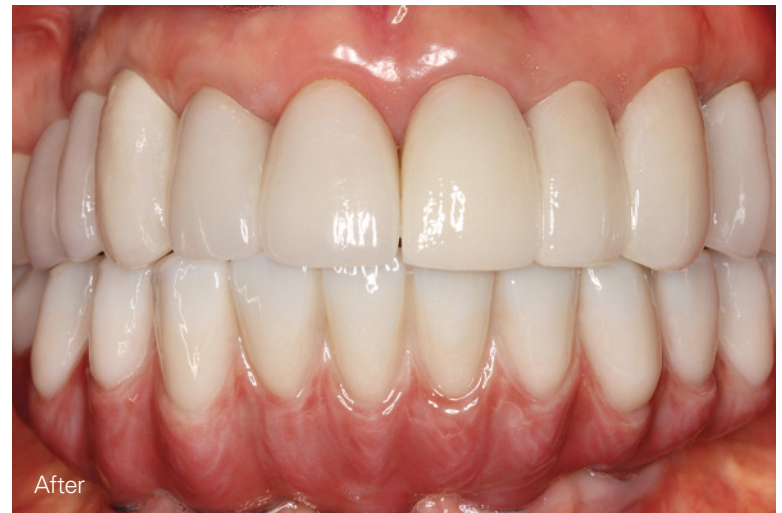
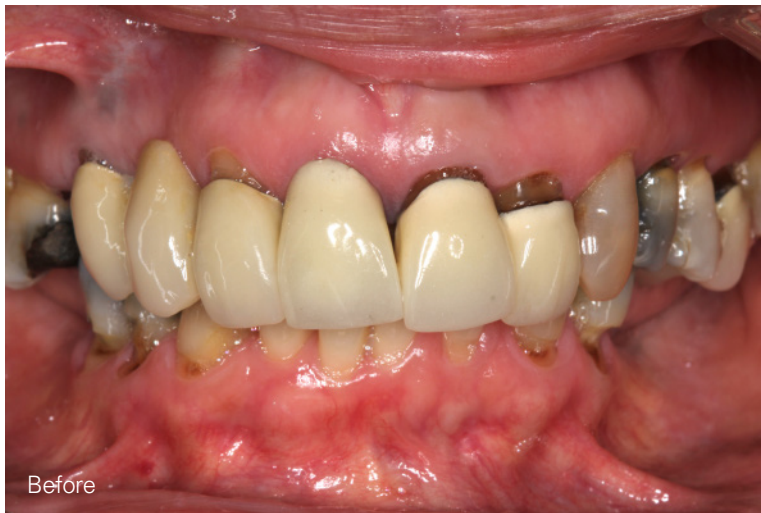
Immediate transition to health, esthetics
and function with implants



"My teeth are horrible and I cannot smile", this patient remarked at his initial visit. He was very self-conscious and a habit of covering his mouth with his hand whenever he spoke. He was not aware of what modern dentistry could do for him.

Following extractions and immediate implant placement he was completely restored to health. Today he smiles confidently, is very happy, and can eat whatever he wants.

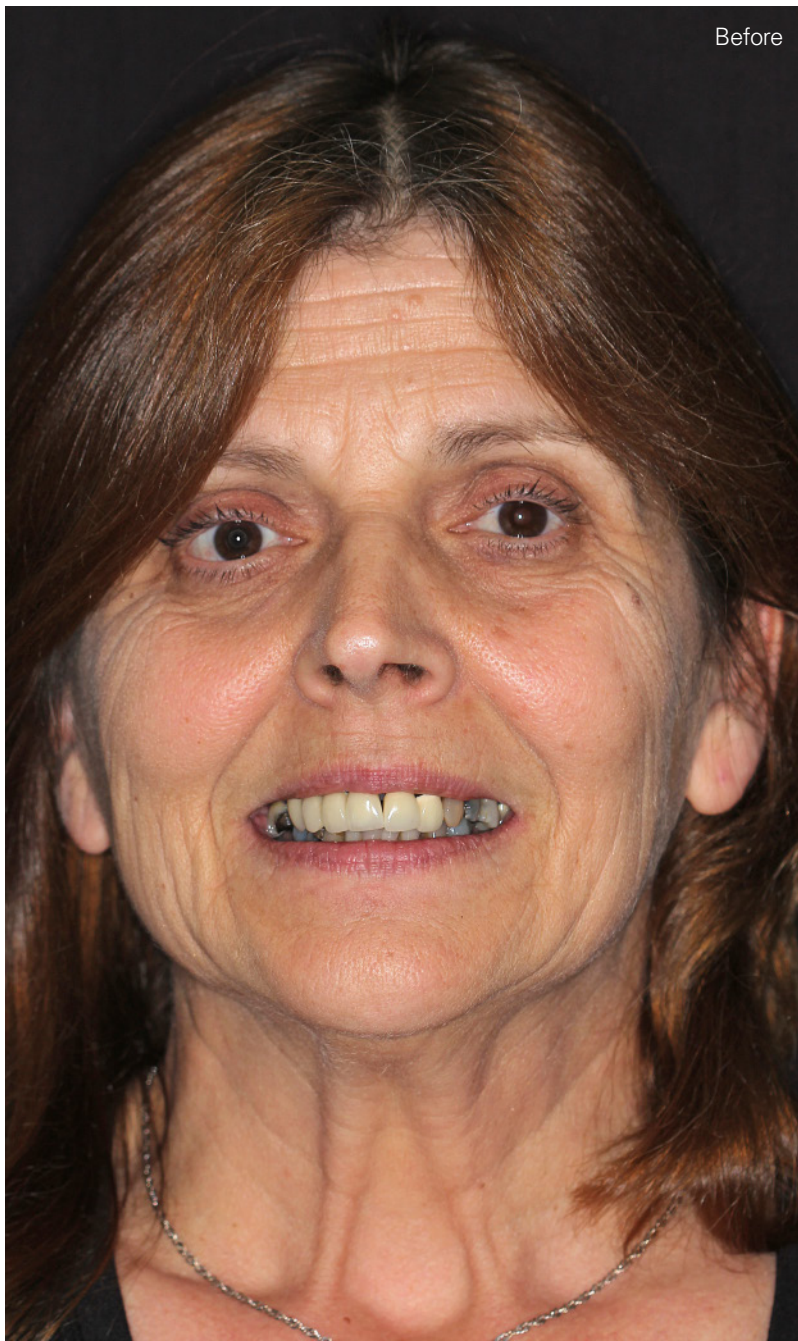

A Combined Approach Immediate Implants on the Bottom and a Staged Approach Up Top

Many patients go through life without ideal dental care. Oftentimes dental treatment results in segmented care without a long-term approach to the eradication of dental disease. Our practice philosophy is to treat dental disease and to restore our patients to function, health and esthetics. Once restored, our goal is to keep our patients healthy. This requires a preventive maintenance program which ensures long term health.

This patient has a complete implant reconstruction on the lower jaw. The teeth were removed and the implants placed simultaneously. On the upper jaw, we elected to keep some teeth and replace the missing ones with dental implants.

She is now healthy, happy and dentally stable for the first time in many years. Our goal (the patient's and ours) is to keep her that way. With regular cleanings, she will be able to keep her mouth healthy for years to come.



Before

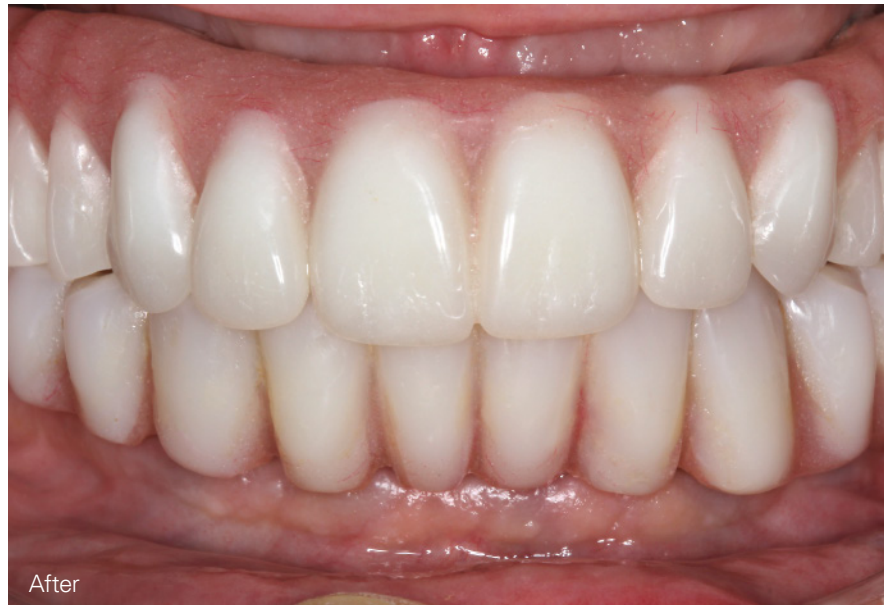
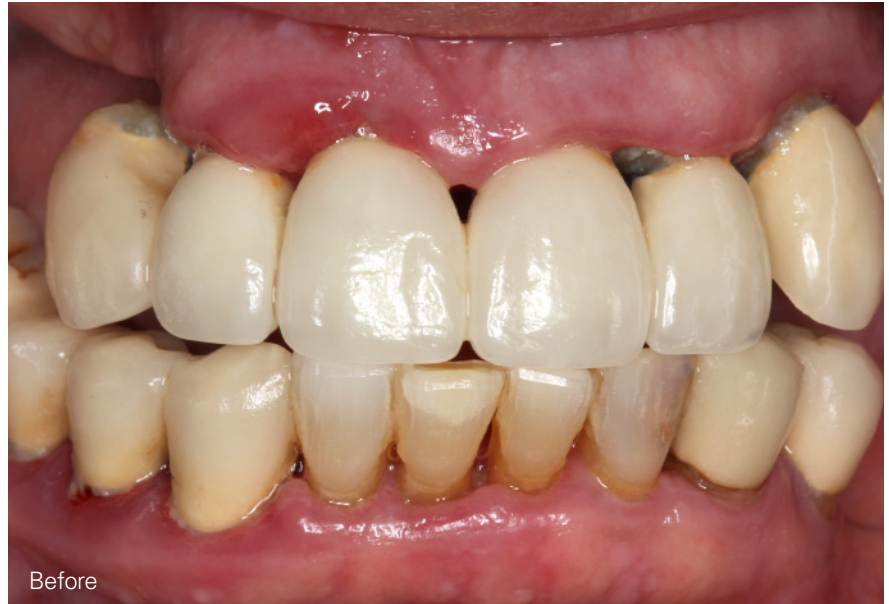
After

Turning Back the Hands of Time A Total Smile Makeover

This beautiful woman and former model presented with a hopeless dental situation. "I was told by my previous dentist that implants were not possible," she stated at her initial visit. She was surprised that an implant reconstruction was not only possible, but routine.

In one day, her lower teeth were removed and dental implants placed. Lower teeth were immediately placed on the dental implants and the patient could smile and eat that evening. The upper jaw required bone reconstruction prior to implant placement. However, the patient was never without teeth. Today her upper and lower teeth are completely implant supported. She is comfortable and can eat all foods without pain or difficulty. Six years later she looks even more beautiful. "People comment to me all the time about my beautiful smile. I would definitely recommend implants because people should always be the best they can be, no matter what age they are," she stated with confidence.

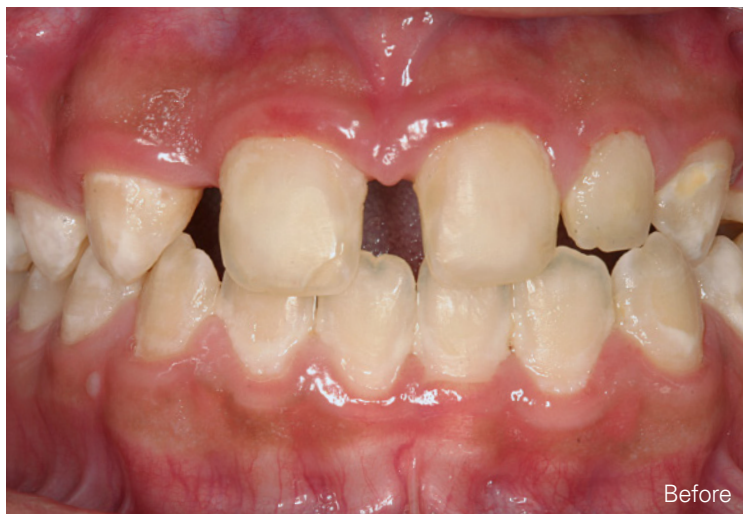



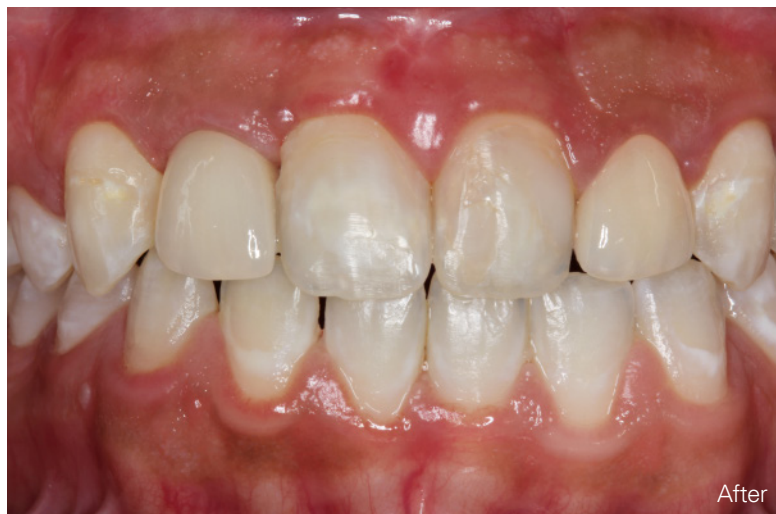Before



After




Before



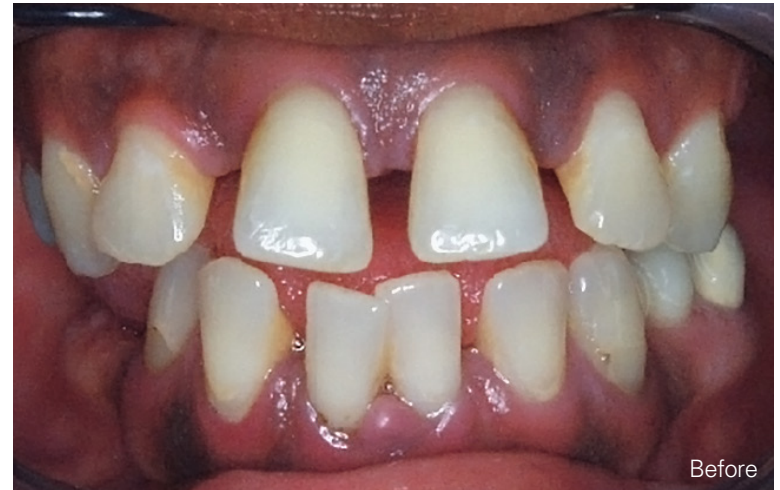After

Two Implants Saved this Young Man from a Mouth of Crowns

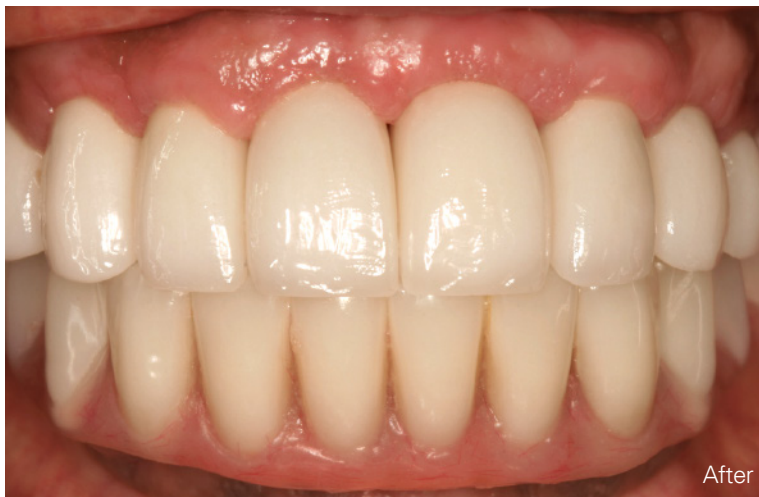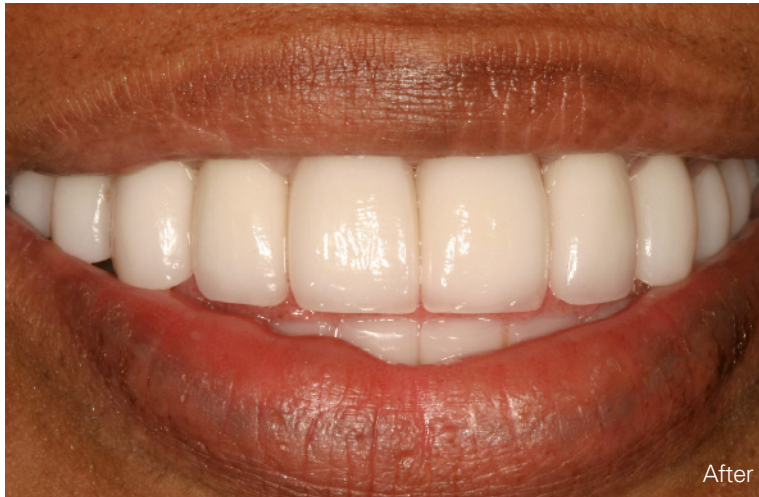This young man was told that he needed 14 crowns. After careful examination, diagnosis and treatment planning, a solution was cobbled that eliminated the need for crowning of his natural teeth. Orthodontics provided the answer. Congenitally missing two natural teeth, space was created for two implants following orthodontics. Bone grafting was necessary and completed during the active phase of orthodontics, allowing immediate placement of dental implants after orthodontic care. His self-confidence skyrocketed following care and he is now pursuing his career with passion.



Implants to the Rescue



"I hate the dentist, I have partials and they are horrible, and I am phobic" this young attractive female patient told her dentist at the beginning of care. Her dental experiences were mostly emergencies, due to untreated gum disease, resulting in the loss of many of her teeth. Together we developed a plan to replace her few remaining teeth with fixed bridges on dental implants. We immediately placed dental implants and gave her fixed upper and lower bridges. Over a decade following treatment, her smile looks fabulous. The only dentistry she has required is routine cleanings. "You can see why I call my periodontist, The Magician," she volunteers 12 years later.






Michael Sonick, DMD

Michael Sonick, DMD, is an internationally known, highly regarded authority in the field of dental Implantology and Periodontology. He completed his undergraduate degree at Colgate University. He received his DMD at University of Connecticut School of Medicine and his certificate in Periodontology at Emory University. He received his implant training at Harvard University as well as the Branemark Clinic in Gothenburg, Sweden.

A full-time practicing periodontist in Fairfield, Connecticut, he is also a frequent guest lecturer in the international program at New York University School of Dentistry and the University of Connecticut School of Dental Medicine. He lectures worldwide on the subject of aesthetic implants, periodontal plastic surgery and guided bone regeneration and comprehensive treatment planning. He is the co-editor of the multi-language textbook, *Implant Site Development*, which has been translated into both Spanish and Chinese. He serves on the editorial boards of numerous journals including the *Compendium of Continuing Education* and the *Journal of Cosmetic Dentistry*, and has published numerous papers in peer-reviewed journals. He is a member of the Leading Dental Centers of the World, a Master in DSD (Digital Smile Design) and Seattle Study Club Speaker. He is a Diplomate of the International Congress of Oral Implantology. The General Dental Practice Residents at Yale New Haven Hospital awarded Dr. Michael Sonick the honor of "Teacher of the Year."

Dr. Sonick is member of the following organizations:





Rui “Ray” Ma. DMD

Dr. Ma is member of the following organizations:



Rui Ma, DMD is an experienced periodontal and dental implant surgeon who is very dedicated to his profession. He utilizes the most current technology and most up to date innovations in providing care to his patients. A fourth generation dentist raised in his family's private practice, Dr. Ma excelled in his education achieving his Doctor of Dental medicine (D.M.D) from Tufts University in Boston. Previously educated at State University of New York in Albany, he received his Bachelor of Science in Chemistry with Summa Cum Laude and graduated as class Valedictorian. Dr Ma completed his post-doctoral training in periodontics at Stony Brook University, in New York, where he was bestowed the Certificate of Advanced Graduate Study in Periodontology.

Dr. Ma currently is a member as well as co-director of the prestigious Fairfield County Dental Club, the premier continuing education facility for dentists in Connecticut. He also serves as Director of the Fairfield County Hygiene Club providing dental hygienists an opportunity to advance their clinical skills and knowledge.

He provides treatment in a knowledgeable, caring, comfortable, and most importantly pain free setting.

THE SMILE BOOK

All periodontal and implant reconstructions shown in this book were performed in the offices of Fairfield Implants and Periodontics, LLC. The final restorative (crowns, veneers, etc.) treatment was performed by our talented and caring local dental colleagues. We are fortunate to work with such an excellent group of restorative dentists, who make this excellent treatment possible for our patients.



Fairfield County Implants & Periodontics
Dr. Michael Sonick, Dr. Rui Ma & Associates
Creating Beautiful Healthy Smiles for a Lifetime



1047 Old post Road, Fairfield CT 06824
203-254-2006 - office@sonickdmd.com

www.sonickdmd.com