

cosmetic dentistry

the international C.E. magazine of beauty & science

1 2011

_c.e. article

Same day inlays/onlays
strive to save the tooth

_clinical

Two-stage esthetic
crown lengthening

_industry report

BEAUTIFIL Flow Plus:
dentistry simplified



ANNUAL DENTAL TRIBUNE STUDY CLUB SYMPOSIA AT THE GNYDM

NOVEMBER 27TH – 30TH, 2011, STARTING AT 10:00 AM DAILY



For the fourth year in a row, Dental Tribune Study Club hosts its annual C.E. Symposia at the GNYDM, offering four days of focused lectures in various areas of dentistry. Find us on the exhibition floor in aisle 6000!

Each day will feature a variety of presentations on topics, which will be led by experts in that field. Participants will earn CE credits for each lecture they attend. DTSC is the official online education partner of GNYDM.



PLEASE SEE PROGRAM DETAILS UNDER WWW.DTSTUDYCLUB.COM/GNYDM

REGISTER NOW: WWW.GNYDM.COM

ATTENDEES MUST PRE-REGISTER AS GNYDM VISITORS FOR FREE.

SUNDAY, NOVEMBER 27

-  10:00 - 11:00 DR. HOWARD GLAZER // COURSE NO. 3780
GIOMERS: NEW GIANTS OF MI DENTISTRY
-  11:15 - 12:15 DR. SHAMSHUDIN KHERANI // COURSE NO. 3790
COMPREHENSIVE DENTISTRY USING DIGITAL IMPRESSION TECHNOLOGY
-  12:45 - 1:45 DR. RON KAMINER // COURSE NO. 3800
THE HOTTEST TOPICS IN DENTISTRY
-  2:00 - 3:00 DR. LOUIS MALCMACHER // COURSE NO. 3810
MINIMALLY INVASIVE DENTISTRY: TIPS AND TRICKS TO MAXIMIZE SUCCESS
-  3:15 - 4:15 TBA // COURSE NO. 3820
TECHNOLOGY TO IMPROVE YOUR CARIES MANAGEMENT
-  4:30 - 5:30 DR. GEORGE FREEDMAN // COURSE NO. 3830
EVOLVING CONSERVATIVE RESTORATIONS

TUESDAY, NOVEMBER 29

-  10:00 - 11:00 DR. GEORGE FREEDMAN AND DR. FAY GOLDSTEP // COURSE NO. 5690
INNOVATIONS THAT WILL CHANGE YOUR PRACTICE FOREVER
-  11:15 - 12:15 TBA // COURSE NO. 5700
THE IMPORTANCE OF THE FLAP DESIGN IN RELATION TO THE TYPE OF THE UNDERLYING BONE DEFECT
-  12:45 - 1:45 DR. GEORGE FREEDMAN AND DR. FAY GOLDSTEP // COURSE NO. 5710
THE DIODE LASER: THE ESSENTIAL SOFT TISSUE HANDPIECE
-  2:00 - 3:00 DR. SELMA CAMARGO // COURSE NO. 5720
LASERS IN ENDODONTICS: CLINICAL APPLICATION FOCUS ON DIFFICULT CASES
-  3:15 - 4:15 JULIA WEHKAMP // COURSE NO. 5730
ONLINE LEARNING: A NEW APPROACH TO CONTINUING DENTAL EDUCATION
-  4:30 - 5:30 DR. MARIUS STEIGMANN // COURSE NO. 5740
MY FIRST ESTHETIC IMPLANT CASE - WHY, HOW, & WHEN?

*THIS PROGRAM IS SUBJECT TO CHANGE

MONDAY, NOVEMBER 28

-  10:00 - 11:00 DR. FAY GOLDSTEP // COURSE NO. 4670
WHAT PATIENTS WANT... WHAT DENTISTS WANT: EASY, HEALTHY DENTISTRY!
-  11:15 - 12:15 DR. SHAMSHUDIN KHERANI // COURSE NO. 4680
LASER DENTISTRY OVERVIEW WITH AN UPDATE ON CLOSED FLAP OSSEOUS
-  12:45 - 1:45 DR. LARRY EMMOTT // COURSE NO. 4690
REMEMBER WHEN "E" WAS JUST A LETTER? USE E-SERVICES TO IMPROVE PATIENT CARE AND INCREASE PROFITABILITY
-  2:00 - 3:00 DR. GEORGE FREEDMAN AND DR. FAY GOLDSTEP // COURSE NO. 4700
DIODE LASERS AND RESTORATIVE DENTISTRY
-  3:15 - 4:15 DR. DAMIEN MULVANY // COURSE NO. 4710
WHY VIEW YOUR 3D PATIENTS WITH 2D IMAGES? A COMMON SENSE APPROACH TO 3D IMAGING IN THE GENERAL PRACTICE
-  4:30 - 5:30 DR. MARTY JABLOW // COURSE NO. 4720
UNDERSTANDING THE ADVANCES IN SELF-ADHESIVE TECHNOLOGY AND HOW TO INCORPORATE THEM INTO YOUR RESTORATIVE PRACTICE

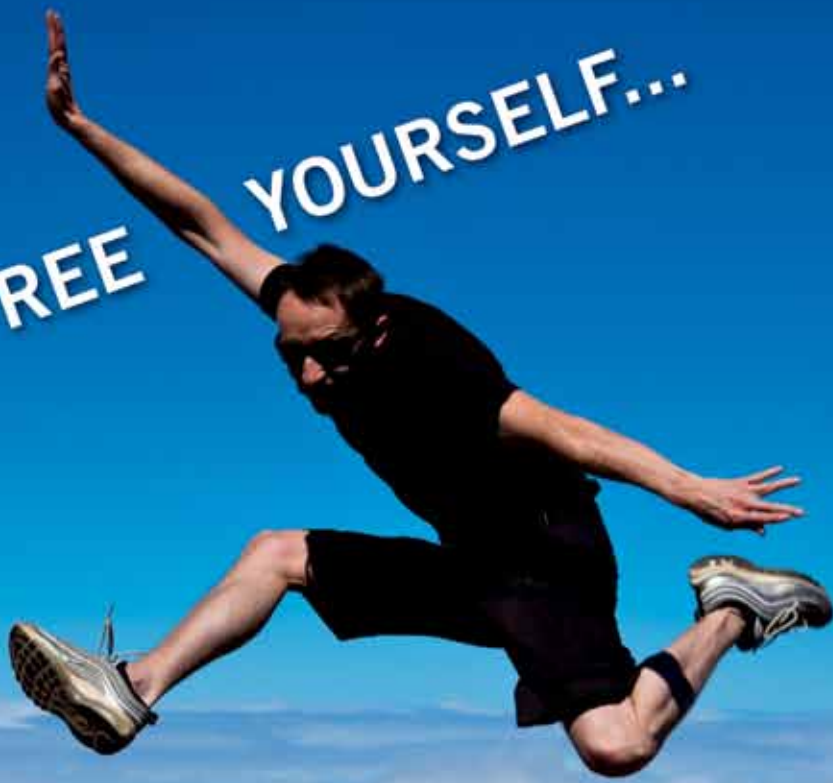WEDNESDAY, NOVEMBER 30

-  10:00 - 11:00 DR. MARIUS STEIGMANN // COURSE NO. 6600
MY FIRST ESTHETIC IMPLANT CASE - WHY, HOW, & WHEN?
-  11:15 - 12:15 DR. GEORGE FREEDMAN AND DR. PAT ROETZER // COURSE NO. 6610
CEMENTING ALUMINA AND ZIRCONIA RESTORATIONS
-  12:30 - 5:00 **OSSEO SUMMIT**
DR. DAVID HOEXTER, ALONG WITH VARIOUS IMPLANT EXPERTS // COURSE NO. 6620
THE 2ND ANNUAL OSSEO UNIVERSITY SUMMIT: REVOLUTIONARY IMPLANT DESIGN UNVEILED



For more information, please contact
Julia E. Wehkamp, C.E. Director, Dental Tribune Study Club
Phone: (416) 907-9836, Fax: (212) 244-7185
E-mail: j.wehkamp@DTStudyClub.com

FREE YOURSELF...



... AND TRY OUR BEST HANDLING COMPOSITE EVER!

89% fillers by weight:

- Outstanding wear resistance
- Enhanced color stability

30-50% less resin compared to classic hybrid and pseudo nano composites:

- Low shrinkage of only 1.6 vol. %
- Non-sticky
- Prolonged working time under ambient light

Designer Nano particles:

- Excellent polishability and polish retention
- Tooth-like modulus of elasticity
- Tooth-like thermal expansion and flexural strength

Call 1-888-658-2584

GrandiOSO

89% filled universal Nano Hybrid Composite
The Combination of handling, esthetics and performance.



TRY GRANDIOSO NOW
FOR JUST **\$58**



REF 2646 Trial Kit 8 X 0.25 Caps
(2 X A1, 2 X A2, 2 X A3, 2 X A3.25)
1 X 1g GrandiOSO Heavy Flow
syringe A2, 1 X Dimanto Polisher

Welcome to cosmetic dentistry



Torsten Oemus
Publisher
Dental Tribune International

The goal of this quarterly magazine is twofold. First, it seeks to share practical dental knowledge that can be put to use in your day-to-day practice. Second, it is a vehicle to help you chip away at your continuing education (C.E.) requirements.

The amount of new information available in the dental field about new products, techniques and research data is astounding. Running a practice and seeing patients leaves little time for catching up on the latest clinical news and product information. Thus, we hope *Cosmetic Dentistry* will not only be a welcome respite for those rare chunks of time you can devote to leisurely reading, but one that provides a practical return on your investment by providing information that you can actually put to immediate use.

In addition, we know that taking time away from the practice to pursue C.E. credits is costly in terms of lost revenue and time. As a quarterly magazine, *Cosmetic Dentistry* is here to help you chisel at least four C.E. credits per year out of your already busy life without the lost revenue and time away from your practice. To that end, every edition of *Cosmetic Dentistry* will include at least one hour of ADA CERP-certified C.E. credit where readers can answer questions about the materials at www.dtstudyclub.com to earn this credit. Annual subscribers to the magazine (\$50) need only register at the Dental Tribune Study Club website to access these C.E. quizzes free of charge.

In fact, even non-subscribers may take the C.E. quiz after registering on the DT Study Club website and paying a nominal fee. If you are a practitioner with a penchant for words, it might also interest you to know that authors of the C.E.-accredited articles receive 15 percent of the fees collected from the non-subscribers who take the C.E. quiz online. The C.E. quiz for the articles in this edition will be available online on July 25.

Dental Tribune America is part of the largest dental publishing network in the world, Dental Tribune International (DTI), which consists of 23 license partners around the globe. The DTI network publishes a variety of dental publications that are distributed in more than 90 countries. Please visit us online at www.dental-tribune.com to see the variety of publications we offer, and at www.dtstudyclub.com to see the complete list of online and offline C.E. opportunities available. In the meantime, we hope you enjoy the first edition and welcome your feedback.

Sincerely,

A handwritten signature in black ink, appearing to read 'Torsten Oemus'.

Torsten Oemus
Publisher

Pacific Dental Conference

March 8–10, 2012 Vancouver, BC

Join us in Vancouver for Canada's premier dental conference!

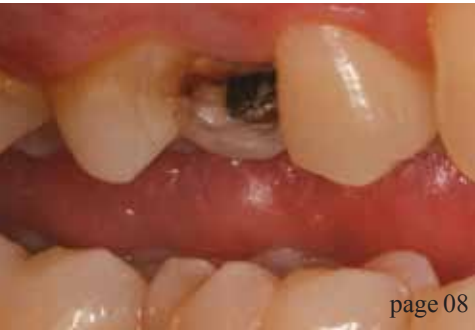

- Earn up to 15 hours of CE credits during three days of lectures and hands-on courses
- Over 100 speakers and 150 open sessions and hands-on courses to choose from, as well as the Live Dentistry Stage in the Exhibit Hall
- Enjoy the largest two day dental tradeshow in Canada featuring all the newest equipment and products at over 500 exhibitor booths in the spacious PDC Exhibit Hall
- Lunches and Exhibit Hall Receptions included in the registration fee
- Online hotel reservations now available
- Shopping, hotels, restaurants and breath-taking Stanley Park are all within blocks of the spectacular Vancouver Convention Centre
- Scenic two hour drive to world famous Whistler Mountain for spring skiing and snowboarding

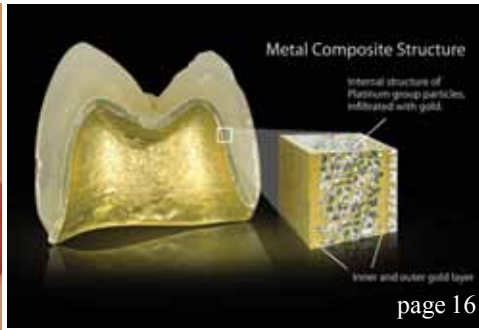


Easy online registration opens October 14th, 2011 at...

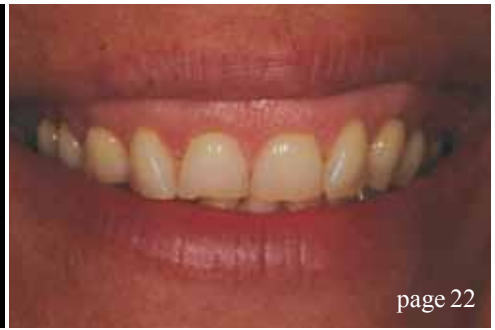www.pdconf.com



page 08



page 16



page 22

| editorial

- 04 Welcome to **Cosmetic Dentistry**
_Torsten Oemus, Publisher

| C.E. articles

- 08 Same-day **inlays/onlays** strive to save the tooth
_Lorin Berland, DMD, FAACD, and Sara Kong, DDS
- 16 Clinical indications for a **composite metal PFM restorative**
_Bary F. McArdle, DMD

| clinical

- 22 Two-stage esthetic **crowns lengthening**
_Michael Sonick, DMD, Stephen Rothenberg, DMD and Debby Hwang, DMD

| events


- 26 Practical education for the **implant dentist**
- 28 DTSC Symposia at the **Greater N.Y. Dental Meeting**
_Julia Wehkamp, Dental Tribune Study Club C.E. Director

| industry report

- 29 GrandioSO: the ultimate **handling and performance** composite
- 32 **Nitrous oxide/oxygen sedation:** multidisciplinary application resurgence
- 34 Pola celebrates **10 years**
- 36 Universal **self-etch bonding agent**
- 37 An advancement in **flowable composites**
- 38 BEAUTIFIL Flow Plus: **dentistry simplified**
- 40 Quick technique: **Tetric EvoCeram**
- 43 A **composite** for every need
- 46 Do you require **patient referrals** and higher **case acceptance** rates?
_Harold Meredith


| about the publisher

- 49 _submissions
- 50 _imprint



| on the cover


Cover image courtesy of SDI Ltd.



page 26



page 28



page 29



Let Us Create It!

Visit Us At The AGD, Booth 1016

Website Design
Logo & Brand Design
Networking Campaigns
Custom On Hold Messaging
Custom Brochures & Gift Cards
Newspaper & Mailing Campaigns
Signage, Window & Wall Graphics
DentalVision 3.0 Custom Video Presentations

877-265-9069

www.DentalMarketers.com



Same-day inlay/onlays strive to save the tooth

Authors_Lorin Berland, DDS, FAACD, and Sarah Kong, DDS

c.e. credit part I

This article qualifies for C.E. credit. To take the C.E. quiz, log on to www.dtstudyclub.com. The quiz will be available on July 25.

The name of the game in dentistry today is to save the tooth for use in the future. In this age of adhesive dentistry, respecting and preserving the remaining healthy tooth structure as well as improving esthetics have become components of value as well. With today's advanced technology and materials, longevity is mainly a matter of diagnosis, correct treatment planning and proper execution of technique.

The problem with replacing old amalgams with tooth-colored composites is that they are difficult, inconsistent and unpredictable. Yet, the warranty on these 30-, 40- and 50-year-old silver fillings is running out. We have to remember that amalgam technology is more than 150 years old. At that time, people lost their teeth a lot earlier and died a lot earlier, too.

Now, however, we have a population that is over 50 years old and growing – and they want to keep their teeth feeling good and looking good. Patients are now living longer and they want and expect to keep their teeth for a lifetime.

Adhesive dentistry offers a more conservative restorative approach to conventional dentistry. Why take away healthy tooth structure when there's a viable alternative? Why not attempt to save the good and just replace the bad? Direct composites

and laboratory composite resin systems are valuable and worthwhile options to preserve tooth structure and long-term dental health. After all, preserving a patient's natural tooth, whenever possible, is always in his or her best interest.

It has been our experience that providing multiple, large interproximal posterior composites directly can be difficult to achieve on a consistent basis in the oral environment, especially when replacing amalgams. Why? Because they take a lot of chair time. Amalgams require bulk. That's why we were taught the block type preparation to provide the necessary bulk for strength.

Furthermore, because amalgams do not bond, we were taught to create undercuts and "extension for prevention." As mercury contracts and expands with cold and hot temperature changes over time, cracks form in the glasslike nature of teeth.

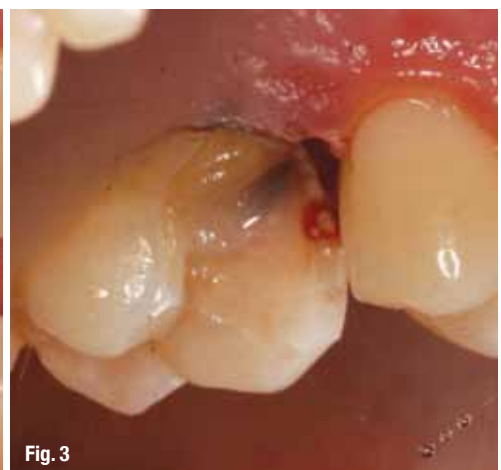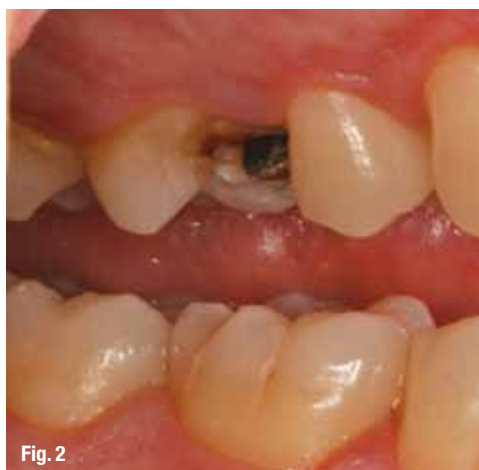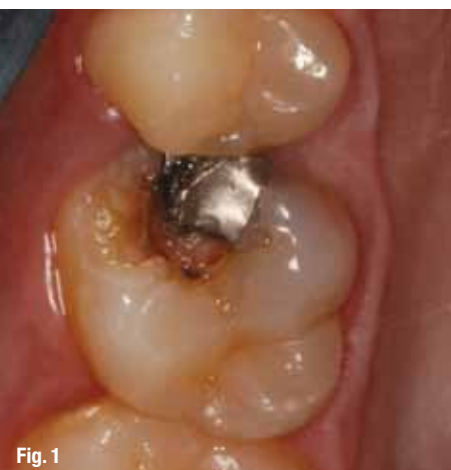Most of the time, these large preps are difficult to restore with direct composite. There are isolation and contamination issues, and it is difficult to replicate nature in the mouth in a timely, cost-effective and predictable manner for every case, every time. In addition, curing in layers makes for a long appointment and increases the possibility of contamination. It is uncomfortable for patients to keep their mouths open for the prolonged amount of time necessary.

Fig. 1_#3 pre-op, palatal view.

(Photos/Provided by Dr. Lorin Berland and Dr. Sarah Kong)

Fig. 2_#3 pre-op, buccal view.

Fig. 3_Decay removed and lining placed.



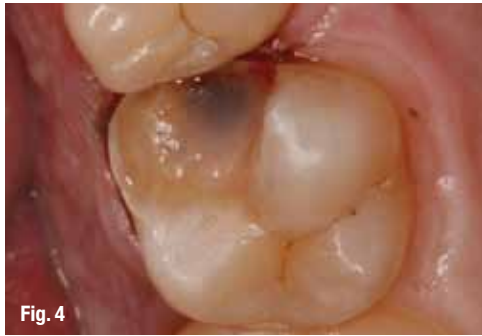

Fig. 4

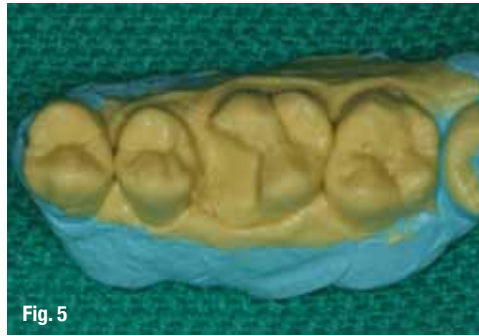

Fig. 5

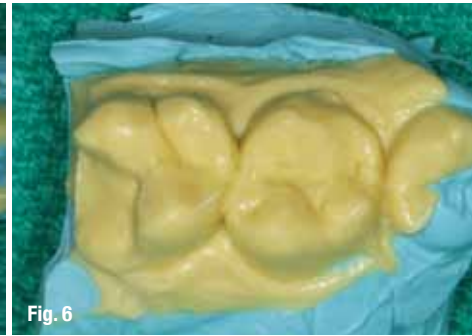

Fig. 6

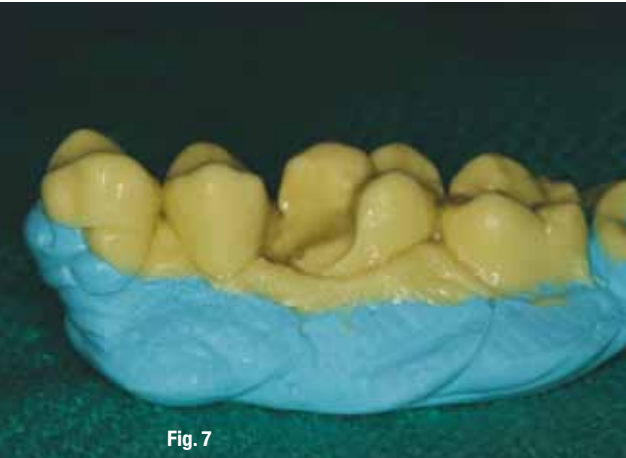


Fig. 7

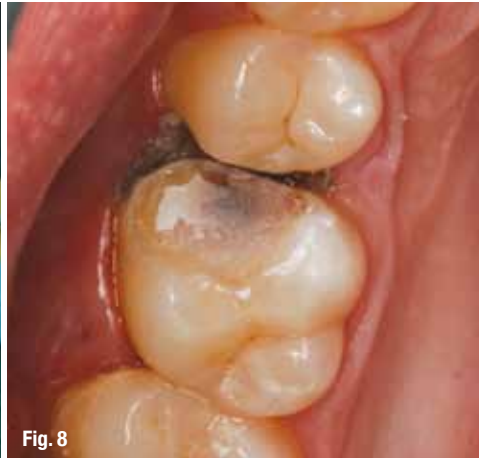

Fig. 8

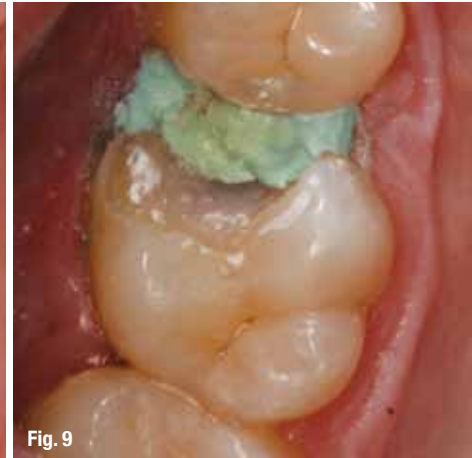

Fig. 9

Often, large direct posterior composite resins yield unsatisfactory results in terms of esthetics, and especially long-term function, due to curing and contamination issues.

However, when we do same day inlay/onlays out of the mouth and in the laboratory, we find that multiple posterior restorations are easier, stronger and more anatomically correct. Because they are processed at the same time, they can be even more time efficient than using a CAD/CAM system and reduce tooth movement during the transitional phase that can result in altered contact or occlusion.

Not having to deal with provisional restorations absolutely eliminates those untimely emergencies when temporaries break or come off. Those costly, non-productive, uncomfortable and unhappy second appointments can also be avoided, saving every-one time and money. In addition, without concerns about retention of temporaries, preparation can be even more conservative.

Case No. 1

In this case, the patient came to our office on an emergency basis with a broken tooth on the upper right molar. It was no surprise that the tooth had a previously placed MO amalgam with recurrent decay that caused the mesiobuccal cusp to fracture off completely (Figs. 1, 2). Often, teeth that have had old amalgam fillings tend to break due to cracks caused

by the expansion and contraction of the metal alloy in the tooth's glasslike substance.

In addition, caries detectors were non-existent when the bulk of amalgam restorations were placed so many teeth have recurrent decay under the old amalgam fillings.

After thorough clinical and radiographic examinations were performed, it was determined with the patient's input that a same-day onlay would be the most prudent option for this tooth. This way, he would be receiving the maximum amount of care in the least amount of time.

The procedure

After placing topical anesthetic, articaine HCl 4 percent with 1:1,00,000 epinephrine was administered to achieve profound anesthesia. Next, a nitrous oxide nasal mask was placed to decrease the patient's exposure to mercury aerosol while the amalgam was being removed. In this case, because the patient opted not to use nitrous oxide, pure oxygen was administered through the nasal mask.

We continued by isolating tooth #3 with a rubber dam. This step was essential to reduce the amount of amalgam ingested by the patient. It also offers isolation, higher visibility and better dentistry for our patients. If doing quadrant dentistry, I like to use the split-dam technique, which stretches to include several adjacent teeth in a quadrant. A FenderWedge

Fig. 4_Prepped tooth, palatal view.

Fig. 5_Silicone model.

Fig. 6_Sectioned model.

Fig. 7_Silicone model, buccal view.

Fig. 8_Tooth ready to bond.

Fig. 9_Expasyl placed interproximally prior to seat.

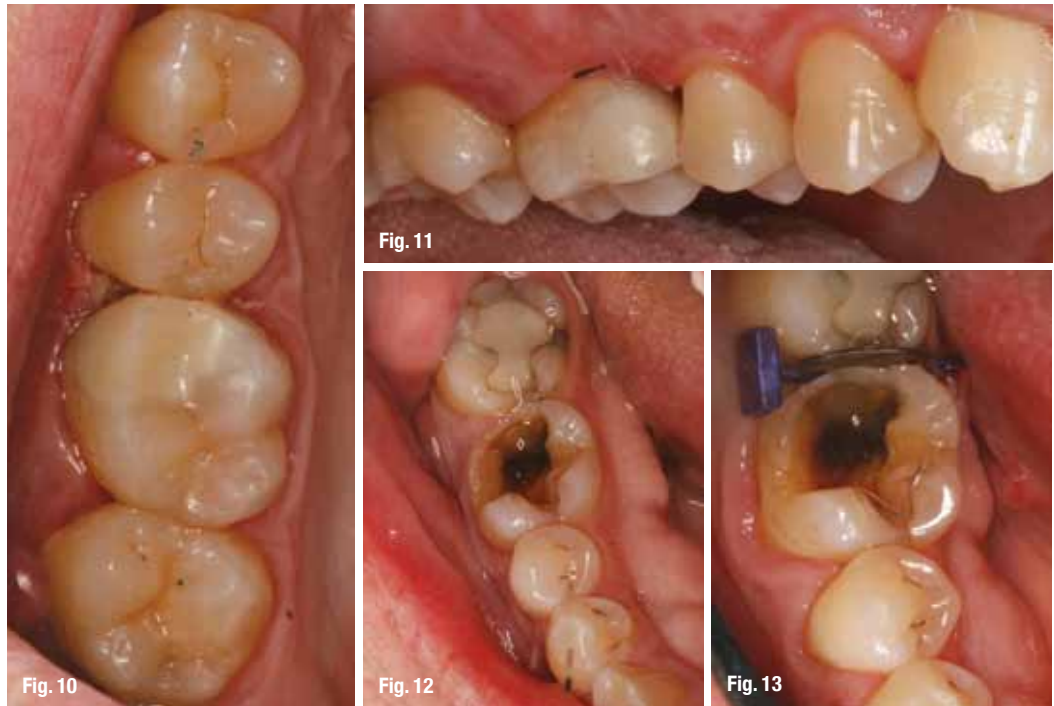


Fig. 10_Onlay seated, palatal view.

Fig. 11_Onlay seated, buccal view.

Fig. 12_#30 pre-op.

Fig. 13_FenderWedge in place.

(Directa) was then placed to separate and protect the adjacent tooth during prep, air abrasion, etching, bonding and refining while continuing to wedge the teeth for a tighter interproximal contact in the final restoration.

To facilitate removal of the remaining amalgam restoration, an hourglass-shaped diamond bur was used as diamonds are less likely to produce the fracture and craze lines associated with carbide burs. High-speed evacuation was used throughout the procedure to help decrease possible inhalation and ingestion during amalgam removal.

Caries detector was painted onto the prepared surface, and it was noted that cracks associated with the long-time expansion and contraction of the mercury-filled amalgam restoration had contributed to the apparent interproximal decay. Once the decay was carefully and completely excavated using a small, round diamond bur and a spoon excavator, the tooth was insulated in a few important steps (Fig. 3).

First, disinfectant was placed on the prepared dentinal surface (Hemaseal Et Cide, Advantage Dental Products) and air-thinned. Then, two coats of

self-etching bonding agent (OptiBond All-In-One Unidose, Kerr Dental) were placed to provide reduced postoperative sensitivity and high dentin bond strength.

After air thinning and light curing, a flowable composite (Premise Flowable, Kerr Dental) in the lightest shade was added to the internal walls and floor to create an even floor and to fill in undercuts that were originally prepared for amalgam retention. A flat-end cylinder, fine-grit, short shank diamond was used to refine the tooth preparation after insulation was completed (Fig. 4).

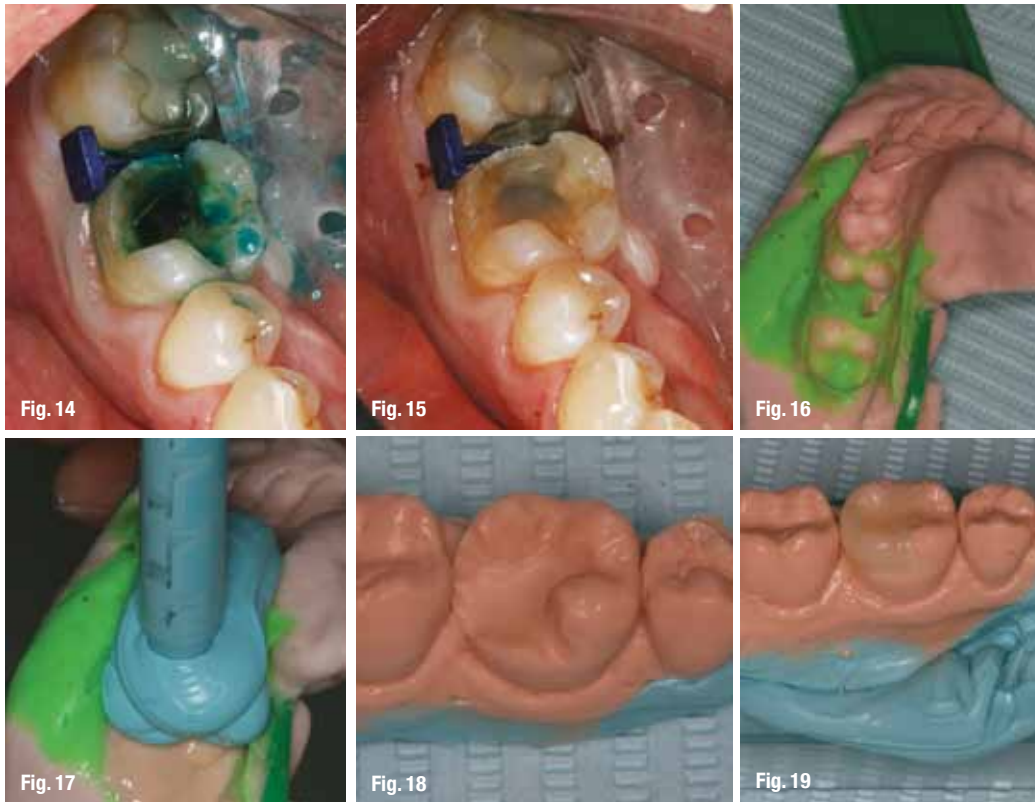
Next, two Identac hydrocolloid alginate impressions (Dux Dental) were taken fast and accurately. They take only 90 seconds to set with our chosen materials, so they are ideal for same-day inlay/onlays. Before expressing the hydrocolloid material into the prepped tooth, we squirted a little surfactant (Prep-Wet Plus, Dux Dental) onto the tooth to wet the prep while my assistant mixed the alginate.

Meanwhile, a second assistant was loading a syringe with warm Identac Syringable Hydrocolloid Cartiloids (Dux Dental) to hand to me. The "plug" was

‘Adhesive dentistry offers a more conservative restorative approach to conventional dentistry.

Why take away healthy tooth structure when there’s a viable alternative?

Why not attempt to save the good and just replace the bad?’



initially squirted away from the prep and then into the prep itself so as not to interfere with a "clean" impression. Once the tray had been loaded with the alginate (Identac, Dux Dental), the first assistant handed it to me. The tray was inserted with gentle pressure and held steady for 90 seconds. Another impression was taken using the same aforementioned steps.

The patient then had about an hour break while the inlay was being made and was able to make the most efficient use of his time by having his teeth cleaned with the hygienist during this break in treatment. This not only made the time seem to go by faster for the patient, but it also eliminated "dead time" in our schedule.

The patient made the most of his time in the chair, fixing his broken tooth and getting his teeth cleaned. This type of combination treatment lends itself to a more productive day when scheduled this way, and patients really appreciate it.

Lab work

Meanwhile, back in the lab, the impressions were first disinfected and then poured with MACH-SLO (Parkell) and based with bite registration material on a C-Bite articulator (C-Bite, Dental Products) (Fig. 5). An electric waxing unit was used to block out any undercuts on the die (Ultra Waxer, Kerr Lab).

The onlay was incrementally built in composite layers with a D2 primary dentin base shade (Premise

Indirect Primary Dentin, Kerr Dental) followed by an A2 facial dentin shade (Premise Indirect Facial Dentin, Kerr Dental) and a neutral incisal shade (Premise Indirect Incisal, Kerr Dental).

Once the onlay was cured with light, heat and pressure in the BelleGlass curing unit (Kerr Dental) for 10 minutes, it was fitted, adjusted and polished on the silicone models (Figs. 6, 7) with various burs and polishing wheels. All margins, contacts and contours were easily and accurately verified outside the mouth, saving valuable chair time and clinical frustration.

Seating the onlay

When seating the onlay, a medium size Isolite (Isolite Systems) was applied for easy isolation, suction, bite rest and illumination during the cementation of the onlay. No further anesthesia needed to be administered as the tooth had been lined with flowable composite during the prep stage. Patients really appreciate this – especially because they are almost back to "normal" by the time they leave.

The onlay was then tried in to verify proper contacts, contours, margins and esthetics. Before cementation, Expasyl (Kerr Dental) was gently packed into the sulcus (Fig. 8). The aluminum chloride dried the tissue, reducing the risk of sulcal seepage and contamination. The FenderWedges were then inserted beneath the interproximal floor to slightly

Fig. 14 Caries detector.

Fig. 15 Prep with liner.

Fig. 16 Identac Hydrocolloid impression.

Fig. 17 Basing the poured impression.

Fig. 18 Silicone model.

Fig. 19 Model with undercuts waxed.

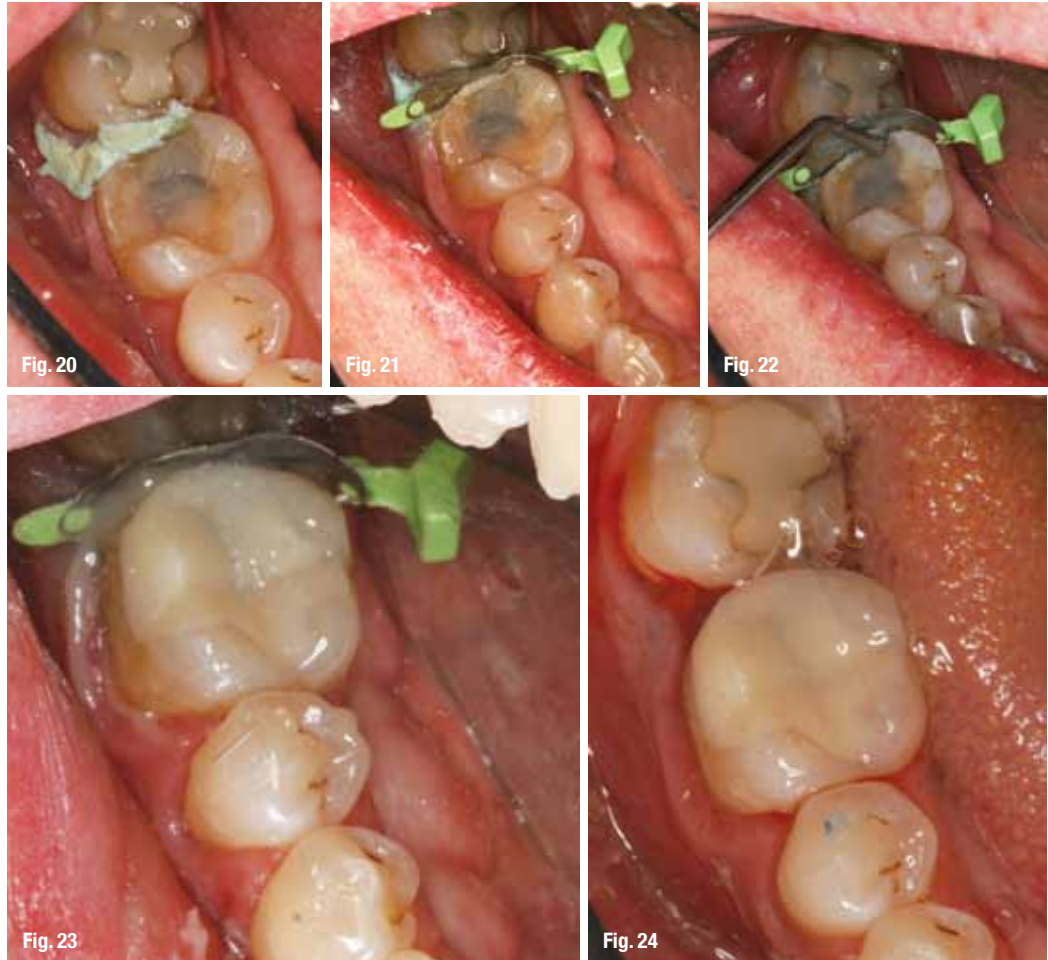

Fig. 20_ Exspasyl prior to seat.
Fig. 21_ Exspasyl and FenderMate prior to seating.
Fig. 22_ Adapting FenderMate.
Fig. 23_ Seating onlay.
Fig. 24_ Final onlay.

separate and isolate the adjacent teeth and to help facilitate seating the onlay.

After rinsing the Exspasyl (Kerr Dental) thoroughly, the enamel and composite core were gently micro-etched with aluminum oxide (EtchMaster, Groman Dental) to increase retention and remove any debris. Then the enamel and composite core were etched for 15–30 seconds. A single component, fifth-generation adhesive (OptiBond Solo Plus Unidose, Kerr Dental) was applied in two coats and air-thinned until there was no more movement. The enamel should be glossy (Fig. 9). Flowable composite (Premise Flowable, Kerr Dental) was dispensed into the prepped tooth and then the inlay was inserted into the tooth.

The FenderWedges were removed and the onlay was further seated using the Titanium-coated #21 Acorn with gentle pressure. Complete seating was facilitated using the contra-angle packer/condenser while an explorer was helpful in removing excess flowable before curing. When dealing with onlays involving interproximal surfaces, it is a good idea to floss after seating the onlay and before curing. The restoration was cured from all angles, starting at the interproximal gingival floors where leakage is most likely to occur.

Occlusal flash and excess flowable composite were then “buffed” with a short flame carbide while the interproximal margins were adjusted with bullet or needle carbides. Sometimes a Bard Parker #12 scalpel and Qwik Strip (Axis) are used to allow for easier removal of interproximal cement.

Once the proper occlusion was established, a diamond-impregnated point and/or cup was used to polish the restoration. Polishing was further enhanced through the addition of polishing paste.

In just one appointment, an esthetic and conservative interproximal onlay replacing a mesiobuccal cusp was prepped, placed and polished (Figs. 10, 11).

Case No. 2

This patient also came in with a dental emergency. The filling had fallen out of his broken, lower right molar the day before he was going overseas for three weeks on business. He wanted a “quick and permanent solution” (Fig. 12).

First the tooth was anesthetized. Next, a FenderWedge was used to isolate the involved tooth, protect the adjacent interproximal surface and pre-wedge the teeth for optimal contacts (Fig. 13). The Isolite

was placed to obtain a dry and illuminated field. We used caries detector to ensure complete decay removal (Fig. 14). The tooth was then microetched, etched and desensitized with HemaSeal and Cide (Advantage Dental Products). Two layers of self-etching bonding agent (OptiBond All-In-One Unidose, Kerr Dental) were applied to provide reduced postoperative sensitivity and high dentin bond strength. This was then air-thinned and light-cured.

Flowable composite (Premise Flowable, Kerr Dental) was added to the internal walls and floor, creating an even floor and filling in undercuts that were originally prepared for caries removal and amalgam retention (Fig. 15). After the tooth was insulated, the prep was refined with a flat-end cylinder, fine-grit, short shank diamond.

Two identical hydrocolloid impressions (Dux Dental) were then taken as before. These impressions were handed to the assistant to be poured in the lab (Fig. 16). During the time between the onlay prep and seat, a small filling was done on another tooth to make the most of this appointment time slot while the onlay was being fabricated in the lab.

Lab work

As described in Case No. 1, the assistant immediately poured the impressions in the lab with MACH-SLO (Parkell) after disinfecting them and basing them with a rigid, fast-setting bite registration material such as Blu-Mousse (Parkell) (Fig. 17). Within two minutes, we had a working silicone model on which to build the onlay (Fig. 18). The undercuts were then blocked out with an electric waxer (Ultra Water, Kerr Lab), paying special attention to avoid the margins (Fig. 19).

Starting with the Premise Indirect (Kerr Dental) dentinal shades (A2 primary dentin and A1 facial dentin) and ending with incisal shades (Neutral incisal), the onlay was incrementally fabricated in layers using various composite instruments. The onlay was then placed in the BelleGlass curing oven for heat, pressure and light curing.

In approximately 10 minutes, the onlay was ready to be finished with multiple finishing burs (Fig. 20) on the silicone models. The onlay was polished for a high shine and then checked on the model to verify accurate interproximal contacts and margins (Fig. 21).

Seating the onlay

When seating the onlay, the Isolite was reapplied for isolation, ease of placement and the patient's comfort during the cementation stage. Before cementation, Expasyl (Kerr Dental) was gently packed into the sulcus, creating a dry space between the tooth and tissue without any risk of rupturing the

epithelial attachment (Fig. 22). The aluminum chloride in the Expasyl dried the tissue, reducing the risk of sulcal seepage and contamination.

The FenderMate was then inserted beneath the interproximal floor to slightly separate and isolate the adjacent teeth and to help facilitate seating the onlay (Fig. 23). The Expasyl (Kerr Dental) was rinsed off thoroughly and the FenderMate was adapted to the adjacent interproximal surface with a condenser (Fig. 24).

Once all of this was properly placed, the enamel and composite core were first microetched to remove any debris and increase mechanical retention of the surface of the composite flowable liner. Then the surface was further prepared for bonding with 37 percent phosphoric acid for 15–20 seconds.

A single-component, fifth-generation adhesive (OptiBond Solo Plus Unidose, Kerr Dental) was applied in two coats and air-thinned until there was no more movement. No curing was done at this time. Flowable composite (Premise Flowable, Kerr Dental) in the lightest shade was then dispensed into the prepped tooth before inserting the onlay into the tooth.

Before curing, the FenderMate was removed and the onlay was further seated using a condenser with gentle pressure. Complete seating was facilitated using the contra-angle packer/condenser. An explorer was helpful in removing excess flowable before curing. Floss was applied between the involved interproximal surfaces before curing and left in place to remove excess interproximal cement and facilitate the cement removal step after curing.

The restoration was cured from all angles, starting at the interproximal gingival floors where leakage is most likely to occur. Occlusal flash and excess flowable composite was "buffed" with a short flame carbide while the interproximal margins were adjusted with bullet or needle carbides. A Bard Parker #12 scalpel and Qwik Strip (Axis) were used to remove interproximal cement and then the remaining floss was used to floss out any remaining cement and to ensure proper at-home flossing.

Once the ideal occlusion was established, diamond-impregnated points and/or cups were used to polish the restoration, starting with the coarsest grit first and finishing with the finest grit for a smooth finish while a PDQ composite polishing brush (Axis Dental) with composite polishing paste (Enamelize, Cosmedent) made for a final high shine.

Conclusion

There are certainly clear advantages for both the patient and the dentist when doing indirect composite resin restorations. These restorations have helped us save patients' teeth, time and money. Over the last

‘The problem with replacing old amalgams with tooth-colored composites is that they are difficult, inconsistent and unpredictable. Yet, the warranty on these 30-, 40- and 50-year-old silver fillings is running out. We have to remember that amalgam technology is more than 150 years old.’

20 years, we have tweaked, updated and modified these restorations in terms of techniques, materials and equipment. These restorations not only save time and conserve healthy tooth structure, they are a valuable service to provide to our patients; and they appreciate it.

Direct composites are an essential part of our armamentarium. Nevertheless, indirect composite

restorations have many advantages, especially when dealing with multiple restorations involving adjacent interproximal surfaces. There is simply no comparison between the strength of these materials made outside of the mouth with those cured in the mouth.

Moreover, it is much easier to build, control, polish and finish the occlusal, interproximal and facial/lingual morphology in the laboratory. Patients appreciate the numerous benefits of both direct and indirect composites, and they especially appreciate not having to be in cumbersome temporaries or having an inconvenient second appointment.

Perhaps the greatest advantage for the patient is being able to conserve the maximum amount of healthy structure while saving time and money – all at the same time. “The trend in dentistry today is clearly toward more esthetic and less invasive. Indirect resin and ceramic inlays and onlays are not only compatible with this trend, but fulfill very nicely the restorative void between fillings and crowns,” said Ronald D. Jackson, DDS, FAGD, FAACD (Cosmetic Tribune, Vol. 1, Nov. 4, Dec. 2008).

Regarding durability, esthetic inlays and onlays are not new anymore. They have a record of accomplishment, and it is good. Wherever you practice, and however you practice, these restorations are durable, esthetic, economical and very much appreciated!_

_about the authors

cosmetic
dentistry



Dr. Lorin Berland, a fellow of the AACD, pioneered the dental spa concept in his multi-clinician practice in the Dallas Arts District. His unique approach to dentistry has been featured on television (‘20/20’) and in national publications and major dental journals, including Time magazine. In 2008, he was honored by the AACD for his contributions to the art and science of cosmetic dentistry. For more information on The Lorin Library Smile Style Guide, www.denturewearers.com and the Biomimetic Same Day Inlay/Onlay 8 AGD Credits CD/ROM, call (214) 999-0110 or visit www.berlanddentalarts.com.



Dr. Sarah Kong graduated from Baylor College of Dentistry where she has served on the faculty in the department of restorative dentistry. She was voted a Texas Super Dentist and Texas Best General Dentist for general dentistry by her peers. Kong is part of a unique multispecialty private practice group in Dallas, www.berlanddentalarts.com, where she focuses on preventive, cosmetic, restorative and pediatric care as well as oral appliance therapy for TMJ, snoring and sleep apnea. Kong is an active member in numerous professional organizations, such as the American Academy of Cosmetic Dentistry, American Dental Association, Academy of General Dentistry, Texas Dental Association and Dallas County Dental Society, where she has served on the membership committee and the peer-review board.

AAID 60th ANNUAL MEETING

REALITIES OF IMPLANT DENTISTRY

STACKING THE DECK IN YOUR FAVOR

AMERICAN ACADEMY OF IMPLANT DENTISTRY | OCTOBER 19-22, 2011



2011

LAS VEGAS

www.aaid.com



Clinical indications for a composite-metal PFM restorative

Author_Barry F. McArdle, DMD

c.e. credit part II

This article qualifies for C.E. credit. To take the C.E. quiz, log on to www.dtstudyclub.com. The quiz will be available on July 25.

Fig. 1 The patient's worn, misaligned and discolored smile.

(Photos/Provided by Dr. Barry F. McArdle unless noted otherwise)

Fig. 2 The old smile is transformed into a naturally balanced one using Captek crowns.

Fig. 3 Shade matching with Captek and accurate clinical records is virtually perfect. The crown in this picture is on tooth #13.

Although "metal-free" has become a mantra in some dental circles, even when it comes to indirect restorations, all-ceramics have their limitations. When parafunctional habits, wear of the existing dentition, the need for subgingival margin placement, masking of discolored tooth structure or the necessity of conventional cementability contraindicate the use of these newer dental materials, the traditional porcelain-fused-to-metal restoration is called for. It has, however, fallen out of favor with many practitioners primarily because of its cosmetic shortcomings in the esthetic zone.

An alternative to conventional PFMs has proven itself as a prime option under these circumstances, both functionally and cosmetically. Captek (Argen Corp., San Diego) is a composite metal, not an alloy, whose optical properties accurately mimic those of enamel's underlying hard and soft tissues.¹

In the hands of a knowledgeable ceramist, ultimate vitality can be obtained by using this system

(Figs. 1, 2), and the shade matching attained with this material is remarkable (Fig. 3).

In addition, Captek has demonstrated micro-mechanical interlocking as its primary mechanism of porcelain adherence², which in my experience has resulted in the superior strength and fracture resistance that is often required in specific clinical situations. The Captek system uses a unique bonding mechanism (referred to as the Universal Porcelain Coupler or UCP) between the coping material and porcelain (or composite resin) that extends gold and platinum micro-filaments from the Captek surface. These micro extensions provide exceptional mechanical bond strength.

This system was developed because of Captek's pure, high noble metal composition —and has the advantage of not producing any oxides, a byproduct of the traditional PFM bond — which therefore requires a different method of bonding to porcelain. This Captek bonding process eliminates the conven-

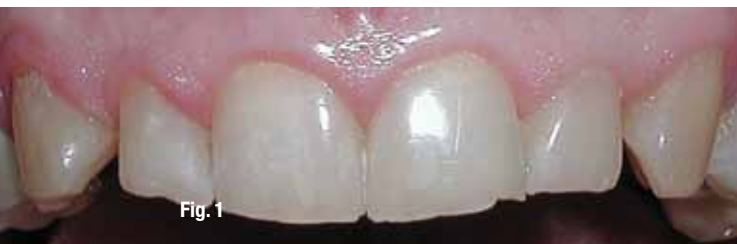

Fig. 1

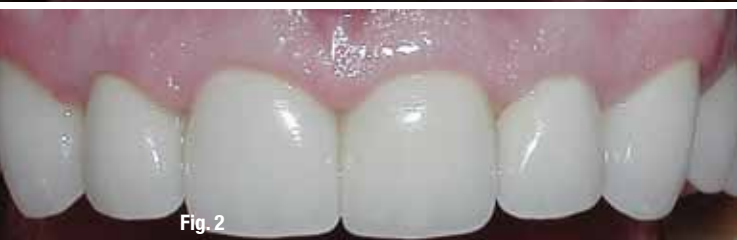

Fig. 2

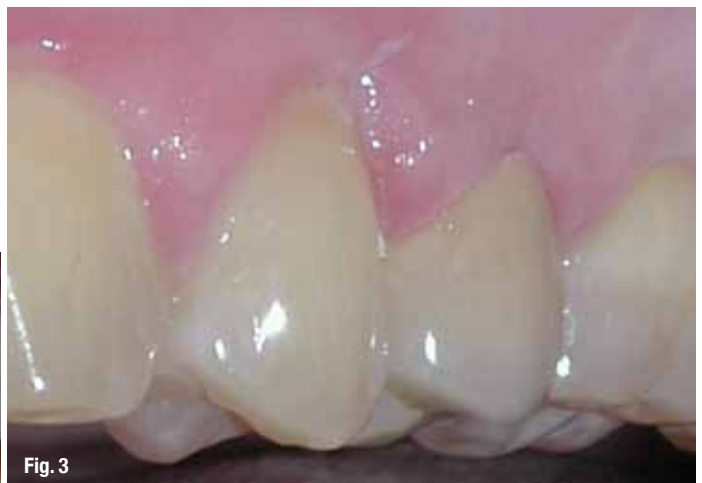

Fig. 3

tional grey oxide layer created during adhesion with other PFMs and surpasses it in its bond strength. This creates a tenacious bond between the Captek coping and porcelain (or composite resin).³ The elasticity of this micromechanical interlocking diminishes ceramometal stresses caused by coefficient of expansion differences that often account for porcelain cracking and chipping.

The UCP on Captek copings provides a color backdrop for the final restoration that is the closest to natural tooth structure and resembles the color of dentin nearest to the pulp. These hues of gold and yellowish-orange provide the most natural color background for the porcelain as dentin has an inherently yellow-gold color with a vital pulp producing a warm red background.

Therefore, the Captek coping provides the perfect base for any type of veneering — porcelain, acrylic or composite — giving it a warmer and more organic tone.

The UCP's light-scattering effect also contributes to the natural appearance of Captek crowns. Light reflecting from the coping through the porcelain is scattered by the extensions of the UCP layer, much like it is by natural tooth structure. Reflected light is fragmented and dispersed by natural tooth structure due to its enamel prisms and dentin tubuli just as it is by the UCP in Captek.

The Captek coping also exhibits an increased resistance to cyclic loading that derives from its unique three-layered structure (a lattice of gold that is strengthened with palladium and platinum), which provides a high degree of elasticity and resilience (Fig. 4).⁴ Masticatory forces and everyday parafunction produce vibration and shocks that can harm porcelain and its underlying supporting structure, whether implant or natural tooth.

Unprotected porcelain may chip and crack during function. Captek protects its porcelain by absorbing masticatory and parafunctional impacts that advance from the point of contact inward. When a restored implant or natural tooth is exposed to these continuous impacts and vibrations, their structure is weakened and the periodontium can be affected.

The inner and outer layers of Captek are each 25 microns thick, 97 percent gold and 3 percent silver. These layers are very forgiving and efficiently absorb the shocks and vibrations that can travel through the porcelain during routine function. This extraordinary shock-absorbing feature protects the layered porcelain, and it is particularly valuable for implant cases where no periodontal ligament cushioning exists.

What's more, Captek affords an important alternative for situations of limited space, such as at the lower incisors. With its one-of-a-kind configuration, the Captek coping can be thinner than conven-

tional metals, allowing the technician more latitude in porcelain design with conservative, minimal thickness restorations.

Even though the Captek coping is not cast, its extensively documented marginal integrity⁵ and antibacterial qualities⁶ make it an ideal restorative where subgingival margins are necessary, and I have found in many cases that these properties may afford the clinician more leeway in relation to the biologic width. The coping is made directly on the die model, providing an exceedingly precise fit.

In the Captek protocol, a metal embedded wax is applied in steps directly to a refractory die for the design and construction of the final metal coping, resulting in a highly precise marginal adaptation (Figs. 5–10). Other PFM technologies employ indirect methods that can introduce inaccuracies and distortions to marginal integrity.

Captek can also be burnished to further refine its marginal precision. The coping can be swedged before porcelain layering with different spacers to accomplish just the desired proximity to the tooth and spacing for cement thickness. Any crown and bridge cement can be used with Captek except those that must be light cured for best results. Captek maintains its accuracy through porcelain firing thanks to its internal reinforcing skeleton that resists warpage.

Research studies have found a marginal precision after cementation of 14.5–18 microns in single crowns and bridgework.⁷ Either chamfer or shoulder and bevel designs can be used with margins in metal or porcelain. When considering the use of this material, be certain to use a Captek-certified laboratory in order to realize its full benefits.

These unique properties are the result of years of extensive research that started in 1972 by two Israelis, Itzhak Shoher, DMD, MS and Aharon Whiteman, MDT. Together they have developed several different dental materials, such as RPS (reinforced porcelain system/Inzoma) and the Renaissance system, which have proven to be extremely biocompatible with outstanding esthetics in everyday dental practice.

In the years between 1993 and 1996, their research into gold, palladium and platinum metallurgy yielded Captek, when this material was introduced to the international dental community.

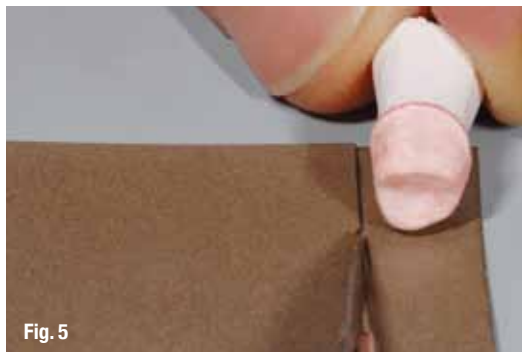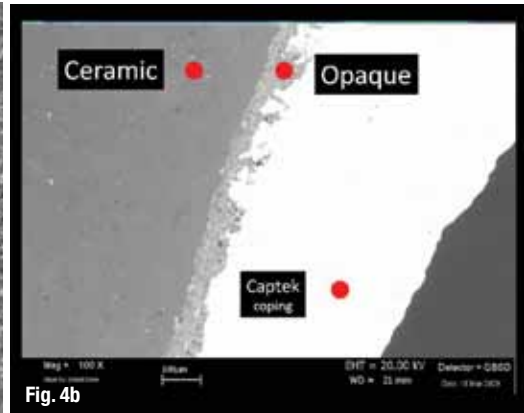

In addition, during the following years, Shoher and Whiteman cultivated multiple improvements to the product, the most significant being Captek Nano, which was introduced in 2007. This version allows for the fabrication of longer span bridgework and adds implant-supported restorations to this material's broad repertoire.

The elemental ratios have been altered in this process to reflect a composite metal content of 84 percent gold with the higher concentrations of 5.3 percent platinum and 7.2 percent palladium for even

Figs. 4a, b A scanning electron micrograph shows the Universal Porcelain Coupler (UCP) interface. (Photos 4–10/Provided by Captek)

Fig. 5 The first layer of metal-embedded wax is put in place on the refractory die.

Fig. 6 This layer is adapted intimately to the die surface.



greater strength. This permits the varying coping thicknesses of 0.28 mm for lengthier span bridge fabrication, 0.23 mm for routine restorations and even less than 0.2 mm for areas in the esthetic zone where maximal clearance for porcelain application may be needed.

Captek copings for bridgework utilize a specialized soldering method that precludes the possibility of any casting distortion for a completely passive fit. At this time, close to 10 million Captek units have been placed in the United States alone.

Uses

It is often the case that the location of previous restorations, cemental exposure or new carious lesions will mandate the placement of subgingival margins. It has also been my experience that because cariogenic oral bacteria are predominantly aerobic, and therefore do not have a significant presence in the subgingival environment, subgingival margin placement results in less recurrent decay.

Due to the moisture inherent in situations such as these, a cementable restoration is essential, and of the new generation in metal-free products, only zirconia will fill that bill.

However, zirconia is among the least esthetic of the ceramics whereas Captek achieves clearly superior esthetic results intrinsically and, in clinical testing, is proven to encourage the most natural soft-tissue esthetics as well.⁸ This quality

is explained by the influence of the Captek coping's warm metal color and its aforementioned bacteriostatic properties, which contribute greatly to gingival health where other materials, even including semi-precious metal copings, can be problematic (Figs. 11, 12).

Bacteriostasis occurs due to significantly lower bacterial adhesion to Captek as compared with other crown and bridge materials or even natural tooth structure, and significantly reduces harmful bacteria in the gingival sulcus over time.⁶ Because Captek is composed completely of precious metals, it will not react in the oral environment to cause oxide formations.

This lack of oxides is a major advantage for all the Captek copings surrounding structures from the gingivae to porcelain. Oxides from a standard crown's margins can infiltrate the adjacent gingivae, causing discoloration, and in some instances, even an inflammatory reaction. The Captek coping will not induce inflammation in the proximate gingiva, connective tissue or alveolar bone in any way.

Oxide formation on standard crown margins can make these surfaces rough, causing greater plaque accumulations that can eventually lead to gingivitis and may, in severe cases, advance to periodontitis. Captek's oxide-free surface prevents the occurrence of such reactions.

In conventional crown systems, metals oxidize during porcelain firing, causing an overall grayish look at the margins. Over time in the oral environ-



Fig. 7




Fig. 8



Fig. 9



Fig. 10

Fig. 7_ The first layering adaptation is completed and is ready for the second.

Fig. 8_ The second layer of metal-embedded wax is put in place on the refractory die.

Fig. 9_ The second layering adaptation is completed and ready for firing.

Fig. 10_ The fired coping is now ready for finishing and porcelain application.

ment, these standard metals continue to oxidize, further discoloring the marginal porcelain through dispersion of the oxide molecules. Captek metals will not oxidize in the oral cavity under any circumstances, thus preserving the original color of the restoration.

Captek's composite metal structure also produces a micro-electrical bipolar stimulus that seems to progressively invigorate the tissue cells around it.⁹ So gingivae are not only unaffected by Captek, but the product actually has a positive effect on these tissues.

Thus, there is comparatively less gingivitis and recession around a Captek crown than found around other ceramometal restorations. Consequently, Captek has become my material of choice for indirect restorations in the esthetic zone that demand subgingival margins.

As any dentist knows, endodontically treated teeth often discolor significantly after such procedures. It is also true that there are some implant cases where it is preferable to use a metal abutment, and in these instances the effect on gingival color can be decidedly negative.¹⁰ The translucency of most metal-free restoratives will not allow for the full masking of this tooth discoloration or metal reflection, and cosmetic outcomes will be adversely affected when those materials are used under these circumstances.¹¹

As a PFM restoration, Captek affords ultimate masking qualities, and its excellent esthetic results

make it the prime choice in situations where masking abutment discoloration is of prime importance.

The longevity of large restorative cases is of major consequence to the treating dentist. Remakes due to functional failure are costly to the dentist not only economically, but in terms of his or her reputation as well. The greater strength of PFM restorations over their metal-free counterparts, even including zirconia units, is well documented in the literature.¹² In cases where occlusal or parafunctional matters are of a principal concern, ceramometal crowns will be the longest lasting.

Considering Captek's advanced cosmetic capabilities and strength characteristics, there is no disadvantage to going with PFM restorations in a smile design case that has wear issues, which could lead to potential failures if all-ceramics are used. It is on this last point that I am met with the most skepticism from colleagues during my lectures around the country. There are many practitioners who simply will not believe that a PFM restoration can match the vitality of an all-ceramic product.

I have found in my practical experience that all other things being equal (skill of the laboratory technician involved, quality of the clinical records provided, etc.), it is easier to fabricate a really lifelike restoration from a metal-free material, but in the hands of a master ceramist, Captek restorations can achieve an organic realism that is virtually indistinguishable from nature (Figs. 13, 14).

In fact, complex restorative cases blending Captek

Fig. 11_The gingivae at these premolars restored with porcelain-fused-to-semi-precious-metal copings are severely inflamed and have receded substantially after only 14 months.

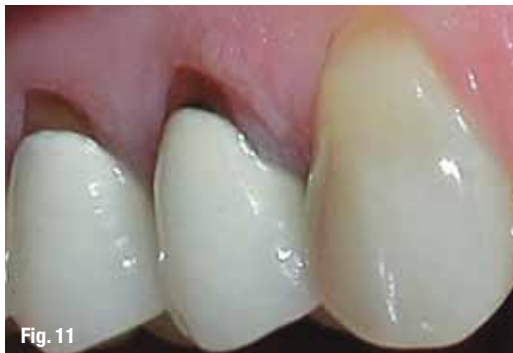

Fig. 11

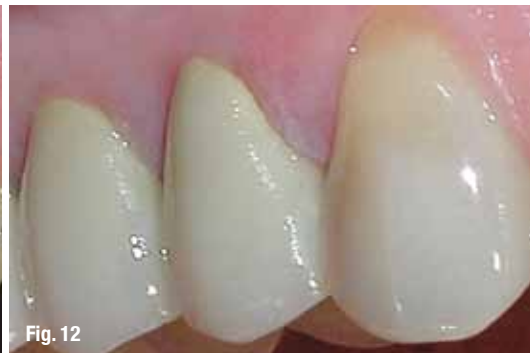

Fig. 12

Fig. 12_The same teeth 18 months after having been re-restored with Captek crowns show no sign of gingival irritation whatsoever.

Fig. 13_The composite facings on these central incisors are esthetically unacceptable.

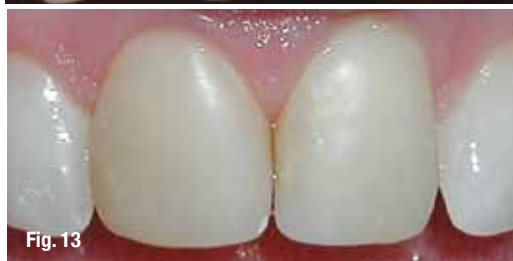

Fig. 13



Fig. 14

Fig. 14_The vitality of these Captek crowns is a rival for any metal-free units, and even their adjacent natural teeth.

Fig. 15_Clinical cross section of the Captek coping.




Fig. 15

and all-ceramic units have been documented to realize a harmonious result.¹³

Conclusion

Although all-ceramic restorations have been en vogue when it comes to transformational restorative cases in the esthetic zone for some time – even being taught as-state-of-the-art in dental schools¹⁴ – they are not the be-all or end-all when it comes to solving many common clinical situations.

The placement of all-ceramic restorations is much more technique sensitive than its ceramometal counterpart, and their long-term function, especially when all occlusal considerations have not been carefully accounted for, is questionable at best in comparison.¹⁵

There is a porcelain-fused-to-metal alternative that is stronger than the all-ceramic choices available, kinder to gingival tissues, more esthetic when seen through those tissues and every bit as natural looking when fabricated by a talented ceramist.

These attributes come from the design of Captek's unique composite metal coping (Fig. 15),¹⁶ whose properties set it apart from all other PFMs in the 10 years that I have been using it.

If there are cases for which you hesitate to use a metal-free restorative due to occlusal questions or where periodontal, abutment color or gingival factors are paramount, consider Captek. It will perform flawlessly under all these conditions while delivering cosmetic results that are unsurpassed by any other material when in the hands of a gifted laboratory technician. What more could you ask for?

The author would like to thank the Elite porcelain team at Arrowhead Dental Laboratory for their expertise in fabricating the Captek restorations shown in this article.

A complete list of references is available from the publisher upon request.

about the author

cosmetic dentistry

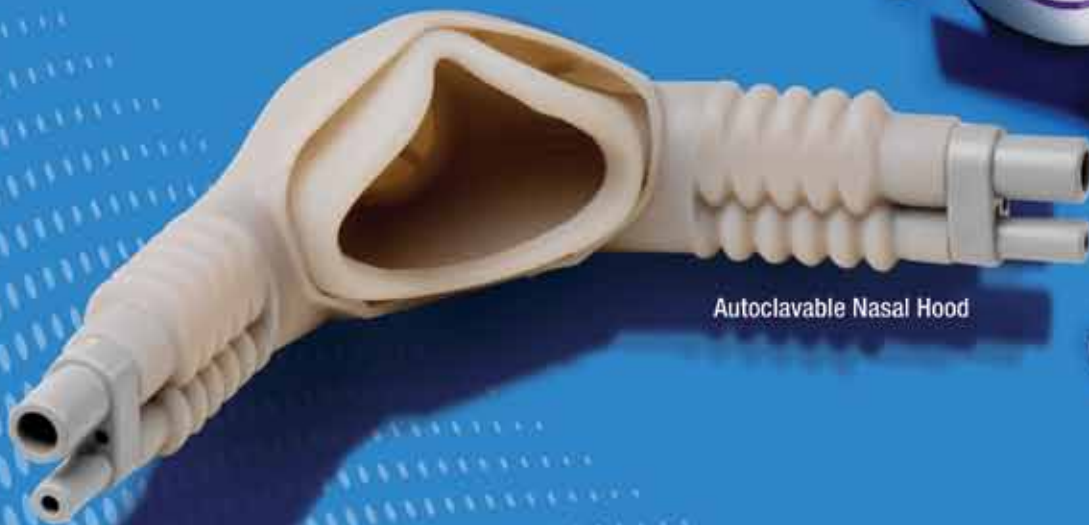

Dr. Barry F. McArdle graduated from Tufts in 1985 and maintains a private practice in Portsmouth, N.H. An expert reviewer for JADA, he has authored numerous articles in the peer-reviewed literature. McArdle is an alumnus of The Pankey Institute.

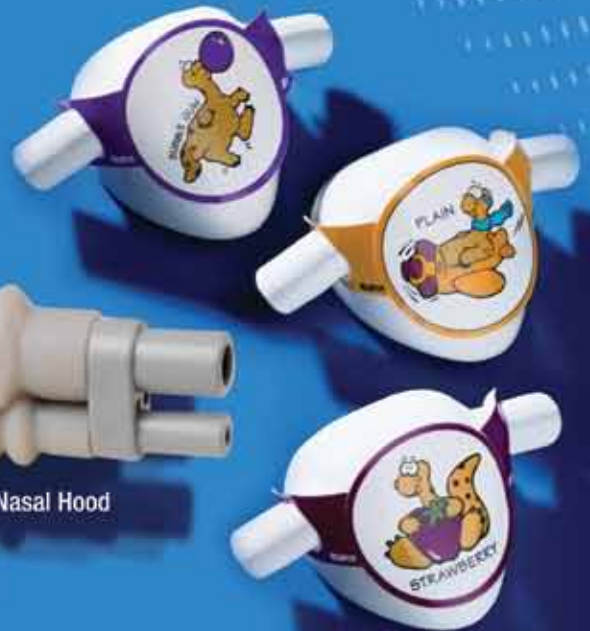He co-founded the Seacoast Esthetic Dentistry Association in 2000 and his lecture series, Seacoast Dental Seminars, in 2005. You may contact him at drmcardle@seacoastdentalseminars.com.

YOUR PATIENT. YOUR CHOICE. PORTER IS THE GOLD STANDARD.

The best of both worlds from one company.



Autoclavable Nasal Hood



Single-Use Nasal Hood

Porter Autoclavable & Single-Use Disposable Nasal Hoods for Nitrous Oxide Sedation

Porter Double Mask Nasal Hood

Safe Clinically proven to be the most efficient scavenging system*

Soft Comfortable, complete seal around the patient's nose

Savings Cost-effective, an investment for your practice

Autoclavable Hygienic and easy-to-clean

Eco-friendly Reduce, reuse, recycle

* clinical data available upon request

Matrix DynoMite Single-Use Nasal Hoods

Soft More comfortable fit which results in a better seal than other disposable brands

Small Reduced size means easier access to the patient's mouth

Savings Proven less expensive than other disposable nasal hood brands

Scented Appealing scents with happy dinosaur sticker, fun for children

Compatibility Easily adaptable to most breathing circuits

**VISIT OUR BOOTH
FOR FREE SAMPLES!**

If you aren't able to come see us at the show, just call 888-723-4001 or visit us at www.porterinstrument.com/dental.php and click "Ask An Expert" to request more information.

AGD Booth #1019

Fall CDA Booth #1725

ADA Booth #2925

GNYDM Booth #1017

PORTER



Two-stage esthetic crown lengthening

Author_Michael Sonick, DMD, Stephen Rothenberg, DMD, and Debby Hwang, DMD

_A smile that is perceived as unattractive mars confidence, sociability and self-regard. For some patients, the lack of visual appeal stems in large part from a gummy smile, which a layperson begins to consider disharmonious when there is 3 to 4 mm of gingiva displayed.¹ Management of such a complaint often entails both periodontal and restorative therapy, if not also orthognathic surgery and facial plastic procedures.

The following report showcases two-stage esthetic crown lengthening and prosthetic rehabilitation for the treatment of a gummy smile.

_Treatment plan

- Consult with oral and maxillofacial surgeon regarding orthognathic surgery
- Consult with facial plastic surgeon regarding lip lowering therapy
- Consult with restorative dentist regarding ideal tooth shape setup and fabrication of surgical guide
- Two-stage esthetic crown lengthening from tooth #4 to #13
- **First stage:** osseous recontouring
- Six-week healing period
- **Second stage:** gingivectomy
- Three-month healing period
- Final porcelain veneer restorations for teeth #4 through #13
- Delivery of maxillary occlusal bite guard

_Treatment plan rationale

Ideal treatment for the patient with vertical maxillary excess embraces a host of dental and medical specialties. In such a case as this, in which the patient demonstrates up to 7 mm of gingival display, LeFort I maxillary impaction may further refine results if conventional crown lengthening insufficiently elevates the periodontal margin, creates an unacceptable crown-to-root ratio

_Patient history

A medically and periodontally stable 40-year-old female presented with excessive, asymmetric gingival display of 5 to 7 mm upon smiling, short clinical crowns and incisal wear from tooth #4 to #13 (Figs. 1, 2). Due to attrition and the relationship between the dentition and periodontal drape, the anterior teeth appear square-shaped and "masculine."

Diagnoses included: (1) Coslet Type IA altered passive eruption, evidenced by a wider-than-customary dimension of keratinized gingiva and an alveolar crest at least 1.5 apical to the cemento-enamel junction (CEJ); and (2) vertical maxillary excess.^{2,3} The patient also shows a thick tissue biotype.

Fig. 1a_Initial facial presentation of patient who exhibits a gummy smile (up to 7 mm of soft-tissue display) and vertical maxillary excess. (Photos/Provided by Dr. Michael Sonick, et al.)

Fig. 1b_Initial view of maxillary anterior teeth upon smiling. The clinical crowns appear short and demonstrate attrition.

Fig. 2_Excessive keratinized gingiva, a thick soft-tissue biotype and asymmetric gingival contours exist.



Fig. 1a

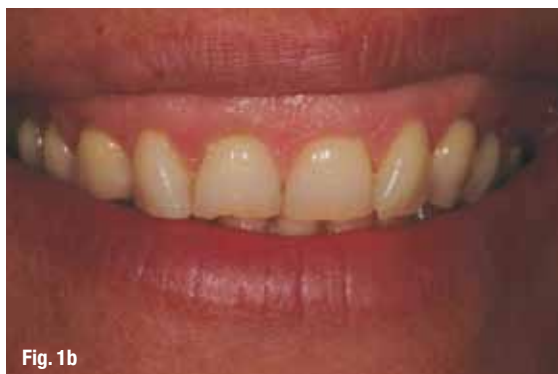

Fig. 1b

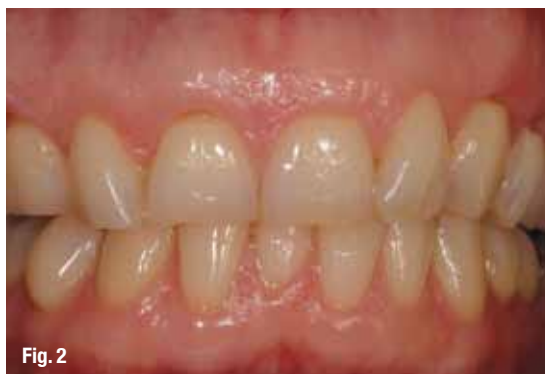
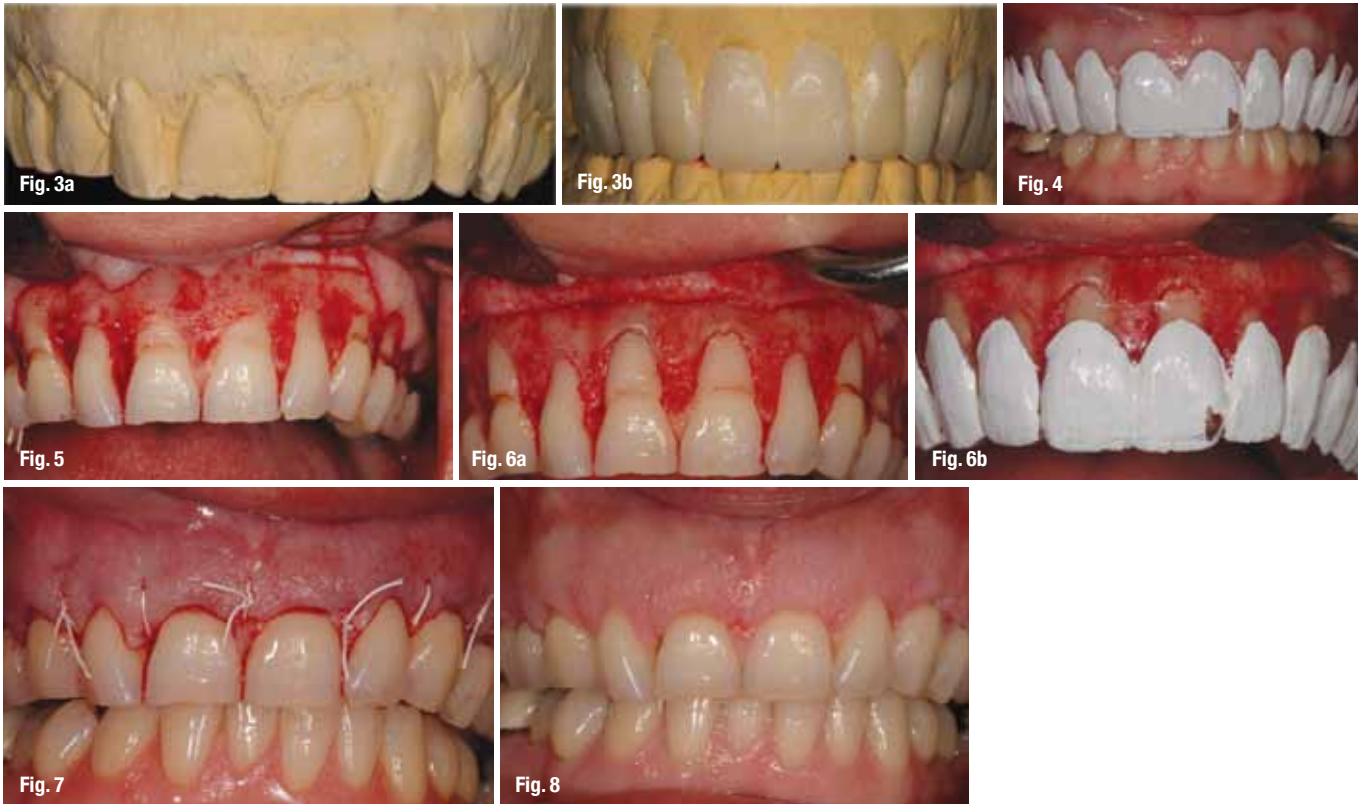
Fig. 2



or precludes achievement of a natural-seeming emergence profile due to exposure of excessive radicular structure.³

Likewise, neuromuscular relaxation of the upper lip by botulinum toxin type A (BTX-A) depresses the lip, and thus masks any mucosal surplus left after periodontal surgery.⁴

As the patient declined orthognathic and facial plastic therapy, the treatment rendered to alleviate her gummy smile and re-establish tissue and dental symmetry included a two-stage crown lengthening procedure followed by delivery of porcelain veneers from tooth #4 to #13.

A biphasic crown lengthening approach minimizes the 1 to 3 mm coronal gingival shifts common after one-stage procedures detected especially in patients with thick soft-tissue biotypes (such as the patient featured in this report).⁵

By first reshaping only the osseous crest and letting healing commence, it is possible to correct any coronal rebound of the soft tissue seen after healing at the second, gingivectomy-only, surgery.

Once the attachment apparatus fully remodels post-gingivectomy, which takes roughly three months, final restorations may be cemented.

Restorative consult

From the diagnostic models, the patient's prosthodontist created an ideal dental wax-up, upon

which a vacuform matrix was applied to generate a surgical guide (Figs. 3, 4).

Osseous recontouring (first stage)

The first stage of biphasic crown lengthening of teeth #4 through #13 involved only osseous resection. The patient took 0.25 mg oral triazolam and 600 mg ibuprofen one hour before surgery. Anesthesia with 2 percent lidocaine with 1:100,000 epinephrine and 0.5 percent bupivacaine with 1:200,000 epinephrine was given via local infiltration.

A buccal sulcular incision was made extending from tooth #4 to #13, and vertical incisions were dropped at the mesio-buccal and disto-buccal line angles of teeth #4 and #13. A full-thickness flap was elevated (Fig. 5).

Osteotomy was performed using an Ochsenbein chisel, carbide finishing bur and Neumeier bur to position the alveolar crest at least 3 mm from the anticipated restorative margin at each site, as verified by the surgical guide (Fig. 6).

The bone was gradualized such that no sharp edges or bulbous areas existed, and positive architecture was preserved.

The flaps were replaced and sutured in sling fashion with 4-0 expanded polytetrafluoroethylene (ePTFE) (Fig. 7). The gingival height and shape post-surgery appeared similar to that found before surgery, even 10 days after intervention (Fig. 8).

Fig. 3a The maxillary diagnostic model.

Fig. 3b Ideal wax-up created on the diagnostic model.

Fig. 4 Surgical guide in place in the mouth. The ideal tooth contours are shaded in white.

Fig. 5 Initial full-thickness flap reflection at first stage surgery. Note the apical level of the alveolar crest compared to the cemento-enamel junction.

Fig. 6a Final bone contours after osteotomy.

Fig. 6b The final osseous contour lies at least 3 mm from the anticipated restorative margins, as outlined by the surgical guide.

Fig. 7 Sling sutures in place after osseous reshaping. Note the similarity in gingival height and morphology between pre-surgical and post-surgical views.

Fig. 8 Healing 10 days after first stage crown lengthening. The periodontal level still approximates the initial presentation.

Fig. 9 Healing six weeks after first stage of crown lengthening.

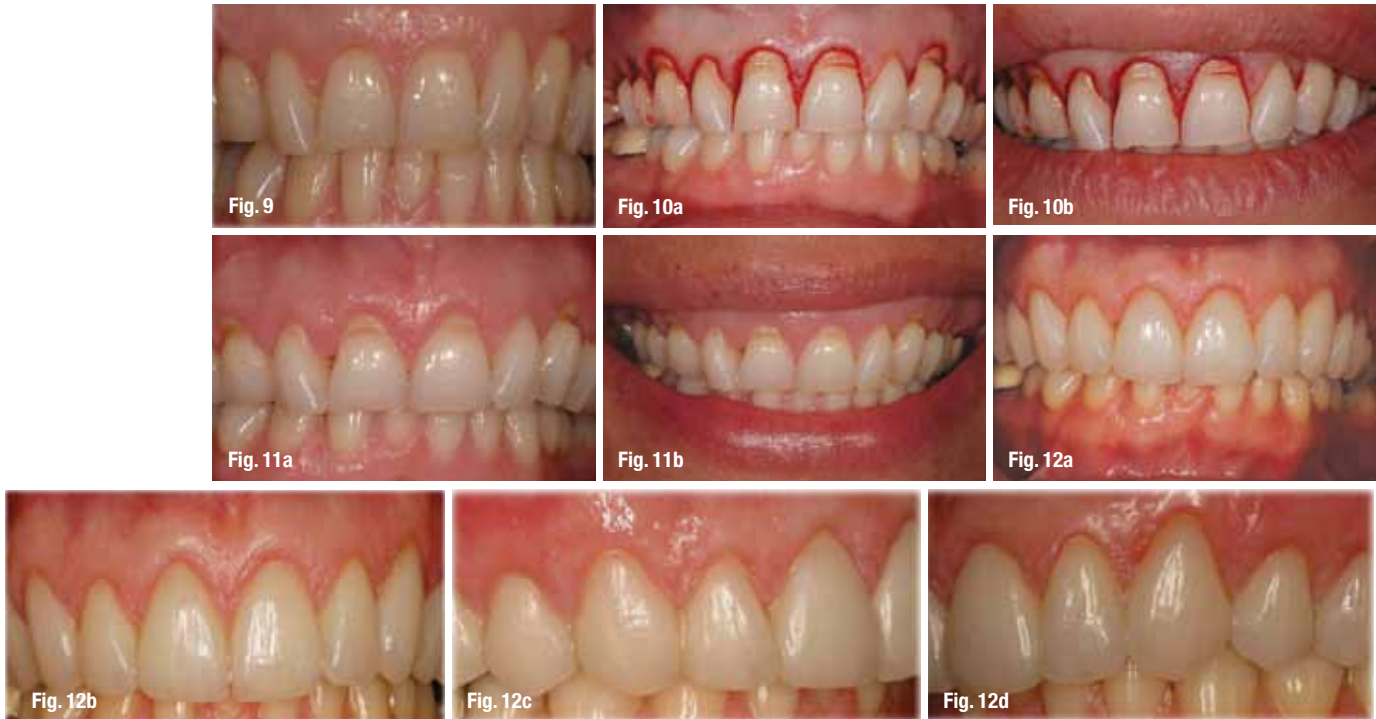

Fig. 10a_Frontal view immediately after second stage gingivectomy.

Fig. 10b_Positional relationship between the lip and gingival margin immediately after second stage gingivectomy.

Fig. 11a_Frontal view four weeks after second stage gingivectomy.

Fig. 11b_Positional relationship between the lip and gingival margin four weeks after second stage gingivectomy.

Fig. 12a_Frontal view of final veneers (#4 through #13) three months after gingivectomy.

Fig. 12b_Central view of final veneers (#6 through #11) three months after gingivectomy.

Fig. 12c_Right lateral view of final veneers (#4 through #8) three months after gingivectomy.

Fig. 12d_Left lateral view of final veneers (#9 through #13) three months after gingivectomy.

Gingivectomy (second stage)

Once the soft tissue resettled six weeks post-osteotomy (Fig. 9), the second stage of biphasic crown lengthening of teeth #4 through #13 was executed. The patient was sedated and anesthetized as above.

A definitive external bevel gingivectomy of teeth #4 through #13 was performed with a #15 scalpel utilizing the surgical template to delineate the desired tooth contours (Fig. 10). The papillae were left intact and no sutures were required. Healing four weeks after the gingivectomy revealed a harmonious gingival drape (Fig. 11).

Final prosthetics

Placement of final veneers on teeth #4 through #13 occurred three months post-gingivectomy (Fig. 12). An occlusal bite guard was delivered to protect the restorations. In order to correct lip line asymmetry and further diminish gingival display, neuromuscular lip correction (lowering) with BTX-A was reconsidered, but the patient did not pursue treatment.

Six years after veneer placement, the patient remained satisfied with the functional and esthetic result achieved solely through periodontal surgery and prosthetic rehabilitation (Figs. 13, 14).

Postoperative instructions

After each surgical procedure, the patient was

instructed to take 600 mg of ibuprofen every four to six hours, hydrocodone 7.5 mg/acetaminophen 750 mg every four to six hours as needed for pain and 100 mg of doxycycline a day for 10 days.

The patient was instructed not to brush at or near the surgical site but instead to rinse with 0.12 percent chlorhexidine or warm saline twice daily. The patient was also directed not to chew in the affected area for at least two weeks. Suture removal occurred at 10 to 14 days post-surgery.

References

1. Kokich VO, Kokich VG, Kiyak HA. Perceptions of dental professionals and laypersons to altered dental esthetics: asymmetric and symmetric situations. *Am J Orthod Dentofacial Orthop* 2006;130(2):141-51.
2. Coslet JG, Vanarsdall R, Weisgold A. Diagnosis and classification of delayed passive eruption of the dentogingival junction in the adult. *Alpha Omegan* 1977;70(3):24-8.
3. Garber DA, Salama MA. The aesthetic smile: diagnosis and treatment. *Periodontol* 2000 1996;11:18-28.
4. Polo M. Botulinum toxin type A (Botox) for the neuromuscular correction of excessive gingival display on smiling (gummy smile). *Am J Orthod Dentofacial Orthop* 2008;133(2):195-203.
5. Sonick M. Esthetic crown lengthening for maxillary anterior teeth. *Compend Contin Educ Dent* 1997;18(8):807-12, 14-6, 18-9; quiz 20.

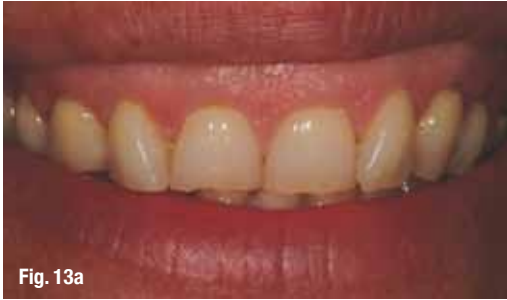

Fig. 13a

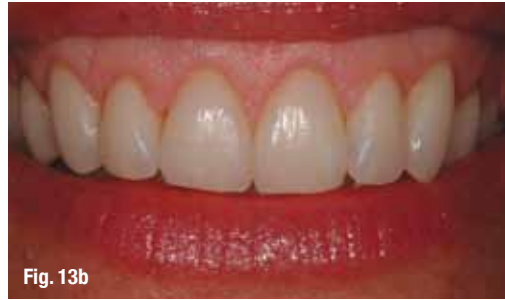

Fig. 13b

Fig. 13a_Smile pre-treatment.

Fig. 13b_Smile six years post-treatment.

Fig. 14_Facial view six years post-treatment.



Fig. 14


_about the author

cosmetic
dentistry



Periodontal surgeon: Michael Sonick, DMD
Restorative dentist: Stephen Rothenberg, DMD

Dr. Michael Sonick is a full-time practicing periodontist and implant surgeon in Fairfield, Conn. He is on the editorial boards of many journals and is co-editor of the textbook "Implant Site Development." He is currently a guest lecturer at New York University School of Dentistry and is director of Sonick Seminars, in Fairfield, Conn. You may contact Dr. Sonick at mike@drsonickdmd.com.



Learn DR. BERLAND'S BIOMIMETIC APPROACH
and improve your patient care & dental practice

SAVE your patient's TEETH, TIME & MONEY


Order the Same-Day Inlay/Onlay CD today!

\$44.00
all-inclusive


Earn 8 C.E. credits

Call 214.999.0110

BEFORE



AFTER



LEARN MORE at berlanddentalarts.com/dentalprofessionals

Dr. Lorin Berland has been internationally recognized for his expertise in cosmetic dentistry. He is a recipient of the AACD Award for Outstanding Contributions to Cosmetic Dentistry. Dr. Berland founded Berland Dental Arts, a multi-specialty group practice in Dallas, Texas.

AD

Practical education for the **implant dentist**

Obtain practical continuing education (C.E.) you can use immediately in your implant practice at the American Academy of Implant Dentistry's (AAID) Annual Meeting, Oct. 19–22 in Las Vegas. Learn from the pros who have the knowledge and experience about how to attract and keep new patients, improve your treatment planning and enhance your skills as an implant dentist. Join more than 1,000 of your colleagues and a world-class faculty at one of the best values in implant dentistry.

- Obtain practical implant dentistry C.E. with a choice of different programs
- Interact one-on-one with world-class presenters in roundtables and workshops
- Leave with clinically practical information you can use immediately
- Discover the latest products and services in implant dentistry
- Celebrate 60 years of innovation in implant dentistry



October temperatures in Las Vegas range in the low 80s during the day, so a visit to the pool at Caesars Palace is not entirely out of the question. (Photo/Robin Goodman, Dental Tribune America)

_Main podium programs

A world-class faculty, including Sascha A. Jovanovic, Carl E. Misch, Craig M. Misch, Paul Petrunaro, Michael A. Pikos and others, will headline the main podium programs at the AAID Annual Meeting. The main podium presentations will include:

- Finding the Right Patient: It Takes More than an Ad
- The First Visit for the Patient: Your Only Chance at the First Impression
- Case Planning to Prevent Implant Complications: Methods to Reduce Biomechanical Factors, Key Implant Positions, Implant Number and Implant Size
- Comprehensive Implant Dentistry Using 3-D Imaging: Reduce Complications, Increase Confidence, Achieve Excellence
- Treatment Planning – Implants Versus Root Canal Therapy: Read, Analyze and then Decide
- The Case Acceptance Appointment: What to Do Starting Next Week
- Extract and Graft, Implant Later
- Extract and Implant
- Implants for Immediate Function: Fact or Fiction
- Risk Assessment in the Esthetic Zone
- Soft-Tissue Esthetics and Health with Dental Implants: 10 Key Criteria for Success
- Regenerative and Esthetic Techniques in Implant Surgery: Clinical Applications with Recombinant Growth Factors
- Enhancing Outcomes with Block Bone Grafts
- Avoiding and Managing Esthetic Implant Complications

The meeting theme is "Realities of Implant Dentistry: Stacking the Deck in Your Favor." Register by Sept. 19 to save \$100 on the full registration fee for dentists. More information, including online registration, abstracts, learning objectives for the main podium programs, the schedule and speaker bios, are available on the AAID website at www.aaid.com.

You can even make your hotel reservations online at the special AAID hotel rate at the Caesars Palace or call (866) 227-5944. Mention the American Academy of Implant Dentistry's group code (SCAAI1) for special group rates. _



G-ænial™ Universal Flo

Your final flowable has ævolved.

Finally, no sacrifices.

- Indicated for for Class I, II, III, IV, and V restorations
- Nano-hybrid flowable with over 167 MPa flexural strength¹
- Wear resistance superior to all leading flowables and conventional composites tested¹
- No voids when placing
- Exceptional viscosity, highly thixotropic, and no residual paste flow for easy handling



Scan with your smartphone for more details or go to gcamerica.com.



GC America Inc.
3737 West 127th Street Alsip, IL 60803
800-303-7063 • www.gcamerica.com
www.gcamerica.com/training • © 2011 GC America Inc.

GC



DTSC Symposia at the Greater N.Y. Dental Meeting

Author Julia Wehkamp, DTSC C.E. Director

As you gear up for the 2011 Greater New York Dental Meeting (GNYDM), consider checking out programs you may have missed at last year's meeting, which was a great success, attracting more than 2,000 registrants.

As the official online education partner of the GNYDM, an event that draws many from the international dental community, Dental Tribune Study Club (DTSC) hosts a focused lecture program on the exhibition floor.

In case you were not able to attend last year's program, you may view all of the presentations online. Each lecture was recorded and archived at www.dtstudyclub.com as a C.E.-accredited webinar. Please visit www.dtstudyclub.com/courses/all where the following archives can be found:

- Dr. Howard Glazer: *BEAUTIFIL: Go with the FLOW*
- Dr. John Flucke: *Light-Cured Adhesive Dentistry: Science and Substance*
- Dr. Martin Goldstein: *A Simplified Approach to Multi-Layer Direct Composite Bonding*
- Dr. Richard Rosenblatt: *Digital Impressions: Are they for me?*
- Dr. Louis Malcmacher: *Total Facial Esthetics for Every Dental Practice*
- Dr. Dirk Gieselmann: *How a MMP-8 Testing Can Change A Dental Office and the General Health Economy*
- Noel Brandon-Kelsch: *Eco-Friendly Infection Control*
- Dr. Gregori Kurtzman: *Understanding Adhesives and How to Incorporate New Advances in Dental Materials and Techniques into Your Restorative Practice*
- Dr. Marc Gottlieb: *Exciting New Tools for Superb Impressions*
- Dr. Marc Gottlieb: *A Game-Changing Approach to Difficult Class II Composite*
- Dr. Marc Gottlieb: *The Newest Developments in*

the Art and Science of Air Abrasion

- Dr. Damien Mulvany: *Optimizing Your Practice with 3-D Cone-Beam Technology*
- Dr. Edward Katz: *Improving Patient Care with 3-D Cone-Beam Computerized Tomography*
- Dr. George Freedman, Dr. Fay Goldstep and Dr. Edward Lynch: *Soft-Tissue Lasers and Caries Diagnosis*
- Dr. Lou Chmura: *Soft-Tissue Lasers Adjunctive to Orthodontic Treatment*
- Dr. Dov Almog: *Introduction to CBCT, Especially As It Pertains to Prevention of Failures in Oral Implantology*
- Dr. Bettina Basrani: *Cleaning and Shaping with New Technology*
- Dr. Dwayne Karateew: *Contemporary Concepts in Tooth Replacement: Paradigm Shift*
- Al Dube: *Mercury Amalgam Waste and OSHA and Regulatory Issues Affecting Dentists*
- Dr. Glenn van As: *The Role of the Diode Laser in Restorative Cosmetic Dentistry*
- Dr. Jeffery Hoos, Dr. Dwayne Karateew, Dr. Enrique Merino and Dr. Ethan Pansick: *Osseo University Summit, Implant-Driven Dentistry*

Furthermore, the recorded lectures from the GNYDM's Live Dentistry Arena can also be found at www.dtstudyclub.com/gnydm-live.

For the fourth year in a row, dentists can enjoy the DTSC symposia at the GNYDM, which will include four days of focused lectures in various areas of dentistry.

Each day, from Nov. 27-30, will feature a variety of presentations on topics that will be led by experts in that field. Participants earn ADA CERP C.E. credits.

Additional details and registration for the 2011 DTSC Symposia at the GNYDM can be found at www.dtstudyclub.com/gnydm.



DENTAL TRIBUNE

DT STUDY CLUB

COURSES | DISCUSSIONS | REVIEWS | MENTORING

GrandioSO: the ultimate handling and performance composite

In general, if a material is not compatible with its substrate, the finished product is doomed to fail — and when this happens in dentistry, where the material is composite and the substrate is tooth structure — you end up with a dissatisfied patient along with a time-consuming, costly remake. VOCO's primary objective in the development of its new nano-hybrid universal restorative was to create a material that not only offers excellent esthetics and handling, but also mirrors the natural properties of the tooth: surface hardness, strength, elasticity, wear, stability and thermal behavior.

Grandio[®]SO, a substrate-optimized universal nano-hybrid composite, has a unique combination of superior handling, esthetics and ideal physical properties that make it the most toothlike composite ever developed.

_The importance of substrate optimization

Dynamic loads such as chewing forces and changes in temperature put constant stress on the restoration, and the only way to counterbalance these ongoing stresses is to use a composite that matches the elastic and thermal behavior of the tooth.

Because of its substrate optimization, GrandioSO behaves like tooth structure, promotes

a natural equilibrium at the restorative-substrate interface and is capable of withstanding years of dynamic chewing forces and millions of temperature changes.

_More filler = less shrinkage

Low shrinkage is a key component of every successful restoration. GrandioSO achieves its remarkably low shrinkage rate of 1.6 percent through its innovative nano technology. In composite materials, polymerization shrinkage occurs only in the resin matrix.

Therefore, the greater the percentage of filler in the composite, the more it reduces shrinkage. In conventional micro-hybrids, the filler particles are made by grinding large pieces of glass ceramic into small particles about 400 nm in size. At this size, the best most universal restoratives can achieve is in the range of 77 to 80 percent filler particles.

GrandioSO uses silicon dioxide nano filler particles grown from a liquid in a sol-gel process to achieve a much smaller particle size of 20 to 60 nm, and then mixes those nano particles with traditional glass-ceramic filler particles. The traditional fillers form a hard network and the nano particles fill the spaces between them, enabling GrandioSO to achieve its higher filler rate of 89 percent.

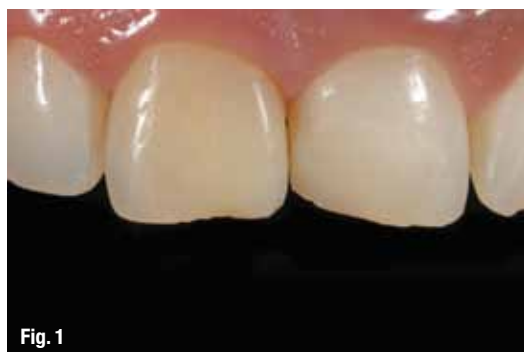

Fig. 1

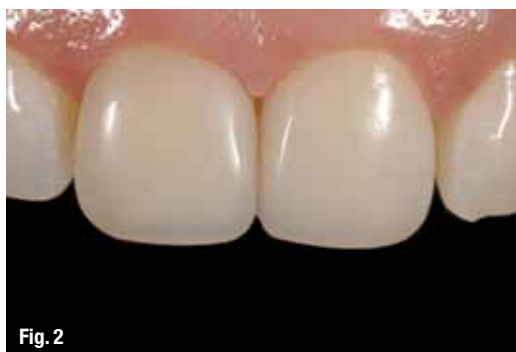

Fig. 2

Fig. 1 _Initial situation. (Photos/ Provided by VOCO)

Fig. 2 _Restored with GrandioSO A2, polished with Dimanto.




Fig. 3




Fig. 4

Fig. 3 Spherical nanoparticles with a defined grit size of 20 nm.

Fig. 4 Conventional fillers produced by milling. The milled down particles are in the form of splinters and vary greatly in size (up to 5 microns).

Fig. 5 GrandioSO

Long-term dimensional stability

GrandioSO exhibits exceptional long-term dimensional stability. When chewing force is applied, it compresses the restoration, a process called material "creep." Once the force is removed, the material begins to expand back to its original shape. However, it never goes back to its exact original volume. This minute difference, called "permanent set," describes the inelastic deformation of the material and is of particular importance for posterior restorations.

If the material can't stand up to the daily chewing load, deformation occurs over time, which can lead to failure of the restoration. Therefore, low creep and low permanent set are essential for long-term dimensional stability. GrandioSO delivers significantly lower creep and permanent set, which are two key physical properties that contribute toward its long-term clinical performance.

Hard surface, permanent high gloss

Surface hardness also plays an important role in restoration durability. GrandioSO exhibits a surface hardness twice as high as other composites, and comes closest to the hardness of natural tooth enamel. Yet, despite its exceptionally high surface hardness, GrandioSO still polishes well and produces long-lasting high-gloss restorations.

Thanks to its superb physical and esthetic properties, GrandioSO can be used for both anterior and posterior restorations.

GrandioSO comes in 16 shades, but in many cases, even in the anterior region, only one shade is required to produce the best esthetic result — saving the dentist time and money.



Fig. 5

GrandioSO VOCO added three special shades to the standard VITA range: VCA5 for the growing needs of geriatric patients, VCA3.25 to close the large shade gap between A3 and A3.5 and Bleach for pediatric and bleached patients.

Conclusion

When it comes to nano-hybrids, substrate optimization really does make a difference. GrandioSO provides a toothlike modulus of elasticity; thermal expansion and flexural strength; remarkably low shrinkage; exceptional strength and wear resistance, excellent handling and sculptability and prolonged working time under ambient light.

And to the patient's delight, the material polishes to a high gloss for a permanent smooth surface that maintains long-lasting esthetics. Putting these all together, GrandioSO might be the most toothlike composite currently on the market.



Tetric **EvoCeram**[®]

Direct Composite Technology has **Evo**lved!

New & Improved Tetric **EvoCeram**[®]

A unique chemistry offering the perfect balance of handling, esthetics and durability.

- Creamy, sculptable consistency for optimal handling
- Innovative refractive index technology for unsurpassed esthetics
- Clinically proven with over 90,000,000 restorations



Tetric **EvoCeram[®]**
NANO-OPTIMIZED COMPOSITE RESTORATIVE

100% CUSTOMER SATISFACTION
GUARANTEED!

ivoclarvivadent.com

Call us toll free at 1-800-533-6825 in the U.S., 1-800-263-8182 in Canada.
© 2011 Ivoclar Vivadent, Inc. Tetric EvoCeram is a registered trademark of Ivoclar Vivadent.

ivoclar
vivadent[®]
passion vision innovation

Nitrous oxide/oxygen sedation: multidisciplinary application resurgence

A brief Internet search would quickly reveal the multitude of health disciplines and their new, or sometimes renewed, interest in the use of nitrous oxide as an ideal sedative agent for dealing with fear and anxiety associated with an ever-expanding list of procedures. The main reason for this rebirth in popularity lies in the basic properties of the drug itself. Nitrous oxide has a rapid onset and is quickly reversible. The long history of dentistry's use of nitrous oxide is well documented and the safety record has been an enviable one.

A review of current findings includes interest in pediatric medicine and obstetrics. Pediatric emergency rooms have established nitrous oxide sedation protocols for procedures, including sutures, setting broken bones and placing IV lines.

Other countries have successfully used nitrous oxide and oxygen in obstetric clinics. These clinics have been equipped with "on-demand" machines that deliver a 50 percent blend of nitrous oxide and oxygen. Mothers in labor prepare for the next contraction by taking a few breaths of the mixture to help them through the contraction. This application is currently being evaluated at some prominent U.S. universities that specialize in childbirth education.

When administering nitrous oxide to patients, some very simple points should be remembered. First, nitrous oxide works best in those situations where its use is planned and discussed with the patient beforehand. To attempt to use nitrous oxide as a rescue agent after an unpleasant situation has developed will have little chance to be effective. Second, nitrous oxide is not a potent agent. It will have varying degrees of success; therefore, it should not be expected to work miracles in patient management.

Third, the patient should be instructed what sensations he or she will experience when adequately sedated. The goal of monitoring the patient's experience will help the practitioner assess the level of sedation achieved and prevent over sedation and a possible unfavorable reaction by the patient.

(Photos/Provided by Parker Instruments)

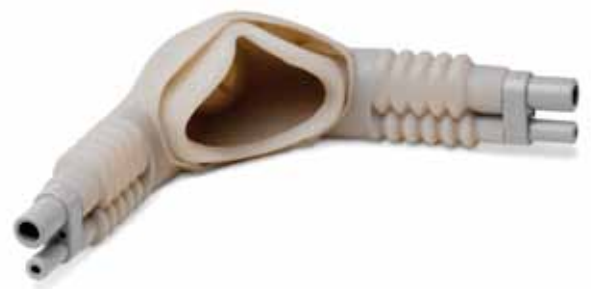

Fig. 1



Fig. 2



Fig. 3



Fig. 4

For dental use, nitrous oxide has some unique advantages. The onset time is very rapid and it is easily titrated by adjusting the administered concentration. Most clinicians advocate 100 percent oxygen administration for several minutes, followed by titration to the desired level of sedation. Titration is a very important practice in preventing over sedation of the patient and the possibility of a "roller coaster effect" caused by raising and lowering the nitrous oxide concentration, often resulting in nausea.

The proper flow rate (the minute ventilation volume [in liters] of the patient) is established by observing the movement of the breathing (reservoir) bag. It should not be flat (increase flow) or overextended (decrease flow). Postoperative oxygenation with 100 percent oxygen is also recommended for several minutes to assist with both patient recovery as well as removal of nitrous oxide from the patient's system. Generally, due to fast recovery from nitrous oxide sedation, patients can leave the office unassisted and an adult escort is not needed.

The machines that control and administer the gases through a breathing circuit are called flowmeters and provide practitioners with a tremendous variety of options and safety features. All flowmeters should include a failsafe to prevent the flow of nitrous oxide without the flow of oxygen. Gas flow and mixture can be precisely measured and adjusted.

Typically, the flowmeter will have a maximum nitrous concentration capability of 70 percent nitrous oxide. Some flowmeters can be capped at a 50 percent maximum concentration.

Flowmeters are typically designed with a narrow upright shape to enable clear visibility of the flow tubes and easy access to the control valves. These devices are available in either analog or digital models. Porter Instrument manufactures a flowmeter that combines both analog and digital technology. Control options vary from needle valves to knobs to push-button operation.

Various mounting options include wall arms and mobile carts (which have E-size cylinders of the gases), allowing for a portable system. Cabinet-mounted flowmeters generally use gases that are

supplied from a central tank room (with larger size gas cylinders) located in the facility. The savings in the cost of the gas (generally five times less per procedure) as compared to portable E-size cylinders and the convenience of delivery make this method of installation an ergonomic and cost-effective preference.

Probably the most important consideration should be given to the breathing circuit. The fit of the mask is an important element to the predictable analgesic outcome. A mask that doesn't seal properly around the nose will allow ambient air to be drawn in and dilute the gas mixture that comes from the breathing bag. This may result in the patient reporting he or she "doesn't feel the gas."

Improper fitting masks may also allow gas to escape, exposing the dentist and staff to unsafe levels of nitrous oxide. Breathing circuits come with masks that are autoclavable or single-use disposable. Scented and plain options are available as well. All breathing circuits should be supplied with a vacuum control gauge that indicates the proper level of vacuum is being achieved.

The use of nitrous oxide is no longer just a standard practice in the United States but virtually every continent has "clinical champions" who provide lectures, seminars and hands-on training in the proper use of nitrous oxide sedation. Internationally, what had started as a pediatric initiative with the European Academy of Pediatric Dentistry (EAPD) and the International Academy of Pediatric Dentistry (IAPD) has gained acceptance in general dentistry in the Middle East, India, China and the Pacific Rim countries. The popular "Handbook of Nitrous Oxide and Oxygen Sedation," written by Clark and Brunick, has been translated into several different languages.

Nitrous oxide is the oldest and only inorganic anesthetic agent still in clinical use today. It appears to have reached a tipping point both globally and across all medical and dental disciplines. When administered appropriately by trained health-care providers, nitrous oxide is a valuable asset in decreasing the pain and anxiety experienced by patients during certain dental and medical procedures.

_contact	cosmetic <small>dentistry</small>
<p>Mike Lynam Porter Instrument (215) 723-4000 www.porterinstrument.com dental@parker.com</p>	

Pola celebrates 10 years

Southern Dental Industry's (SDI) Pola tooth whitening system is celebrating 10 years of tooth whitening success. Since being launched at the International Dental Show (IDS) 2001 exhibition, Pola tooth whitening systems have whitened millions of smiles all over the world. SDI's formula for success has focused on minimizing sensitivity and maximizing whitening effectiveness for patients and dentists alike. The Pola tooth whitening system is composed of both in-office and take-home options.

Pola Office+ is an auto-mixing, extremely fast in-office bleach that whitens teeth in under half an hour. The easy-to-use and unique delivery system allows dentists to complete the procedure using a minimum amount of time. *Pola Office+* can be used with or without a bleaching light as it does not require light activation. *Pola Office+* contains the unique built-in desensitising agent potassium nitrate, which inhibits postoperative sensitivity. The neutral PH of *Pola Office+* ensures maximum comfort during and after treatment, and the short treatment time results in less patient discomfort and lower sensitivity.

Pola Day and Night are take-home tooth whitening systems prescribed only by dental professionals to be used by patients in custom-made tooth whitening trays. *Pola Day* is hydrogen peroxide-based and *Pola Night* is carbamide-peroxide based. Both systems are available in three concentrations to allow a tailor-made whitening program addressing all patient needs.

All Pola take-home tooth whitening products are in a high viscosity neutral PH gel, contain a unique blend of soothers and conditioners and have a high water content ensuring the greatest possible patient comfort and reduced sensitivity in a take-home kit.

Pola Paint is a paint-on tooth whitening system designed to be used as touch-up procedure to maintain a previously whitened smile. There is no need for trays to be made. Patients simply purchase a kit from you and do the work themselves. *Pola Paint* is an excellent marketing tool for your tooth whitening business.

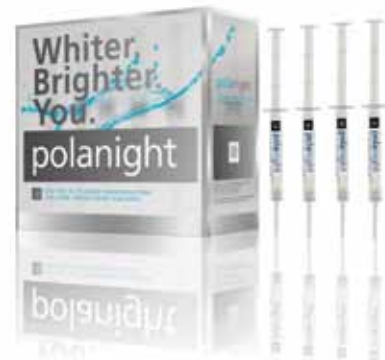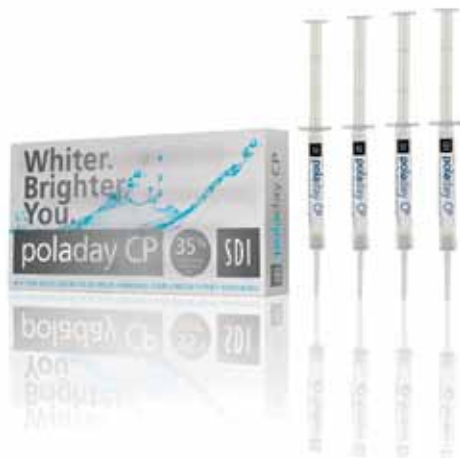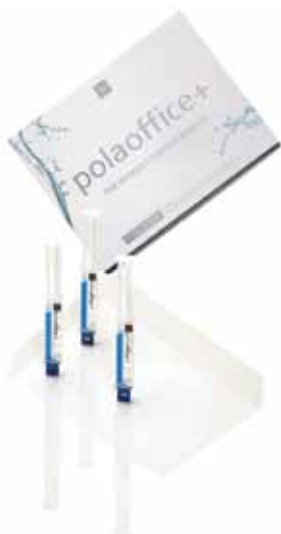The well-established line up of Pola tooth whitening products has recently been complemented with "Pola Day CP," which is a 35 percent carbamide peroxide version of *Pola Day* and offers an extremely fast 15 minute take-home whitening time. This is perfect for people who want to bleach their teeth at home and can never find the time to do it.

SDI understands the need for dental professionals to set themselves apart and thus offers dental professionals a wide range of complimentary marketing support, including posters, patient brochures, statement stuffers and window decals. Beyond the standard materials, SDI also provides custom marketing materials through its in-house graphics department.

The "Whiter.Brighter.You.for life" patient loyalty program has helped hundreds of dental professionals increase their patient base and reduce last-minute cancellations and no-show appointments. This is a unique and inexpensive program that can be easily and quickly implemented into your dental office.

To learn more about the Pola tooth whitening system, contact your local authorized dental dealer representative or schedule a visit from your SDI representative.

For additional information, please contact SDI at (800) 228-5166 or visit www.sdi.com.au/en/tooth-whitening.



(Photos/Provided by SDI)

poladay+night

take home advanced tooth whitening systems



NEW
Packaging
available
soon!

Pola Day CP

- Great results in only 15 minutes a day!
- 35% carbamide peroxide

Pola Day

- From 30 minutes once a day
- Available in 3%, 7.5% and 9.5% hydrogen peroxide

Pola Night

- From 45 minutes once a day
- Available in 10%, 16% and 22% carbamide peroxide

Whiter. Brighter. You.



SDI (North America), Inc.
729 N. Route 83, Suite 315
Bensenville, IL 60106, USA
Toll free: 1800 228 5166
Fax: 630 238 9200
usa.canada@sdi.com.au
www.sdi.com.au

Visit: www.sdi.com.au/en/marketing-materials/
to view our full range of **FREE**
marketing materials available



NEW YORK RIO DE JANEIRO MILAN BERLIN DUBAI PARIS ROME LONDON SYDNEY HONG KONG

Universal self-etch bonding agent

Oxford Scientific Dental Products introduces Oxford Bond SE, a simple-to-use, self-etching bonding agent. Oxford Bond SE is designed for use in both direct and indirect techniques. The agent provides strong, reliable bonding of composites, compomers and resin-reinforced glass ionomer materials to dentin and enamel.

Unlike most self-etching bonding systems, Oxford Bond SE can be used for indirect procedures without adding a separate adhesive or dual-cure activator. This simplifies the procedure and makes it more reliable by eliminating any variability in mixing by various staff members, ensuring a tenacious bond with every procedure.

Proven to be superior

Oxford Bond SE provides all the benefits of a cutting-edge self-etch adhesive: less patient sensitivity, ease of use and fewer application steps. It exhibits superior bond strengths to both dentin and enamel. In a laboratory study (data available upon request), Oxford Bond SE showed bond strengths superior to six of the leading self-etch adhesives on the market. Oxford Bond SE received a ++++ rating from The Dental Advisor. More than 50 percent of the evaluators stated they would switch from their current self-etch bonding agent to Oxford Bond SE.

Oxford Bond SE is very simple to use. Application requires only three steps with a total time of 45 to 50 seconds. Light curing is achieved in 20 seconds and self-curing is achieved in 5 minutes.

Oxford Bond is supplied in 5 ml bottles or in 0.15 ml single doses. The single-dose delivery system is highly reliable. Gravity feeds the fluid in the upper chamber into the lower chamber, insuring a complete and homogenous mixing of the components. Each single-dose container has enough to bond to at least three units. This single-dose system provides enough material for a standard procedure without wasting an inordinate amount of bonding agent in the mixing well. It also promotes good infection control.

Oxford Bond SE is competitively priced and represents a very good value for your supply dollar. To order Oxford Bond SE or to obtain additional information, call Finnigan Enterprises at (888) 686-1950 or go to www.oxfordscientificdental.com.

About Oxford Scientific Dental Products

Although the Oxford Scientific brand name may be new to North American dental professionals, the company has been manufacturing dental consumables for a number of U.S. companies for nearly 20 years. Oxford Scientific Dental Products are manufactured to the highest standards. The facility is FDA registered and the products are CE certified.

The company's mission is to provide the dental consumer with the finest quality materials based upon state-of-the-art manufacturing and the pride of a dedicated workforce. The company's portfolio currently contains: a core build-up material, Oxford Zircore Nano, a dual-cure, nano zirconia filler reinforced resin core build-up material that was rated "Excellent-Good" by an "independent, non-profit dental education and product testing institute" in its January 2011 newsletter; a complete line of temporary crown and bridge materials, such as Oxford Temp, a temporary C&B material, Oxford Temp Cem, a temporary cement and Oxford Correct, a flowable composite repair material for the temporary C&B material. Oxford Correct was selected by the "independent, non-profit dental education and product testing institute" for its 2010 Buying Guide, published in its December 2010 newsletter.

The Oxford Scientific Dental Product portfolio will constantly expand to fulfill the needs of every practice for high-quality restorative materials at a competitive price while maintaining a commitment to satisfaction.

Oxford Scientific Dental Products are exclusively marketed and distributed in North America by Finnigan Enterprises of Meriden, Conn., (888) 686-1950.

(Photos/Provided by Oxford Scientific)



An advancement in flowable composites

G-ænial™ Universal Flo, available from GC America, represents the next advancement in the **flowable composites category**. In the past, dentists had to sacrifice strength and esthetics to get the easy handling they loved with a flowable. That is no longer the case.

Studies have confirmed that G-ænial Universal Flo has higher strength, higher wear resistance and higher gloss retention than other flowable composites tested, and even rivals leading conventional composites in these categories as well. Finally, no more sacrifices to get the handling professionals love!

G-ænial Flo is a partner product to G-ænial Universal Flo. It is indicated for use in small cavities and as a cavity liner. This highly radiopaque and highly flowable composite enables easy placement and flow into the preparations for excellent handling.

G-ænial Universal Flo

- _ Handles like a low-flow flowable and performs like a restorative
- _ New, innovative delivery system
- _ Easy access, handling and placement
- _ Highly thixotropic with excellent flow
- _ Recommended for Class I, II, III, IV and V restorations
- _ Higher strength than leading flowables and conventional composites
- _ Higher wear resistance than leading flowables and conventional composites
- _ Higher gloss retention than leading flowables and conventional composites
- _ 15 shades in three opacities
- _ bis-GMA free

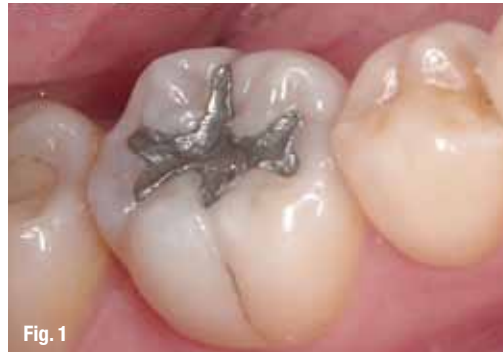

Fig. 1

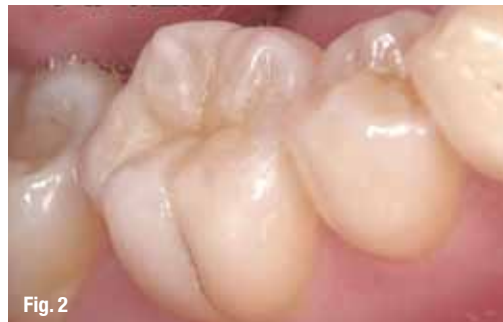

Fig. 2

Fig. 1_Before
Fig. 2_After

(Photos/Provided by GC America)
(Images courtesy of Dr. S. Koide)

G-ænial Flo

- _ High flowability for easy placement and no air voids during placement
- _ Newly designed syringe and tip minimize waste, allow excellent visibility and easier use
- _ Recommended as a base or a liner, a pit and fissure sealant, for small cavities and for minimum intervention dentistry
- _ Higher radiopacity
- _ bis-GMA free



BEAUTIFIL Flow Plus: dentistry simplified

Shofu has a revolutionary product on the market that is already making restorative dentistry a whole lot easier. BEAUTIFIL Flow Plus is an all-in-one final restorative, base and liner with mechanical properties that rival leading hybrids in compressive strength, wear and flexural strength. This syringe-delivered injectable hybrid stands apart from other flowables with its unprecedented approval for all indications and a radiopacity greater than enamel.

Moreover, it has remarkable handling properties that are unlike any other flowable you have tried before, allowing precision stacking and sculpting capabilities with no slump. Additionally, Shofu's proprietary "surface pre-reacted glass" (S-PRG) filler material provides sustained fluoride release and recharge that can otherwise only be found in the far less esthetic glass ionomer materials. All of these features combined put BEAUTIFIL Flow Plus in a class of its own.

_All-in-one base, liner and restorative

Traditional methods of filling and packing hybrids are time consuming and present technique-sensitive issues that may result in postoperative sensitivity and/or failures. Especially in a Class V situation where packing composite materials is a constant battle to get the material to stick to the tooth structure and not to your instruments. With BEAUTIFIL Flow Plus, the material is syringe delivered where needed, including the occlusal and proximal margins. For example, using a syringe delivery in a Class V prep completely eliminates this push/pull effect because once extruded, it self-levels, adapts to the tooth structure and stays put until light cured.

_Effortless adaptation and polishability

The flowable consistency of BEAUTIFIL Flow Plus provides effortless adaptation to tooth structure when compared with hybrids. Because the material is flowed into the preparation rather than being packed in like hybrids, dentists can achieve a tight marginal seal with minimal or no instrumentation. This helps reduce the occurrence of voids inherent in traditional hybrid packing techniques. Furthermore,

the material effortlessly achieves a smooth, ready to polish finish. Dr. Howard Glazer of Fort Lee, N.J., spoke at the 2010 Greater New York Dental Meeting where he explained, "BEAUTIFIL Flow Plus, once applied and photocured, is 95 percent polished."

_Physical properties

BEAUTIFIL Flow Plus was specifically designed to stand up to the rigors of the occlusal surface and marginal ridge. High filler content and unique chemical properties ensure that clinicians have all of the material strength found in leading hybrids. In fact, critical physical properties such as compressive strength, flexural strength, toothbrush wear and other criteria are clinically equivalent or superior to leading hybrids on the market. Using this new approach, dentists can now achieve better adaptation, with a stronger material, in fewer and less complicated steps.

_It stays put

One of the many distinguishing features of BEAUTIFIL Flow Plus is that it stays where it's put. Other flowables tend to run and spill out of the prep. BEAUTIFIL Flow Plus provides precision stacking capabilities with no slump. This is particularly important when working at awkward angles or with fidgety patients. Available in two distinct viscosities, F00 Zero Flow (0 mm of flow held vertically for 1 minute) and F03 Low Flow (3 mm of flow held vertically for 1 minute) that add to dentists' treatment options. F00 is ideal for stacking, especially in the marginal ridge. F03 offers a superior base or liner consistency. That said, the physical properties for both viscosities are identical so they can be used interchangeably.

_Fluoride release and recharge without sacrificing esthetics

One of the main problems with other materials (such as glass ionomers) that recharge fluoride is that they absorb water once placed in the mouth. This causes the glass filler to swell, and the esthetics of the material to break down. Shofu's proprietary

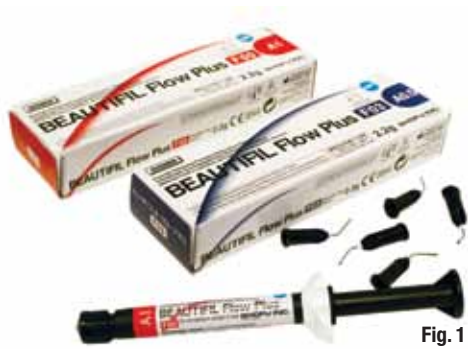

Fig. 1

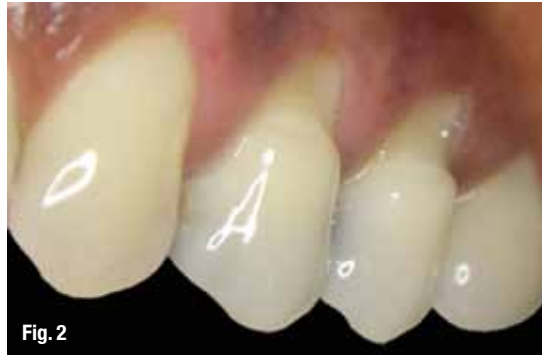

Fig. 2

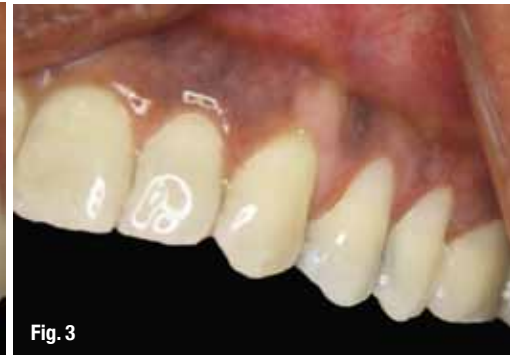

Fig. 3

GIOMER technology utilizes "surface pre-reacted glass" (S-PRG) filler, which has a surface-modified layer protecting the durability and esthetics of the glass from water, while still allowing beneficial ions to travel freely between the glass core and the oral environment.

Many other restoratives release fluoride initially but quickly deplete this charge within a matter of days or weeks. With S-PRG technology, everyday activities such as tooth brushing or rinsing with fluoridated products actually recharge the material's glass core, carrying sustained preventative benefits to adjacent tooth structure over the life of the restoration.

Clinical evidence

Numerous independent clinical studies have documented the biomimetic properties of S-PRG fillers that help to protect and preserve surrounding tooth structure. One such study conducted on the hybrid material BEAUTIFIL II (the FDA predicated product of BEAUTIFIL Flow Plus) highlighted these results.

As published in JADA, the University of Florida found that restorations containing S-PRG filler showed no secondary caries, no failures, no post-operative sensitivity and the material maintained its luster at the 8-year recall. A 13-year recall is currently in progress.

Dentistry simplified

Using state-of-the-art dental materials such as Shofu's injectable hybrid, BEAUTIFIL Flow Plus, provides patients with highly esthetic results that are also efficient and dependable with enduring biomimetic benefits. Dentists no longer have to settle for highly filled hybrid composites that present adaptation challenges or watered-down flowable restoratives that adapt well but are weak, messy and spill out of the prep.

In BEAUTIFIL Flow Plus, you have a single, syringe-delivered restorative that is as strong as hybrid composites, adapts well, handles beautifully, is highly

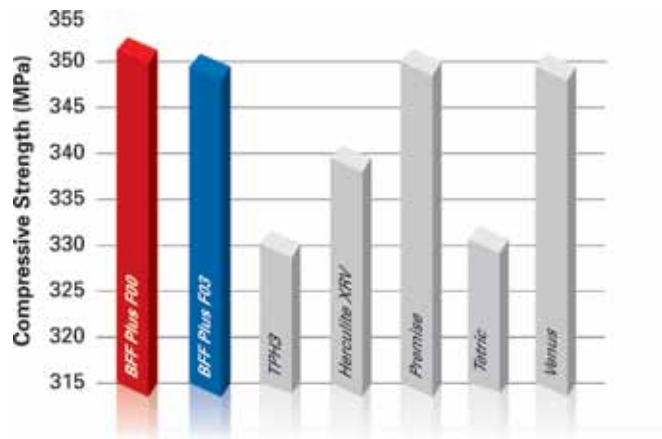


Fig. 4



Fig. 5

esthetic and has clinically proven healing properties. At the end of the day, what more could any dentist want in a restorative?

A name you trust: Shofu BIO

Since 1922, Shofu Inc. has been a leading manufacturer of highly acclaimed dental and laboratory supplies used by dentists, hygienists and laboratory professionals around the world. Shofu Dental Corp., located in San Marcos, Calif., was founded in 1971 to provide direct support for North and South American markets.

Capitalizing on the company's extensive knowledge of polishing technology, Shofu is striving to provide minimally invasive cosmetic solutions to meet the needs of patients while also delivering innovative products that exceed the demands of today's discriminating dentist.

Fig. 1_BEAUTIFIL Flow Plus. (Photos/ Provided by Shofu)

Fig. 2_Class V before treatment.

Fig. 3_Class V after treatment.

Fig. 4_Physical properties of BEAUTIFIL Flow Plus vs. hybrid composites.

Fig. 5_Left F00, right F03.

Quick technique: Tetric EvoCeram

Author Jason Olitsky, DDS, AAACD

Ambient light in the dental examination room when placing composite restorations — a common cause of restorative failure — initiates premature curing of composite materials during final contouring, resulting in less predictable restorations. Solutions have been limited to materials that effectively slow the polymerization process.

However, these materials also increase curing time, making restorations more time consuming and costly. To solve the aforementioned issues, Tetric EvoCeram (Ivoclar Vivadent, Amherst, N.Y.), a universal nano-hybrid composite, was developed to provide dentists the ability to control curing in every situation.

Featuring "Polymerization on Demand," Tetric EvoCeram provides industry-leading working and setting times through the incorporation of a special additive in the photo-initiator system. Less reactive to ambient light, the composite remains highly reactive to curing lights within the wavelength range of 400–500 nm.

A unique feature, the Polymerization on Demand system allows dentists to fully contour restorations and control curing, while the consistency of the material allows for simple placement. Additionally, Tetric EvoCeram demonstrates low polymerization

shrinkage rates to limit incidences of marginal leakage and secondary caries.

Offering the best in esthetics, the refractive indices, monomers and nano-color pigments of the filler particles of Tetric EvoCeram provide life-like results in even the most challenging cases. The unique refractive index creates a chameleon effect, allowing the nano-fillers and nano-color pigments to blend with the natural tooth structures. Further, Tetric EvoCeram demonstrates high translucency and enhances shade adaptation to facilitate the shade matching process in cases requiring direct restorations.

Preventing the reflection of the fillers from scattering incoming light, the nano-hybrid particles demonstrate an average size of less than 550 nm. With this, restorations completed with Tetric EvoCeram offer high radiopacity and are clearly distinguishable from surrounding tooth structures and changes in the dental hard tissues, such as secondary caries. The size of the fillers also allow the composite to be polished in only 30 seconds and offers a high level of gloss similar to pure microfilled and nanofilled materials.

Tetric EvoCeram is indicated for use in a broad range of restorations in the anterior or posterior, and

Fig. 1 The patient presented with failing amalgam restorations in teeth #12–#14. (Photos/Provided by Ivoclar Vivadent)

Fig. 2 After complete isolation was achieved with the OptraDam, the amalgam was removed and the teeth were prepared. Matrixes were then placed and Tetric EvoCeram in the selected dentin shade was layered into the preparations.

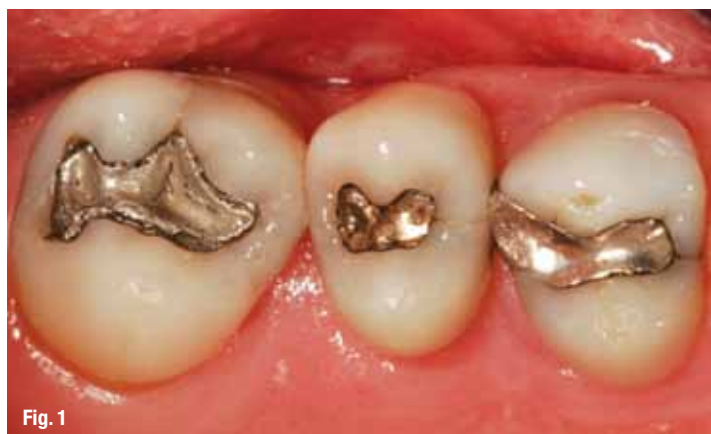

Fig. 1

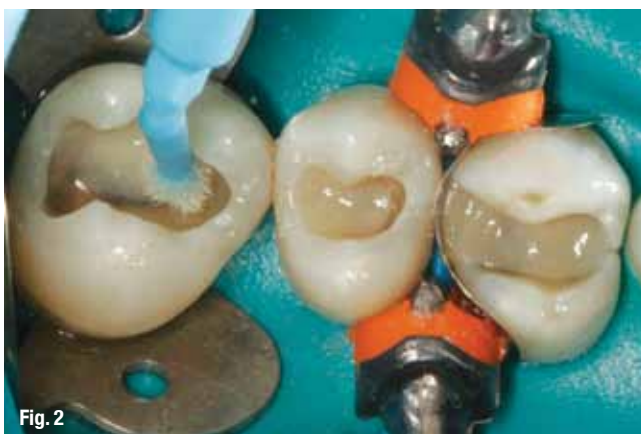

Fig. 2

Oxford Bond SE

A better bond...
at a better price.



Oxford Bond SE gives you everything you'd expect from a 7th generation bonding agent and more... all at a price that's less than the leading competitors'. Oxford Bond SE is a unique, simple-to-use, self-etching adhesive designed for use in both direct and *indirect procedures without requiring additional steps or use of a separate activator.*

THE DENTAL ADVISOR™ consultants liked both Oxford Bond SE's dual-cure feature as well as the single unit-dose packaging. In fact, **54% of consultants reported they would switch to Oxford Bond SE and 79% would recommend it.***

Oxford Bond SE features:

- High bond strengths to both dentin and enamel
- Dual-cure versatility without the need for a separate activator
- Reduced postoperative sensitivity for maximum patient comfort
- Multiple or single-use dispensing for greater convenience

To order the bonding agent that gives you much more for much less, visit www.oxfordscientificdental.com or call 1-888-686-1950.

* Excerpted from THE DENTAL ADVISOR Evaluation, November 2010, Volume 27, No. 09.

Special Introductory Offer!

Get 10% off your purchase of Oxford Bond SE at check-out!
Order online at
www.oxfordscientificdental.com.

Imported to North America exclusively by
Finnigan Enterprises, LLC
Meriden, CT 06450

 Oxford Scientific

www.oxfordscientificdental.com | 888 686 1950

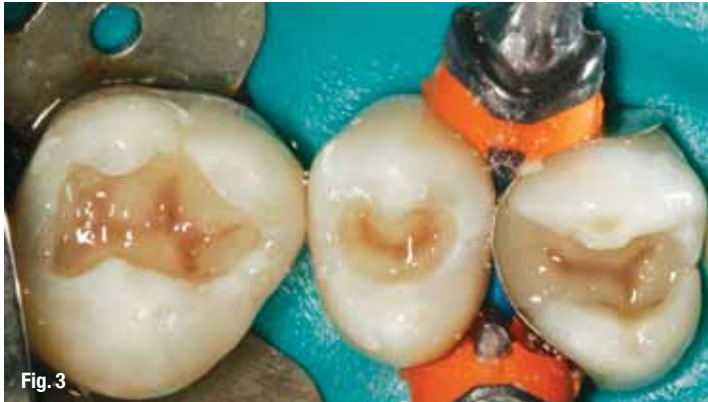

Fig. 3

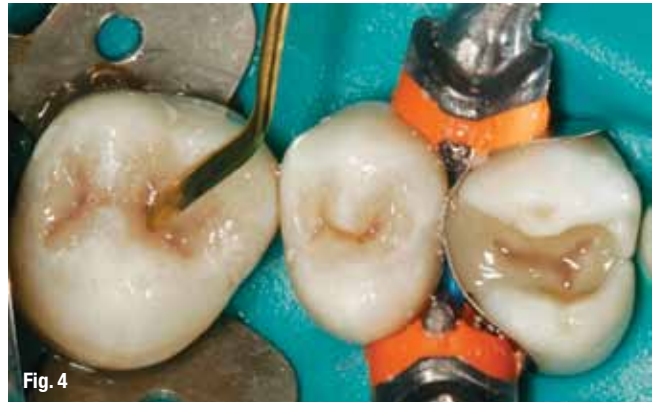

Fig. 4

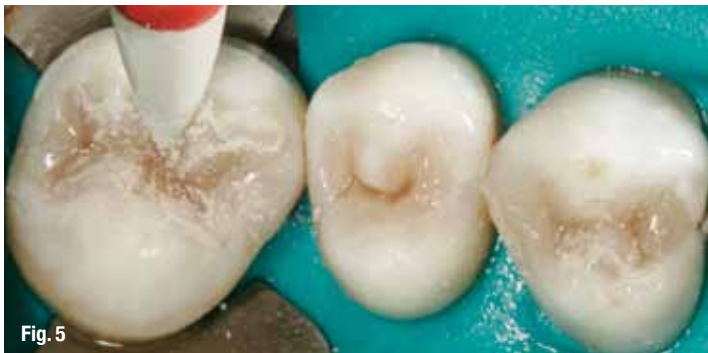

Fig. 5

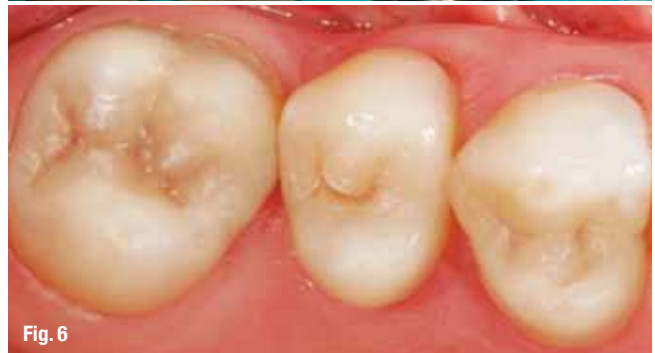

Fig. 6

Fig. 3 The final dentin layers were placed and stains (Tetric Color) were applied to simulate natural discolorations.

Fig. 4 A composite modeling instrument was utilized to place and contour the final layers of Tetric EvoCeram in the selected enamel shade.

Fig. 5 Occlusion was adjusted as necessary and the restorations underwent final polishing with a one-step diamond polishing system (OpraPol).

Fig. 6 The completed Tetric EvoCeram posterior composite restorations demonstrated natural morphology and excellent esthetics.

is available in 22 shades to meet the esthetic requirements of any case. Offered in syringes or Cavifils, the composite can be placed simply and efficiently.

Clinical procedure

- 1) Place a rubber dam (OpraDam) to ensure proper and complete isolation.
- 2) Remove caries or prior restorations.
- 3) Disinfect the preparation with 2 percent chlorhexidine gluconate.
- 4) Apply 35 percent phosphoric etchant gel to the tooth for 15 seconds.
- 5) Place a matrix for cavities affecting the proximal area.
- 6) Place a single coat of unidose desensitizer (Telio CS Desensitizer) on the tooth for 10 seconds to rewet the dentin and to create protein-plugs in the tubules.
- 7) Apply two coats of single dose adhesive/desensitizer (Excite F) on the tooth for 10 seconds each and then air dry (A-dec Syringes, A-dec) to evaporate the solvent.
- 8) Cure the desensitizer for 10 seconds with an LED curing light (Blue Phase 20i).
- 9) Place a single increment, less than 1 mm, of translucent shade flowable liner material (Tetric Flow) on the pulpal floor and cure for 10 seconds.
- 10) Place and condense Tetric EvoCeram in the desired dentin shade with the Excite F applicator brush, taking care to ensure there are no voids between the composite and liner.

11) Place fissures in the dentin layer with a composite modeling instrument, which will facilitate the application of stains (Tetric Color) to simulate discolored fissures and cure the dentin layer for 20 seconds.

12) Place the enamel layer of Tetric EvoCeram in the desired enamel shade, sculpt to proper contour and cure the restoration for 40 seconds.

13) Adjust occlusion with a carbide bur (OS1, Brasseler) and polish the restoration with a one-step diamond polishing system (OpraPol) for 30 seconds.

about the author

cosmetic
dentistry

Dr. Jason Olitsky is an accredited member of the American Academy of Cosmetic Dentistry, instructor and speaker with Gold Dust Clinical Mastery and adjunct faculty at the Arizona School of Dentistry and Oral Health.

contact

cosmetic
dentistry

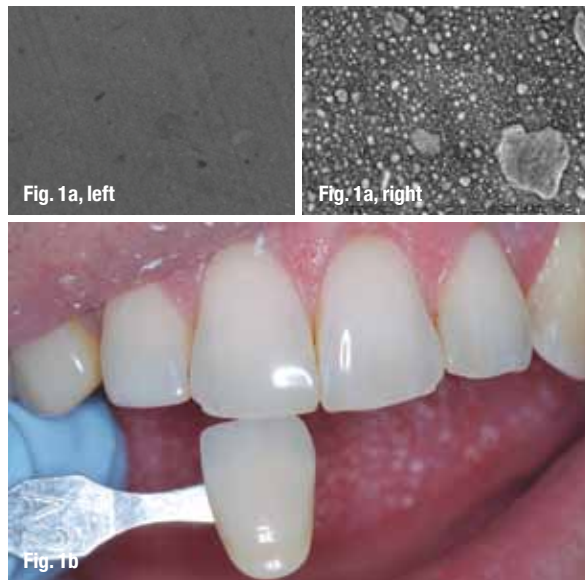
For more information, please contact Ivoclar Vivadent at (800) 533-6825 or visit the company online at www.ivoclarvivadent.com.

A composite for every need

Helping you decide where and how different composite materials can benefit your practice

Modern resin materials have opened a huge door of opportunity for patients and clinicians alike. Composite dentistry is a minimally invasive, affordable option that your patients can accept even in these economically challenging times. With composites you can treat patients in just one office visit and take home the profit.

Although other systems make composite dentistry a daunting task for practitioners – guessing which enamel shade should go over which dentin shade to obtain the desired end result – the Renamel Restorative System is designed to make composites fun and easy. This article examines when and where each composite type can help you in your practice while illustrating the benefits of a systems approach.



How a systems approach helps you

Composites that can simulate tooth structure have given dentists an amazing tool to restore and cosmetically enhance teeth. Cosmedent's Renamel Restorative System is the gold standard of these restorative materials, designed to give you simple and predictable results case after case. This system is the only completely integrated direct bonding restorative system combining microfills, nanofills, hybrids, opaques and tints, flowables and packables.

An integrated system helps you by eliminating the guesswork and stress of color selection. Because all Renamel composites are color matched to each other and the classic VITA shade guide, shade selection is easy and stress-free.

The Renamel System is the most predictable composite system in dentistry because all Renamel composites of the same shade exactly match each other and the VITA shade guide. While other systems make you guess which enamel shade should be layered over your dentin shade, Cosmedent takes the stress away. By having a systems approach to composites, you can layer any material with complete predictability.

Do you want your final restoration to match VITA shade A2? Simple! Whether you use a nanofill, microfill, microhybrid or a combination of materials, your choice is always A2. Do you want to add an opaque or flowable to your restoration? No problem; the choice is still A2 for a perfect and invisible match. Whatever color you want your outermost layer to be is the color you choose throughout your entire restoration. It is that easy!

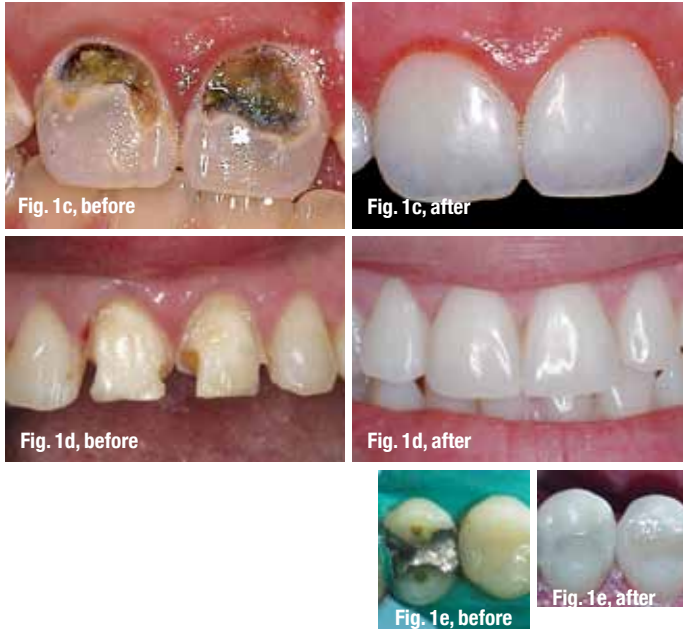Replace enamel = Renamel Microfill

When you wish to simulate or replace enamel, Renamel Microfill should be the composite of choice. Renamel Microfill polishes to an unbelievably beautiful shine and is the only material that will hold its polish long term. This composite also handles beautifully, has a natural translucency and is color stable for many years.

Rated the No. 1 composite in dentistry for the past 15 years, Renamel Microfill is the only material that accurately mimics natural enamel, giving you the best polish, remarkable wear resistance and the

Figs. 1a, left, right Nothing polishes like a microfill. Renamel Microfill (left) vs. a leading nanofill composite (right). (Photos/Provided by Cosmedent) (Figs. 1a-left and right are courtesy of a University of Illinois study)

Fig. 1b Twenty-two and a half years later, this case shows long-term wear resistance and color stability. (Photo/Dentistry and photography by Bud Mopper, DDS, MS)



__Raise value and block color = Creative Color Opaquest

This is the stage where your creativity as a dentist really gets to shine through, so have fun! Creative Color Opaques paint on easily and they help you block light and blend color at the same time. Their 13 shades cover the entire VITA shade range and are perfectly color-matched to all Renamel composites, thus giving you the flexibility to opaque all VITA colors with complete predictability.

__Lower value and add color = Creative Color Tints

Creative Color Tints are used to impart character and help make your restorations look more natural. Unlike opaques, tints decrease value and are great for adding incisal translucency and cervical realism into your restoration.

__Quick and simple composite repairs = Renamel Flowables

Flowable Microfill

Renamel Flowable Microfill is a great solution for increasing your success with Class V restorations and for filling voids in anterior teeth. If you want a flowable microfill with great shades, Renamel Flowable Microfill is it. The 26 shades are perfectly matched to VITA shades and the rest of the Renamel Restorative System to make shade selection quick and easy.

Flowable Microhybrid

Use Renamel Flowable Microhybrid for quick and simple repairs on hybrid and nanofill restorations and small occlusal repairs of all types. Renamel Flowable Microhybrid is radiopaque to distinguish it from tooth structure.

Cosmedent's Renamel Restorative System takes the stress out of shade selection and helps you succeed with composite. As composite becomes an increasingly popular treatment option for patients, it is important to understand why a systems approach can help you make the right decisions.

Cosmedent representatives are always happy to help, so if you have any questions about where and how a composite material can fit into your practice, please call (800) 621-6729.

highest esthetics attainable. Renamel Microfill can be used to replace natural enamel or to replicate the enamel layer in a build-up technique (Figs. 1a, b).

__Extra strength and opacity = Renamel Microhybrid

The No. 1 rated hybrid composite for 18 years, Renamel Microhybrid has a proven clinical record of high strength, long-lasting color stability, superior wear resistance, plus a built-in opacity to block out unsightly shine-through.

With its low porosity and excellent handling, Renamel Microhybrid delivers beautiful results case after case (Fig. 1c). In restorations where extra opacity is required from your composite, Renamel Microhybrid is your choice. Use by itself or as the dentin layer in a build-up technique.

__Strength and esthetics = Renamel NANO

Renamel NANO was designed for clinicians who want to work with just one composite without compromising on strength and esthetics (Figs. 1d, e). Renamel NANO is clinically proven to have low shrinkage and low porosity, plus higher compressive strength than the other leading composites. It has received a perfect score in esthetics from a leading team of evaluators.

Renamel NANO is the perfect composite choice for all posterior restorations and is a beautiful and easy-to-use universal composite for the anterior. If you desire a longer lasting shine than what is possible with a nanofill composite, layer the same shade of Renamel Microfill over your Renamel NANO.

Figs. 1c before, after_Rampant caries and the final restoration, which was done with Renamel Microhybrid

(Photo/Dentistry and photography by Dennis Hartlieb, DDS)

Figs. 1d, e before, after_Esthetics 'Wow!' before and after, which were done with Renamel NANO. (Photos 1d/Dentistry and photography by Newton Fahl, Jr. DDS) (Photos 1e/Dentistry and photography by Bruce LeBlanc, DDS)

한진 Seoul



ICOI World Congress X X V I I I

6~9 October, 2011 | Coex, Seoul, Korea

- Congress Co-Chair_ **Dong-Seok Sohn(Korea), Carl E. Misch(USA)**
- ICOI President_ **Hom-Lay Wang(USA)**
- ICOI Korea President_ **Chong-Yeon Shin**
- Program Chair_ **Su-Gwan Kim(Korea)**
- ICOI Co-Chair_ **Kenneth W.M. Judy(USA), Carl E. Misch(USA)**

Invited Speakers ※ In alphabetic order

- | | | |
|------------------------------|--------------------------------|----------------------------------------|
| • Carl Misch (USA) | • Kyeong-An Joe (Korea) | • Shih-Chang Tweng (Taiwan) |
| • Chen Zhuofan (China) | • Kyoo-Sung Cho (Korea) | • Shiota Makoto (Japan) |
| • Douglas Deporter (Canada) | • Marius Steigmann (Germany) | • Stephen Chu (USA) |
| • Erika Benavides (USA) | • Maurice Salama (USA) | • Tae-ju Oh (Korea) |
| • Giulio Rasperini (Italy) | • Mitsuhiro Tsukiboshi (Japan) | • Trakol Mekayarajjananonth (Thailand) |
| • Hom-Lay Wang (USA) | • Mohammad Ketabi (Iran) | • Tulio Valcanaia (Brazil) |
| • Hyun Jun Jeon (Korea) | • Myron Nevins (USA) | • William Giannobile (USA) |
| • Jim Yuan Lai (Canada) | • Myung-Jin Kim (Korea) | • Yoshiharu Hayashi (Japan) |
| • Keith Doonan (Australia) | • Pablo Galindo-Moreno (Spain) | |
| • Kunihiko Teranishi (Japan) | • Scott Ganz (USA) | |

※ partial list of speakers



Do you require more patient referrals and higher case acceptance rates?

Author_Harold Meredith

Let's start with the most consistent problem we find through the tabulation of patient questionnaires. Patients will not know that you are accepting new patients, and most of the ones who assume or know that you are, are not motivated to refer their friends and family members. On average, 50 percent of patients assume that you are not accepting new patients! Why? You are not communicating that important fact to them, be it verbally or more importantly, visually.

Visual communication is the key to encouraging patients to remember important information presented to them. We recall up to 80 percent of what is presented to us visually compared to less than 10 percent of what is presented through verbal communication. Walk through your office. Are you communicating to patients visually? It is a proven fact that we must repeat something at least seven times before people will retain the information.

Are you communicating to your patients seven times that you accept new patients? You may think this is too much, but in reality, it is very simple to do. Place it on your business card, appointment card, yellow page ad, website, your television systems in your treatment rooms and reception area, outdoor signage, on your wall facing patients in the dismissal area, on your main entrance door, on your on-hold system on your telephone, your custom brochure and your own custom gift card. That was 11 instances.

In addition, there are so many other opportunities to communicate that one simple point, which in turn will be of great importance in building your business!

First, inter-mixing verbal and visual communication is of great importance. Your receptionist is so important in so many aspects of your business. He or she is the first individual whom your patients will meet, speak with, and in most cases, the last person they will speak to when they are exiting your office. Take advantage of the few moments at the end of a visit by communicating the fact that you are accepting new patients, as it is the last piece of information that your patients will hear when they leave your office.

I would suggest that the individual dismissing your patient say something like, "Mrs. Smith, I would like to give you a couple of our new office brochures. If you get a chance to give them to a friend or family member, we always appreciate your referrals." This is a very good way of presenting the information verbally and reinforcing with a visual idea. There are so many ways to do this, and it is important for your team to have systems in place to comfortably ask for referrals.

Take full advantage of the internal marketing opportunities in your practice. Much less expensive than external advertising, once you have the proper team members that create enthusiasm and excitement in your office, internal marketing will help you build your practice more than external marketing in almost all cases.

Secondly, one of the most overlooked aspects of marketing is the "experience" of visiting the dentist. Creating an enjoyable experience through proper team enthusiasm is by far one of the most important ingredients to maintaining and building your patient

‘What are the benefits of becoming your patient, as compared to the practice down the street? For that matter, why visit the dentist at all when I could take that same piece of expendable income and go on a vacation or buy a new car?’



base. The “spa” type practices are certainly building through such simple ideas as hot towels, the new massage dental chairs, warm blankets, televisions in the ceilings, headphones, video games for the kids, a pleasing atmosphere, etc.

Enhancing the experience of the dental visit can be one of the most important aspects to help you build your practice. It is also important that if you have any of these amenities, you should include it in your advertising. Every dentist offers crowns, but few offer many of the amenities just listed.

This brings up a very important point when it comes to advertising and marketing. What sets you apart? What are patients looking for when they are selecting a new product or service? The answer is: benefits! What are the benefits of becoming your patient, as compared to the practice down the street? For that matter, why visit the dentist at all when I could take that same piece of expendable income and go on a vacation or buy a new car?

Your communication, both internally and externally, is of such great importance, yet most offices have no idea how many opportunities they miss due to a lack of proper and effective marketing or communication. Nevertheless, let's talk benefits. These are what set you apart and make the difference in your advertising and creating a sense of urgency through a professional offer.

So, what are the benefits of visiting your dental office? Consider this carefully; as mentioned, the experience of visiting your practice is huge when gaining or retaining patients. However, your experi-

ence and continuing education is vital to growth. The more you know, the more you can help patients, and this of course will increase the possibility of more patients visiting your practice.

Most practitioners feel awkward communicating the fact that they are taking continuing education courses to improve themselves to be of more help to their patients. Most patients will feel more at ease and certainly quite happy knowing that their dentist is on the “cutting edge” when it comes to their dental care.

In closing, communicating visually, understanding the importance of your front office team, your continuing education, the patient experience and benefits are some of the keys to growing your practice. Taking this and creating a professional marketing plan with team members designated for implementing such a plan will certainly elevate you to success. _

Image_DentalVision 3.0 Custom Video Presentation System (Photo/Provided by Dental Marketers)

_contact	cosmetic <small>dentistry</small>
Dental Marketers Tel. (877) 265 9069 Fax (905) 265 9999 www.dentalmarketers.com sales@dentalmarketers.com	

Academy of Osseointegration

*27th Annual
Meeting*

Technology to Practice



Phoenix

March 1-3, 2012

Phoenix Convention Center



ADAC·E·R·P



submissions: formatting requirements

Please note that all the textual elements of your submission:

- _ the complete article,
- _ all the figure captions,
- _ the complete literature list and
- _ contact info (bio, mailing address, e-mail address, etc.)

must be combined into one text document. Please do not submit multiple files for each of these items.

In addition, images (tables, charts, photographs, etc.) must not be embedded in the text document. All images must be submitted separately, and details about how to do this appear below.

If you are interested in submitting a C.E. article, contact us for additional instructions before you make your submission.

_Text length

Article lengths can vary greatly – from a mere 1,500 to 5,500 words – depending on the subject matter. Our approach is that if you need more or less words to do the topic justice then please make the article as long or as short as necessary.

We can run an extra long article in multiple parts, but this is usually discussing a subject matter where each part can stand alone because it contains so much information. In addition, we do run multi-part series on various topics.

In short, we do not want to limit you in terms of article length, so please use the word count above as a general guideline and if you have specific questions, please do not hesitate to contact us.

_Text formatting

Please use single spacing and un-indented paragraphs for your text. Please do not put a blank line between paragraphs.

We also ask that you forego any special formatting beyond the use of italics and boldface, and make sure that all text is left justified.

If you would like to emphasize certain words within the text, please only use italics (do not use underlining or a larger font size). Boldface is reserved for article headers.

Please do not "center" text on the page, add special tab stops, or use underling as all of this must be removed before layout. If you require a special layout, please let the word processing program you are using help you to do this formatting rather than doing it by hand on your own.

If you need to make a list or add footnotes or endnotes, please let the word processing program do it for you automatically. There are menus in every program that will help you to do this.

The fact is that no matter how careful one might be, errors have a way of creeping in when you try to hand number footnotes and literature lists.

_Image requirements

Please number images consecutively throughout the article by using a new number for each image. If it is imperative that certain images are grouped together, then use lowercase letters to designate the images in a group (i.e., Fig. 2a, Fig. 2b, Fig. 2c).

Please put figure references in your article wherever they are appropriate, whether that is in the middle or end of a sentence but before the period.

If you are not directly mentioning the figure in the body of your article, when it appears at the end of the sentence the figure reference should be enclosed within parenthesis and appear before the final period.

In addition, please note:

- _ We require images in TIF or JPEG format.
- _ These images must be no smaller than 4 x 4 inches in size at 300 DPI.c
- _ Images cannot be any smaller than 80 KB in size (or they will print the size of a postage stamp).

Larger images are always better, and something on the order of 1 MB is best. Thus, if you have an image that is greater than 1 MB, please do not bother "sizing it down" to meet our requirements, but send us the largest file size available.

The larger the starting image is in terms of bytes, the more leeway the designer has in terms of resizing the image to fill up more space should there be room available).

Also, please remember that you should not embed the images into the body of the text document you submit. Images must be submitted separately from the textual submission.

You may submit images through a zipped file via e-mail, unzipped individual files via e-mail or post a CD containing your images directly to us (please contact us for the mailing address as this will depend upon where in the world you will be mailing them from).

Please do not forget to send us a head shot photo of yourself that also fits the parameters above so that it can be printed along with your article.

_Abstracts

An abstract of your article is not required. However, if you choose to provide us with one, we will print it in a separate box.

_Contact info

At the end of every article is a contact info box with contact information along with a head shot of the author.

Please note at the end of your article the exact information you would like to appear in this box and format it according to the previously mentioned standards.

A short bio (60 words or less) may precede the contact info if you provide us with the necessary information.

_Questions? Comments?

Please do not hesitate to contact us for our International C.E. Magazine Author Kit or if you have other questions/comments about the article submission process:

Group Editor Robin Goodman
r.goodman@dental-tribune.com

Managing Editor Fred Michmershuizen
f.michmershuizen@dental-tribune.com

cosmetic dentistry

the international C.E. magazine of beauty & science

dti Dental
Tribune
International

U.S. Headquarters

Dental Tribune America
116 West 23rd Street, Ste. 500
New York, NY 10011
Tel.: (212) 244-7181
Fax: (212) 244-7185
feedback@dental-tribune.com
www.dental-tribune.com

Publisher

Torsten R. Oemus
t.oemus@dental-tribune.com

Chief Operating Officer

Eric Seid
e.seid@dental-tribune.com

Group Editor

Robin Goodman
r.goodman@dental-tribune.com

Managing Editor

Fred Michmershuizen
f.michmershuizen@dental-tribune.com

Designer

Kristine Colker
k.colker@dental-tribune.com

Designer

Sierra Rendon
s.rendon@dental-tribune.com

C.E. Director

Julia Wehkamp
j.wehkamp@dtstudyclub.com

C.E. International Sales Manager

Christiane Ferret
c.ferret@dtstudyclub.com

Marketing Manager

Anna Wlodarczyk-Kataoka
a.wlodarczyk@dental-tribune.com

Marketing Assistant

Lorrie Young
l.young@dental-tribune.com

Accounting

Melissa Chan
m.chan@dental-tribune.com

List Manager

Edwin Figueroa
e.figueroa@dental-tribune.com

Product/Account Manager

Mark Eisen
m.eisen@dental-tribune.com

Product/Account Manager

Humberto Estrada
e.estrada@dental-tribune.com

Product/Account Manager & Interactive

Gina Davison
g.davison@dental-tribune.com

International Product/Account Manager

Jan Agostaro
j.agostaro@dental-tribune.com

Dental Tribune America is the official media partner of:



cosmetic dentistry_Copyright Regulations

_the international C.E. magazine of cosmetic dentistry published by Dental Tribune America is printed quarterly. The magazine's articles and illustrations are protected by copyright. Reprints of any kind, including digital mediums, without the prior consent of the publisher are inadmissible and liable to prosecution. This also applies to duplicate copies, translations, microfilms and storage and processing in electronic systems. Reproductions, including excerpts, may only be made with the permission of the publisher.

All submissions to the editorial department are understood to be the original work of the author, meaning that he or she is the sole copyright holder and no other individual(s) or publisher(s) holds the copyright to the material. The editorial department reserves the right to review all editorial submissions for factual errors and to make amendments if necessary.

Dental Tribune America does not accept the submission of unsolicited books and manuscripts in printed or electronic form and such items will be disposed of unread should they be received.

Dental Tribune strives to maintain the utmost accuracy in its clinical articles. If you find a factual error or content that requires clarification, please contact Group Editor Robin Goodman at r.goodman@dental-tribune.com. Opinions expressed by authors are their own and may not reflect those of Dental Tribune America and its employees.

Dental Tribune cannot assume responsibility for the validity of product claims or for typographical errors. The publisher also does not assume responsibility for product names or statements made by advertisers.

The responsibility for advertisements and other specially labeled items shall not be borne by the editorial department. Likewise, no responsibility shall be assumed for information published about associations, companies and commercial markets. All cases of consequential liability arising from inaccurate or faulty representation are excluded. General terms and conditions apply, and the legal venue is New York, New York.

Why settle for Bronze or Silver when...
you can have Gold?

Renamel[®]

THE GOLD STANDARD



Renamel[®] Microfill[™]

- The highest-rated composite in dentistry! This 5-star material has received Reality's "Product of the Year" award a record three times.



Renamel[®] Microhybrid[™]

- #1 rated universal composite for the last decade. Top choice of independent evaluators and clinician's worldwide.



Renamel[®] NANO[™]

- Superb results for all anterior and posterior restorations. A perfect score in esthetics!



Renamel[®] Creative Color[™]

- The #1 rated tinting and opaquing system for over 15 years.

"Renamel has won me over... completely. Superb sculptability, and the most awesome finish!! And, blending at the margins... simply invisible."

— Cosmedent Customer



Perfect Color Match
After 22-1/2 Years

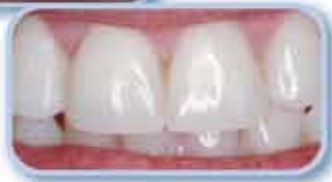

Dentistry and photography by:
Bud Mopper, D.D.S., M.S.



before

Unbelievable
Esthetic Results



after

Dentistry and photography by: Newton Fahl, Jr., D.D.S.

COSMEDENT[™]
Spreading Smiles[™]

TRY OUR 30 DAY
RISK-FREE GUARANTEE.

to order Renamel

800-621-6729

WWW.COSMEDENT.COM

FINALLY, AN INJECTABLE HYBRID RESTORATIVE FOR ALL INDICATIONS

Visit us
AACD

Booth
1906

BEAUTIFIL Flow Plus

- Indicated in classes I, II, III, IV & V
- Physical properties rival hybrids
- Stackable & sculptable; stays put
- Self-polishing "leveling-effect"
- High radiopacity, beyond enamel

BEAUTIFIL Flow Plus is the next step in the evolution of restorative materials, combining the delivery of a flowable and the strength, durability, and aesthetics equal to or better than leading hybrid composites.

Visit www.shofu.com or call 800.827.4638



**F00
Zero Flow**

Stackable

**F03
Low Flow**

Self-leveling

**TRIAL OFFER \$99.95
A \$160.00 VALUE!**

Order now www.shofu.com
Enter code: **CDFP1-11**

