


THE MYTHS & REALITIES OF IMMEDIATELY LOADED DENTAL IMPLANTS

By Allison M DiMatteo, BA, MPS

In recent years an increasing number of articles in dental publications state that evidence-based evaluation and peer-reviewed studies confirm the predictability of immediate loading of dental implants. However, such a generalized and blanket assertion begs questions that narrow the circumstances in which such a statement would be accurate, realistic, and relevant. In other words, is this a myth, or is this a reality?

To achieve a high level of success, it has been suggested that immediate loading of dental implants requires adherence to rigid surgical, restorative, and laboratory protocols. Further, there are multiple important factors in the decision-making process for selecting the best strategy to meet each individual patient's case-specific needs and desired objectives when incorporating techniques for immediately loading dental implants into the treatment plan.

What's hindered understanding and acceptance of the technique over the years have been a lack of long-term clinical trials and fear of change in general, some believe. Additionally, it hasn't helped that there is confusion over what exactly is meant by the term "immediate loading" and the contexts in which the term is used.



Immediate loading has been defined by the ITI Consensus Conference as a restoration placed in occlusion with the opposing dentition within 48 hours of implant placement. This definition has led to one of the myths surrounding immediate loading of dental implants that is addressed later.

According to Jon Julian, DDS, a private practitioner in McPherson, Kansas,

there's a difference between immediate loading and immediate functional loading. Loading an implant involves any device or attachment (eg, healing abutment, tissue former, temporary crown) that puts the implant into connection with the oral cavity, he explains.

"Anything we attach to the implant that brings it into the mouth is going to get pushed and shoved around by the

tongue and by food and, therefore, is loading the implant or stressing the implant," Julian elaborates.

Robert Chapman, DMD, chair of prosthodontics and operative dentistry at Tufts University School of Dental Medicine, explains that what is meant by immediate loading of a dental implant is placement of some type of prosthesis—whether permanent or provisional—at the same time

or very close to the timeframe in which the implants are placed. He says that there is some data that has been developed using radio frequency analysis of implant placement which indicates that the longer clinicians wait during the first month after implant placement before loading the implant, the less stable the implant will be. This relates to the fact that the whole process of osseointegration is one of repair, Chapman explains—repair of the osteotomy (ie, the implant preparation site).

"There may not be quite the stability after a week or so that you may have initially, so there's probably a timeline in which it's most appropriate to do immediate loading of the implant, and that's probably within the first 48 to 72 hours," Chapman says.

Immediate function, on the other hand, involves placing an implant and immediately putting it into full occlusion or into function with the opposing occlusion, Julian says. The difference is that immediately loaded implants can be accomplished with single or multiple implants, whereas he believes immediate function should only be accomplished when joining implants around a curve by a rigid connector (eg, lower denture on four implants).

In this feature presentation, *Inside Dentistry* talks with some of dentistry's leading implant professionals to find out what's realistic and what isn't when it comes to immediately loading dental implants. By clarifying the misconceptions, general



"I DON'T WANT TO BE IRRESPONSIBLE AND ENCOURAGE PEOPLE TO IMMEDIATELY LOAD ALL CASES, BECAUSE THE REALITY IS THAT A LOT GOES INTO CASE SELECTION...IF DONE IMPROPERLY, THERE IS A HIGHER RISK OF FAILURE THAN WHEN THE PROCEDURE IS PERFORMED CORRECTLY."

—JEFFREY GANELES, DMD



RelyX™ Cements have proven their leading position*



Learn why more doctors choose RelyX Cements.*

www.3MESPE.com/RelyXUnicemCement
www.3MESPE.com/RelyXLutingPlus

There's only one way a product becomes the best seller. And that's by proving itself with doctors.

RelyX™ Unicem Cement

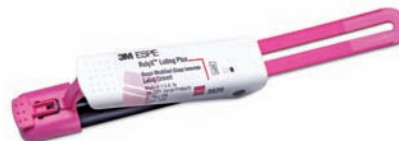- #1 selling resin cement in the U.S.
- 5 years of clinical success
- Very low incidence of post-operative sensitivity
- Easy to use for virtually all indications†

RelyX™ Luting Plus Cement

- #1 RMGI cement in the U.S.
- Award-winning Clicker™ Dispenser
- Sustained fluoride release
- Indicated for metal/PFM crowns, bridges, inlays/onlays, all-zirconia or all-alumina strengthened core ceramic restorations (such as Lava™ Restorations or Procera®)



RelyX™ Unicem
Self-Adhesive Universal Resin Cement



RelyX™ Luting Plus
Resin Modified Glass Ionomer Luting Cement

You + 3M ESPE =
Standards that inspire confidence

For more information call 800-634-2249

3M ESPE

*Based on U.S. sales data.

†For veneers, use RelyX™ Veneer Cement from 3M ESPE.

dentists can be better prepared to discuss with their patients the immediately loaded implant procedure and/or treatment plan cases based on fact, not fiction.

WHAT ARE THE MYTHS? WHAT ARE THE REALITIES?

MYTH: Functional load is implied when referring to immediately loaded implants.

REALITIES: Michael Sonick, DMD, a private practitioner and lecturer, notes that non-functional load (ie, the temporary is out-of-occlusion) is of paramount importance to success. Too much [shear] stress creates implant instability and potential subsequent loss, he says. Normal mastication, oral hygiene habits, and bruxism nonetheless affect interim crowns taken out of occlusion, but to a lesser—and usually clinically insignificant—degree, Sonick explains.

“In particular cases, however, functional load is not problematic, especially if implants are splinted and the opposing arch has a removable restoration,” Sonick says. “For example, immediately loading the mandibular arch with a full, fixed hybrid prosthesis (interim) is not uncommon and in fact is a very predictable method. The success rate of implants mirrors that of non-temporized fixtures. Indeed, Balshi et al reported a 98.5% survival rate of implants in fixed, splinted temporization, with predictors of success being a greater number of implants placed, short cantilever length and adequate quality and quantity of bone.¹”

MYTH: Immediate loading of dental implants doesn't work.

REALITIES: According to Jeffrey Ganeles, DMD, an adjunct professor at Nova Southeastern University College of Dental Medicine and a practicing periodontist, when cases are properly selected and the appropriate techniques, materials, and protocols are used, immediate loading of dental implants does work.

“I don't want to be irresponsible and encourage people to immediately load all cases, because the reality is that a lot goes into case selection,” Ganeles cautions. “If


done improperly, there is a higher risk of failure than when the procedure is performed correctly.”

Henry Salama, DMD, and David Garber, DMD, both private practitioners and members of “Team Atlanta,” note that with proper planning and clinical application utilizing certain guidelines, immediate loading of dental implants can be accomplished successfully for single units and

large cases, in the maxilla as well as in the mandible. Over the last 20 years, in an effort to improve and increase the integration of dental implants into everyday clinical practice, dentistry has significantly modified and enhanced many of the initial clinical guidelines for implant placement, they explained.

Because of the nature of osseointegration, implants need stability and good

blood supply in order for the bone to grow to the surface of the implant, Chapman explains. Therefore, if clinicians don't ensure excellent placement of the implants by selecting an implant that has the best capability of providing stability (ie, is long enough, has the most appropriate macro surface design), ensuring that there's sufficient bone, and verifying that there's adequate blood supply (ie, good width of



87% of the doctors increase their production after hearing Dr. Barnes. The other 13% never try.

Hear him on Friday, jump start your practice on Monday.

Hear the WORLD LEADER.

We invite you to hear the legendary Dr. Dick Barnes. Get ready to move your practice to the next level. Come and hear the world leader in practice development. If you've never heard Dr. Barnes or if it has been awhile, now is the time to give your practice a boost. Learn how to reach a higher level of expertise in your practice. Discover how hundreds have easily implemented changes that increased their production. Be sure not to miss this program with the celebrated Dr. Dick Barnes.

September 19 Albuquerque, NM
October 3 Grand Rapids, MI
October 17 Columbia, SC
October 24 Raleigh, NC
November 7 Kansas City, KS
November 21 Shreveport, LA

9:00 am - 3:00 pm
Lunch is provided
\$199 Doctor
\$35 Staff
5 AGD CE credit hrs.

You will learn:

- To implement proven practice building techniques by providing ideal treatment for patients
- The art of case presentations, a step-by-step procedure for achieving acceptance of treatment. How to do a presentation on full mouth reconstruction case
- To implement a proven structure designed to increase retention of new patients
- To comfortably convince patients to accept treatment
- What to say to patients who say they want to think it over
- Controlling your practice by recognizing and supporting the responsibilities of your staff

DR Dick Barnes

The World Leader.

Call 1-800-800-7200 today for further information.
(Circle 103 on Reader Service Card)

¹ Balshi SF, Allen FD, Wolfinger GJ, Balshi TJ. A resonance frequency analysis assessment of maxillary and mandibular immediately loaded implants. *Int J Oral Maxillofac Implants*. 2005; 20(4):584-594.

bone), then no matter how nice the final crowns look, the process is going to fail, Chapman warns.

MYTH: Immediate loading of dental implants can't or shouldn't be done.

REALITIES: According to Julian, research and clinical experience have demonstrated that immediate loading can be accomplished under the right circumstances. The right circumstances, he says, are not based necessarily upon a set of rules, but rather decisions based on clinical reality. How dense is the patient's bone? What type of occlusion does the patient have?

"The research that I'm seeing suggests that the sooner we stress the *bone* [following implant placement], the better quality the bone becomes around the implant," Julian says. "The trick is to not overstress the *implant* by allowing occlusal forces to overload it."

Chapman notes that the occlusion must be meticulously developed so that the stresses on the implant—both vertically and horizontally—are within the parameters where osseointegration can occur.

However, Krauser notes that immediate loading is not appropriate for all cases, since some implant sites may have bone defects that require bone and soft tissue regeneration leading to a mature bone prior to implant placement or immediate loading. Therefore, those cases may be best suited for staged implant placement, not immediate loading.

"It's very important to understand that there are occasions when you plan to immediately load implants, but that when you get into the clinical situation, you find the requisite criteria (eg, initial stability, bone quality) cannot be met," explains Nitzan Bichacho, DMD, professor and head of the RE Goldstein Center for Aesthetic Dentistry and Clinical Research Department in Hadassah, Jerusalem. "If those requisite criteria cannot be met, then you should not immediately restore the implants. Therefore, in most cases, unless you have very good data that was analyzed before the surgery, you need to prepare for an alternative."

Patients need to be aware of this possibility, Bichacho says, as well as prepared for it. After all, one of the biggest advantages of immediately placing and resting an implant is the emotional impact it has for the patient, he explains.

MYTH: Immediately loaded implants may be at higher risk for failure in the future.

REALITIES: According to Ganeles, this isn't true, and he notes that once an implant integrates, it doesn't matter how it was loaded. However, many implants

PROTOCOL & PATIENT CONSIDERATIONS FOR IMMEDIATELY LOADED IMPLANTS

There are numerous factors to review before considering immediate loading as a possible treatment approach for an edentulous patient, regardless of their case type. Clinicians contemplating immediate loading need to understand that it is a viable treatment alternative for their patients, but one that requires a good knowledge of the healing process of dental implants, explains Jeffrey Ganeles, DMD.

As Lyndon Cooper, DDS, PhD, explains, an ideal immediately loaded implant is one that is ideal in all aspects of its placement and restoration, but just happens to have sufficient primary stability in a patient that can manage the provisional loading period without risking success.

Immediate loading requires that all parts of implant dentistry be accomplished well (ie, surgery, grafting—if needed, occlusal management, construction of the provisional restoration). As others have commented, Henry Salama, DMD, and David Garber, DMD, caution that immediate loading of dental implants demands a more detailed level of pre-planning than a delayed loading protocol, and their advice for general dentists is to collaborate with their surgeons and laboratory technicians to formulate a system for delivering the case and delegating responsibilities.

1. Case Analysis and Diagnosis. Jack Krauser, DMD, says clinicians must identify and study what the needs are of the patient (eg, how long they had missing teeth). What kind of a case is it? Is it a conversion of a denture to teeth, or is the patient losing their natural teeth and seeking to bypass the denture via a fixed reconstruction? The case type is critical to the way in which the immediate-loading procedure will proceed, Krauser says.

Robert Chapman, DMD, says that like anything else in the biomedical sciences, a good diagnosis—based on radiographs, medical history, study casts—is the place to start. Knowing what potential problems may be related to osseointegration (eg, radiation therapy, medications that retard bone healing) is important in order to identify patients that may not be good candidates for implants in general.

2. Determine bone quality and quantity. "You must have a clinical judgment of the volume and quality of

bone into which you're placing your implant so that it can gain primary stability," Jon Julian, DDS, emphasizes. "That's key."

Julian believes that if there is good primary stability and a very rigid, immovable connector or abutment connection to the implant is used, then the implant can be immediately loaded even if the clinician is grafting in that situation. However, he clarifies that this would only be done for anterior teeth in cosmetic situations.

3. Consider the soft tissue condition. Addressing soft tissue issues and anatomical factors around an extraction site can involve considerations of either resorption or remodeling of the bone socket. With grafting, most of the elements of the socket or bone ridge can be preserved, Krauser explains. If an implant is placed at the same time as an extraction, the potential for bone changes may be greater than for a healed, mature ridge. If there is simultaneous extraction and placement, there are decisions that involve soft and hard tissue responses that occur during the integration phase that may require adjustment of the final prosthetic margin, he elaborates.

"The status of the buccal aspect 'sets your fate,'" Krauser says. "This means that greater resorption will occur if the plate is injured, missing, traumatized, or involved in the infective-inflammatory response of the site. A thick plate tends to be more stable over time. Positioning coupled with decision-making and timing are critical elements."

4. Determine the ideal location for the implant. According to Cooper, an immediately loaded implant must be in an ideal location to support its clinical and functional success, as well as esthetics. "The implant has to be in a good position, the abutment has to be the right abutment, and the contour of the restoration has to be ideal to support long-term hygiene and prevent peri-implantitis," Cooper says.

He notes that he has seen cases in which clinicians have added an additional implant or moved the location of an implant to try and assure the immediate success of an immediate-load prosthesis, but they've

only compromised the long-term clinical outcome, particularly in terms of esthetics.

Chapman recommends that treatment plans include the use of CT scans and surgical guides. Guided surgery increases the likelihood that implants will be placed into the depth that is needed while simultaneously ensuring that there is sufficient bone and good blood supply, he says.

5. Take the single-tooth implant out of function. This protocol should be followed to ensure that the single-tooth implant does not touch in any excursive movement. Therefore, clinicians should identify patients with pathologic habits, such as bruxism and clenching, and protect them from those habits by utilizing nighttime appliances to support the occlusion, Julian recommends.

6. Have the correct armamentarium available. Having the correct inventory of products in the correct sizes available chairside, as well as an inventory of different types of bone graft materials, is important, believes Krauser.

7. Know/prepare the prosthesis to be placed on the implant. Chapman says part of the treatment planning process is knowing how the occlusion is to be developed and what type of prosthesis is to be placed on the implant to achieve patient comfort and esthetics, but most importantly to ensure stability.

Nitzan Bichacho, DMD, emphasizes that the prosthetic component of the immediately loaded dental implant treatment plan is very important. He adds that clinicians need to be able to restore the implants—whether they're single or multiple implants—in such a way that they won't be disturbed for at least 2 months after placing the restoration.

"From the very start the restoration must be accurate, as well as rigid, which is very important," Bichacho says. "Clinicians need to understand very well both the surgical aspect and the prosthetic part—the occlusion, the type of connection, and the type of abutment (ie, cemented or screw-retained). All of these things are important."

placed before Bränemark's landmark publications had success rates somewhere in the 50% range, he says, and many of those were immediately loaded. As a result, early implant protocols in general steered clear of immediately loading anything, Ganeles recalls.

"As we've acquired more knowledge about osseointegration, we've realized that loading isn't necessarily the key ingredient for successful healing," Ganeles believes. "Instead, we're paying more attention to movement of an implant rather than loading of an implant. It's a subtle distinction, but a very important one."

According to Bichacho, requisite criteria for a successful immediate loading implant procedure include initial stability of the implant after insertion; preferably the use of multiple, splinted implants around the curvature of the arch; and provisional prosthetics—whether in full contact or out of occlusion—that are not disturbed during the healing process. Prior to placing the implant, consideration should be given to bone quality/quantity into which the implant is being placed, as well as the shape, macro- and microstructure, and surface texture of the implant, he adds.

"You can place an implant outside of the boundaries that I described, but then you take risks, and the implant might fail," Bichacho cautions. "Usually, when implants fail, the treatment becomes much more complicated. This is why I would

not take risks. I would recommend to be very rigid in the fulfillment of the prerequisites, and if all of those prerequisites—not just a few of them—cannot be met, then the implant should not be immediately loaded—period."

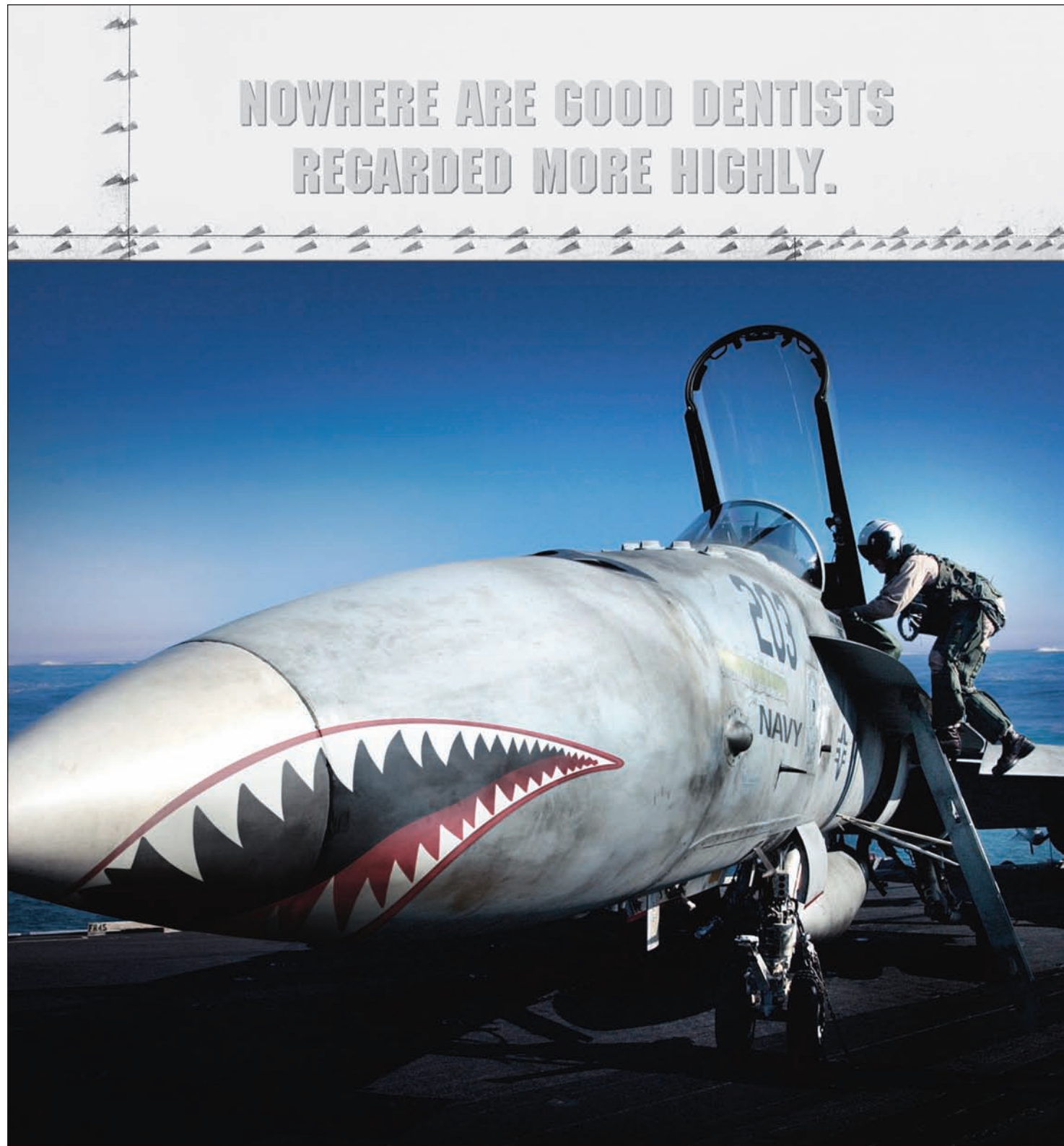
MYTH: All immediate loading dental implant cases can be approached in the same manner.

REALITIES: Different cases that are appropriate for immediate loading should be handled differently based on whether the case involves a single implant, a partially edentulous ridge, or a fully edentulous ridge, explains Jack Krauser, DMD, a private practitioner and lecturer.

When Carl Misch, DDS, MDS, the director and founder of the Misch Implant Institute and co-chairman of the board

of the International Congress of Oral Implantologists, instructs students at his institute, he identifies four categories of immediate load patients and the risk factors associated with each. There are those who will receive an overdenture with implant retention; completely edentulous patients with multiple implants and fixed full-arch prostheses; patients with multiple adjacent teeth (ie, partially edentulous)

NOWHERE ARE GOOD DENTISTS
REGARDED MORE HIGHLY.



"USUALLY, WHEN
IMPLANTS FAIL,
THE TREATMENT BECOMES
MUCH MORE COMPLICATED
...I WOULD RECOMMEND TO
BE VERY RIGID IN THE
FULFILLMENT OF THE
PREREQUISITES, AND IF ALL
OF THOSE PREREQUISITES—
NOT JUST A FEW OF THEM—
CANNOT BE MET, THEN
THE IMPLANT SHOULD
NOT BE IMMEDIATELY
LOADED—PERIOD."

—NITZAN BICHACHO, DMD



The Navy is ready to show its teeth at a moment's notice. So if you'd like to be part of something bigger than a standard-issue, nine-to-five practice, maybe it's time to look into a career as an Officer in the Navy Dental Corps. It's where you'll find competitive pay, state-of-the-art facilities, and the satisfaction of helping those less fortunate — not to mention the respect of the men and women who proudly serve our country. Learn more about full- or part-time service opportunities at navy.com or by calling 1-800-USA-NAVY.

©2007. Paid for by the U.S. Navy. All rights reserved.

NAVY

(Circle 104 on Reader Service Card)

"GENERALLY, IF AN IMPLANT HAS PRIMARY STABILITY UPON PLACEMENT, THEN IT HAS A VERY GOOD CHANCE OF INTEGRATION REGARDLESS OF LOAD TIMING."

—MICHAEL SONICK, DMD

in which implants will be placed and splinted together for the immediate load; and then patients with a single missing tooth who will receive a single tooth implant, he explains. Those four types of patients for immediate loading procedures each have different risk factors associated with them and require different approaches.

Salama and Garber reiterate that the applications for immediate loading are

not the same in all applications. Immediate loading of a full-arch restoration is quite different than immediately loading a single-unit restoration in both technical and biomechanical perspectives, they explain. Additionally, the parameters for successfully immediately loading an anterior tooth are different from those associated with a posterior tooth, Salama and Garber say.

MYTH: Osseointegration/level of bone will be negatively affected by immediate loading.

REALITIES: According to Sonick, some studies have shown that a certain level of micromovement may *promote* bone apposition and density rather than resorption. Histology around immediately loaded implants in function for 8 to 9 months demonstrates bone-to-implant contact (60% to 70%) on par with delayed load fixtures, he says.²

"There is no difference in survival rates either. A Cochrane systematic review (11 RCTs, 300 patients) determined that there was no difference between immediately or conventionally loaded implants with respect to implant failures or marginal bone levels," Sonick explains. "If applicable, splinting immediate prostheses seems to enhance success. Generally, if an implant has primary stability upon placement, then it has a very good chance of integration regardless of load timing."³

MYTH: All implants are the same in the context of immediate loading.

REALITIES: According to Ganeles, the type of implant used for immediate loading (ie, length, surface-coating) impacts the procedure. "Only a few different types of implants have any track record with these kinds of procedures," Ganeles explains. "If you're using an implant du jour or an off-brand implant that doesn't have a track record, then you're experimenting."

Bichacho comments that today's active implants provide initial anchorage for all bone types and demonstrate the capability of expanding the bone during insertion, without an osteotome, so the insertion site is not too wide. He also notes that most implants today are surface treated adequately to provide good biologic response.

MYTH: A great number of immediate loading cases are being performed.

² Piatelli A, Paolantonio M, Corigliano M, Scarano A. Immediate loading of titanium plasma-sprayed screw-shaped implants in man: a clinical and histological report of two cases. *J Periodontol.* 1997;68(6):591-597.

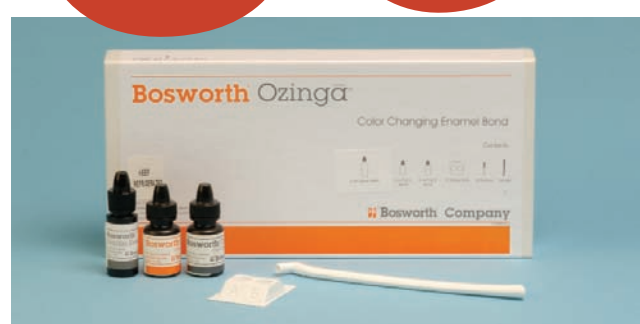³ Esposito M, Murray-Curtis L, Grusovin MG, et al. Interventions for replacing missing teeth: different types of dental implants. *Cochrane Database Syst Rev.* 2007;(4):CD003815.

savings up to
50%

Find out what's new
at Bosworth and save!

Visit Bosworth at
ADA Annual Session
Booth #1708

October 16-18 • San Antonio



Ozinga®

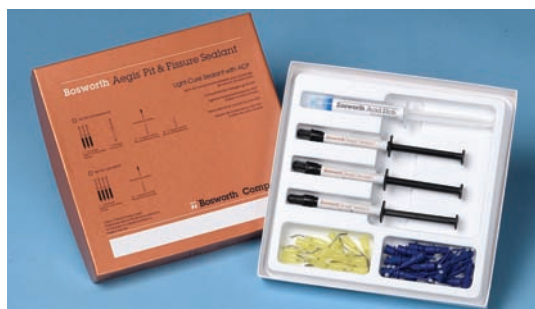Color-changing universal bond.
Now you see it, now you don't!

Buy **1**
Get **1**
FREE!



Aegis® Pit & Fissure

Protect your patients from bacteria and acid
with the help of ACP!



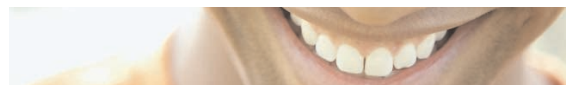15%
rebate



ComfortCaine®

Topical anesthetic gel in 6 flavors for oral
mucosal application. 20% Benzocaine.

Buy **5**
Get **1**
FREE!



*To receive rebate or free goods, send a copy of this ad and a copy of your favorite distributor invoice dated 9/1/08 - 9/30/08 to: The Bosworth Company, 7227 N. Hamlin Ave., Skokie, IL 60076 or fax to (847) 679-2080. All invoices must be received by 10/31/08. Offer not available with any other promotion.

Bosworth Company
P: 1.800.323.4352 • www.BOSWORTH.COM

REALITY: Krauser observes that immediate loading procedures are not being performed as often as they are perceived to be performed. “It’s a very popular lecturing topic at implant meetings, so it gives the impression that they’re being done frequently,” Krauser says. “According to a Q1 2008 report from Millennium Research Group, up to 12%, and anecdotally from meetings and colleagues up to 20%, of cases are being done with immediate loading.”⁴

MYTH: Esthetics may become compromised with immediate loading.

REALITIES: If an implant restoration is to be immediately placed, it MUST be an interim one, Sonick emphasizes. A temporary crown with appropriate contours and emergence profile will encourage papilla to form, he adds.

“During the osseointegration period, the dentist may have to adjust the temporary minutely and wait for the desired effect, a process that may require several tries, but in the end, a beautiful temporary should translate into a beautiful (and easily fabricated) final prosthesis,” Sonick explains. “Development of an ideal mucosal drape around an implant takes time and technical skill but is well worth the effort. There are certainly reports in the literature that outline methods of doing this.”⁵⁻¹¹

Chapman cautions that not overloading the occlusion is important. For this reason a temporary prosthesis often is a better approach than a final prosthesis for many immediate loading patients. The occlusion and the esthetics can be modified if needed, he says.

MYTH: Placing implants in the most ideal position is a complex process.

REALITIES: Krauser says that it is not the actual placement of the implant for immediate loading that is complex, but rather the pre-placement planning that’s involved to ensure synchronized processes. Adds Ganeles, it’s not about difficulty, but about precision.

“Immediate loading is what I call the NASCAR of implants. When you pull in for a pit stop, a lot of things happen at the same time,” Krauser says, elaborating on the analogy. “So when everybody that’s part of the treatment team is operating at a high level of skill, you’re treating the right cases, using the right size implants or prosthetic abutments, and it involves management concerns that are addressed ahead of time.”

As Ganeles explains, it’s not easy to achieve good results, but planning and adhering to protocol enable clinicians to realize predictable results. “The devil really is in the details with these kinds of cases

because there are so many of them,” he says. “However, immediate loading of dental implants can be made extremely predictable when all the details are accounted for.”

Krauser notes that today, with the advent of cone beam CT for improved diagnosis and planning, dentists know in advance the type of bone into which they’ll be placing the implant and the trajectory of it. Also, such technology enables them to determine if they can place the implant in a favorable spot for the ultimate prosthetics, whether there will be a need for grafting, and, most importantly, whether it’s a good case for immediate loading.

Further, three-dimensional data about the patient’s case can be imported into an implant planning software to create a surgical guide or template that will enable the clinician to place the implants in a very predictable way. Also, Krauser says, the provisional restoration can be made before initiating the actual surgical event.

However, regardless of the technological tools employed to facilitate the process and enhance predictability, Ganeles emphasizes that there must be a high level of expertise throughout the whole immediate loading process. In a traditional implant delivery procedure, it means that

⁴ Millennium Research Group. Q1 2008 data. Report surveying US general practitioners, oral and maxillofacial surgeons, periodontists, and prosthodontists.

⁵ Elian N, Tabourian G, Jalbout ZN, et al. Accurate transfer of peri-implant soft tissue emergence profile from the provisional crown to the final prosthesis using an emergence profile cast. *J Esthet Restor Dent.* 2007;19(6):306-314.

⁶ Kourtis S, Psarri C, Andritsakis P, Doukoudakis A. Provisional restorations for optimizing esthetics in anterior maxillary implants: a case report. *J Esthet Restor Dent.* 2007;19(1):6-17.

⁷ McArdle BF. Using a fixed provisional prosthesis during post-extraction healing and implant placement. *Compend Contin Educ Dent.* 2006;27(3):179-184.

⁸ Ganddini MR, Tallents RH, Ercoli C, Ganddini R. Technique for fabricating a cement-retained single-unit implant-supported provisional restoration in the esthetic zone. *J Prosthet Dent.* 2005;94(3):296-298.

⁹ Macintosh DC, Sutherland M. Method for developing an optimal emergence profile using heat-polymerized provisional restorations for single-tooth implant-supported restorations. *J Prosthet Dent.* 2004;91(3):289-292.

¹⁰ Touati B, Guez G, Saadoun A. Aesthetic soft tissue integration and optimized emergence profile: provisionalization and customized impression coping. *Pract Periodontics Aesthet Dent.* 1999;11(3):305-314.

¹¹ Buskin R, Salinas TJ. Transferring emergence profile created from the provisional to the definitive restoration. *Pract Periodontics Aesthet Dent.* 1998;10(9):1171-1179.

EDUCATION & TRAINING FOR IMMEDIATELY LOADING DENTAL IMPLANTS

Carl Misch, DDS, MDS, teaches immediate-loading procedures within his institute, but only after the participants have learned a structured, multi-phased program of traditional implant approaches. “Not only do they have to learn that, but they should perform traditional unloaded healing approaches 50 times so that they’re completely comfortable with the procedure,” Misch explains. “It’s been shown in the literature that about 50 patients are required before you’re knowledgeable enough to know what not to do rather than just what is ideal.”

Misch says the education then should proceed from the structured program and placing 50 implants to taking another course specific to immediate loading that lasts more than just 1 day. Additionally, clinicians should pursue education that addresses the four patient types and their risk factors, he says.

According to Jon Julian, DDS, clinicians have to perform the procedures in order to obtain the necessary experience, but that doesn’t mean that a beginning doctor should make an immediate-loaded implant his or her first case. On the other hand, until he or she does one, they won’t have experience with it, he says.

“I believe the doctor needs to have some degree of self-judgment where he or she determines that they would like to take another step, and that may be early in their implant career or it may be after they’ve placed many of them,” Julian says. “I think having a mentor, a person to work with, is very important.”

Lyndon Cooper, DDS, PhD, adds that there are excellent postgraduate dental implant educational programs in the United States and throughout the world that offer multi-year educational experiences in prosthodontics, periodontology, and oral and maxillofacial surgery in which immediate loading is part of the curriculum. There are also implant fellowships in which dentists who have completed postgraduate education in prosthodontics or other specialties can acquire implant surgical experience in 1-year mentor fellowships in an academic setting, he says.

“I can’t imagine someone learning everything they need in a day or two,” Cooper suggests. “The education and training necessary to become skilled and proficient in these techniques are a combination of experiences that include surgical placement of implants, diagnosis and treatment planning of complex restorative cases, and putting all of the components together.”

“NOT ONLY DO THEY HAVE TO LEARN [IMMEDIATE-LOADING PROCEDURES] BUT THEY SHOULD PERFORM TRADITIONAL UNLOADED HEALING APPROACHES 50 TIMES SO THAT THEY’RE COMPLETELY COMFORTABLE WITH THE PROCEDURE,” MISCH EXPLAINS.

“IT’S BEEN SHOWN IN THE LITERATURE THAT ABOUT 50 PATIENTS ARE REQUIRED BEFORE YOU’RE KNOWLEDGEABLE ENOUGH TO KNOW WHAT NOT TO DO RATHER THAN JUST WHAT IS IDEAL.”

—CARL MISCH, DDS, MDS

a surgeon, restorative dentist, and laboratory technician would be collaborating, using the same set of plans and understanding what each needs to accomplish, he explains.

According to Salama and Garber, the first and probably biggest challenge in the application of immediate loading is the additional layer of logistical planning that's required to coordinate the delivery of both the surgical and the restorative therapy in the same day, or certainly within a couple of days. Unlike in Europe and the rest of the world, American dentistry, in particular, emphasizes specialties, and the vast majority of the general practitioners in the United States rely on their periodontists or oral surgeons to place their implants, they said. As a result, this approach requires coordination between at least two offices and their staffs, as well as the preparation of the appropriate inventory, Salama and Garber explain.

"People see this procedure being done on a television screen at a meeting and they see it occurring very quickly, without a flap, without much bleeding, and the whole procedure has occurred in an hour or two, and the implication is that it's very simple," observes Lyndon Cooper, DDS, PhD, chair and graduate program director of the department of prosthodontics at the University of North Carolina School of Dentistry. "Highly skilled people have worked a long time to learn how to do this, and the simplicity of the appearance belies years of experience and a great deal of planning. For every hour we spend immediately loading a dental implant, there are several hours of planning and several more hours of laboratory work."

MYTH: Only short-term and/or anecdotal evidence has been reported regarding immediate loading of dental implants.

REALITY: According to Sonick, prospective studies on immediate temporization continue to accumulate, although it is true that most published data involve 1-year results or case reports. He notes that a 7-year-long investigation on immediate loading of completely and partially edentulous jaws found ~94% implant survival, with the prosthetic survival rate ~99%.¹²

MYTH: Immediate loading of dental implants is not suitable for all patients.

REALITIES: In the right circumstances, if the prerequisites can be met, and with proper treatment planning, immediate loading of dental implants can be recommended for patients with all types of

DISCLOSING THE RISKS & REWARDS OF IMMEDIATELY LOADED IMPLANTS

According to Carl Misch, DDS, MDS, it's implied by some lecturers and authors that the success rate of immediate loading is similar to that of traditional unloaded healing protocol. However, he says there are studies comparing the two that show the risk of failure (ie, implants not integrating) to be about 10%, in some cases higher and others lower.

"For the novice, that 10% sounds like a minor factor considering some of the benefits that are being touted for immediate loading," Misch observes. "They don't understand that when the implant fails, it also destroys the bone around the implant, often to the point that the labial plate or the facial plate of the bone is completely lost."

If that implant happens to have been placed on a bone graft, this means that this particular implant failure could result in insufficient bone to re-implant, Misch says. It is this type of higher risk that isn't being mentioned enough, he says.

"People are taking the risk without understanding that the risk is not only an implant failure, but often a need to bone graft. The bone graft procedure is not as predictable as the implant procedure," Misch says. "So now, on a patient that had a failure, we're doing an even higher-risk procedure as a consequence of the failure."

An implant failure that results in the need for a bone graft and re-implanting the implant is the economic equivalent of losing the profits of five successful cases, Misch emphasizes. In other words, the overhead is high enough in implant dentistry that when it's necessary to redo the implant and add a bone graft to it, the profit from one successful case is insufficient to cover the cost of the failure.

"It takes about five successful cases to cover the failure," Misch says. "Therefore, a 10% failure rate means you're cutting your income in half because it takes five successes to equal the failure."

The least risk for immediate load is for a mandibular overdenture, Misch explains. His approach would be to splint these implants together within a week. However, if the implants were allowed to heal without a load, they wouldn't need to be splinted together and still would be very predictable, he says.

"The profession has been given the impression that patients want their teeth faster and that they're willing to take the risk," Misch says. "However, what I've seen in my practice is that when I do immediate load, I charge an extra 20%. That increased fee lets patients know there's a higher risk and, when given the option of paying more for the increased risk, almost all of them would rather pay less and have less risk."

Nitzan Bichacho, DMD, emphasizes that patients who come into the practice with big expectations for immediate loading of dental implants need to understand that in order for the treatment to take place, some objective criteria and conditions must be present, and those cannot always be predicted before surgery. He recommends that the dentist prepare an alternative treatment in the event that the implant cannot be immediately loaded.

"I suggest the dentist be fully open with the patient and not become entangled in the patient's wishful thinking. Be very realistic about the treatment," Bichacho says. "This is very important. It's important not to proceed with a treatment scheme just because the dentist wants to do it for the patient, especially if the situation and the clinical parameters won't enable him or her to execute such a procedure."

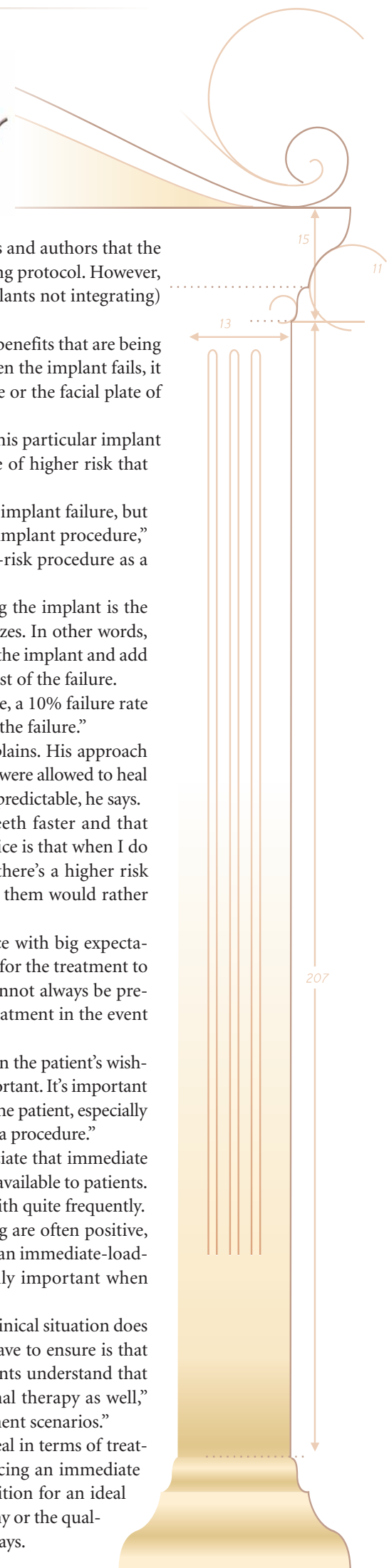
Lyndon Cooper, DDS, PhD, believes that general practitioners need to appreciate that immediate loading or provisionalization of an implant in the edentulous lower jaw is largely available to patients. In other words, he says it's something that dentistry can offer and then succeed with quite frequently.

"When we get beyond the lower jaw, the opportunities for immediate loading are often positive, but the reality of that risk/benefit equation is such that we prudently divert from an immediate-loading plan," Cooper admits. "Making careful risk/benefit calculations is especially important when extracting a tooth and placing an implant and a crown in one visit."

There are many reasons for that, Cooper says, but the main reason is that the clinical situation does not support the long-term functional success of the implant. "What clinicians have to ensure is that when they discuss the range of opportunities with their patients that their patients understand that with the immediate-loading scenario, they need to be prepared for conventional therapy as well," explains Cooper. "This means clinicians should be prepared for alternative treatment scenarios."

Cooper explains that immediate loading of dental implants requires a great deal in terms of treatment planning and bone quality/quantity in order to ensure success. When placing an immediate load implant, the implant must be placed with primary stability in an ideal position for an ideal restoration. The main problems clinicians encounter is that frequently the anatomy or the quality of the bone does not suit the clinical ability to gain primary stability, Cooper says.

¹² Degidi M, Piatelli A. 7-year follow-up of 93 immediately loaded titanium dental implants. *J Oral Implantol*. 2005;31(1):25-31.



edentulism (ie, single tooth, full-mouth, partially edentulous), Ganeles explains.

“Most of the information available about immediate loading has been for patients who are edentulous in the lower jaw,” Ganeles explains. “So, many people thought that if you’re going to do an immediately loaded implant that this was the only kind of patient you should treat this way.”

MYTH: Immediate loading of dental implants is difficult restoratively.

REALITIES: According to Sonick, temporaries used in these situations may be made ahead of time, and most implant systems now offer easy-to-follow kits and parts specifically for this procedure. Preformed crowns and abutments may be used so that clinicians do not have to take an extra implant-level impression, he says.

“Basically, if you know how to make a temporary crown for a prepared tooth, you will find that the process for implants is as simple or even easier,” Sonick says. “Often, immediate temporization is straightforward enough for surgeons to complete. It is possible also to use the tooth the patient came in with as a temporary cemented onto a transitional abutment.”

MYTH: Only very healthy or young patients can benefit from immediate loading or can be treated predictably with immediate loading.

REALITY: According to Ganeles, the demographic, age and health requirements of patients undergoing immediate loading procedures are not that stringent, provided other requisite factors are controlled (eg, bone density, occlusion, soft tissue health, home care ability). “Anybody who is healthy enough to have implant surgery can also have immediate loading accomplished,” Ganeles says.

MYTH: Only specialists should perform immediate loading of dental implant procedures.

REALITIES: There are general dentists who are experts in all phases of

implant placements and provide beautiful work, Krauser says, and there are specialists that may perform average work even though they’re specialists. The high degree of skill and precision comes from each individual working alone or as a team, he explains. These practitioners’ skill sets vary, and not necessarily in a straight line. Only qualified, well-trained and skilled colleagues should perform these procedures, Krauser emphasizes.

According to Cooper, immediate loading procedures are performed extremely well by teams of clinicians in which a surgeon or surgical specialist, a periodontist or an oral surgeon, and a restorative specialist—either a prosthodontist or a very experienced restorative dentist—work together with a radiologist who’s provided them with advanced biometric images of the patient to plan the case. He says that if an individual wants to pursue the immediate-loading scenario, doing so is well served by obtaining specialty or advance training.

“In modern dentistry, the collaborative approach is a must, because there are very few individuals that can perform all phases of dentistry to the highest quality,” Bichacho explains. “All treatment modalities progress, so you need to invest time to stay on the cutting edge of those treatment modalities. So in general, a collaboration between different specialties is a must today in order to provide the best treatment.”

CONCLUSION

According to Julian, it’s important for dentistry to educate general dentists about placing implants themselves in order to have the vision necessary to diagnose, treatment plan, and restore correctly cases for which an implant(s) may be an appropriate treatment modality.

“You can’t ignore it, and the less you know, the less you’ll do for your patients,” Julian cautions. “The more you learn, the more patients that could benefit from implants will be diagnosed and have the opportunity to have implants placed. That

means more referrals to surgeons and to specialists, and the dental community can work together much better.”

And among the implant procedures available is immediate loading. Sonick emphasizes that, if executed properly—with non-functional temporization, correct surgical placement, no cement left behind, proper emergence profile—immediately loaded implants represent a very nice service for patients. However, he cautions that

coordination and communication between restorative dentist and implant surgeon is mandatory.

“Every once in a while we encounter a patient whose life we can transform by providing them with an immediate-loading procedure,” Ganeles says. “That’s the reason you do it, and that’s the bottom line. There is real power in these kinds of procedures to change people’s lives, and everything else is just fluff.”

THE *Inside Look* FROM...

Issue after issue, the feature presentations in Inside Dentistry deliver coverage of the relevant and thought-provoking topics specifically affecting the dental profession, as well as oral healthcare in general. The publishers and staff could not bring the underlying concerns surrounding these timely issues to the forefront without the insights shared by our knowledgeable and well-respected interviewees. For their collective generosity of time and perspectives, we extend our sincere gratitude.

Nitzan Bichacho, DMD

Professor, R.E Goldstein Center for
Aesthetic Dentistry and Clinical Research
Department of Prosthodontics
Hebrew University
Hadassah, Jerusalem
Sylvia@bichacho.net

Robert Chapman, DMD

Chair, Prosthodontics & Operative Dentistry
Tufts University School of Dental Medicine
robert.chapman@tufts.edu

Lyndon F. Cooper, DDS, PhD

Chair and Graduate Program Director
Stallings Distinguished Professor of Dentistry
Department of Prosthodontics
University of North Carolina School
of Dentistry
Lyndon_Cooper@DENTISTRY.UNC.EDU

Jeffrey Ganeles, DMD

Adjunct Associate Professor
Nova Southeastern University College of
Dental Medicine
Fort Lauderdale, Florida
Private Practice
Florida Institute for Periodontics &
Dental Implants
Boca Raton, Florida
jganeles@perio-implant.com

David Garber, DMD

Private Practice and member of
“Team Atlanta”
Atlanta, GA
dgarber@goldsteingarber.com

Jon Julian, DDS

Private Practice
McPherson, Kansas
jk@mcphersondentalcare.com

Jack Krauser, DMD

Private Practice
Boca Raton, Florida
jtkrauser@aol.com

Carl E. Misch, DDS, MDS

Director & Founder, Misch Implant Institute
Co-Chairman of the Board, International
Congress of Oral Implantologists
Director of Oral Implantology & Professor
Temple University School of Dentistry
info@misch.com

Henry Salama, DMD

Private Practice and member of
“Team Atlanta”
Atlanta, GA
Hsalama@aol.com

Michael Sonick, DMD

Private Practitioner and Lecturer
Fairfield County Implants and
Periodontics, LLC
mike@sonickdmd.com

“HIGHLY SKILLED PEOPLE HAVE
WORKED A LONG TIME TO LEARN HOW TO
DO THIS, AND THE SIMPLICITY OF THE
APPEARANCE BELIES YEARS OF EXPERIENCE
AND A GREAT DEAL OF PLANNING.

—LYNDON COOPER, DDS, PHD