

“Implant placement requires
a 3-dimensional mindset...”

The Maxillary Central Incisor Implant: A Guide for Ideal Esthetic Implant Placement

Michael K. Sonick, DMD

The surgical success of dental implants has become quite predictable.¹ It is no longer enough to merely achieve osseointegration in dental implant therapy. Patients require implants that are esthetic as well as functional. The responsibility to deliver an ideal esthetic implant restoration begins with the surgeon.

Replacing a hopeless tooth presents a number of options for the clinician. Treatment options include a fixed, bonded partial denture; a fixed, tooth-supported bridge; a removable partial denture; and a dental implant. Fixed and removable partial dentures are wrought with problems. Implant restorations are often chosen for the following reasons:

- They are non-removable and permanent.
- Adjacent teeth are preserved.
- The success rate is significantly higher than for a fixed bridge.
- The strength of the restoration is increased.
- The case is segmented.
- Extraction site bone is preserved and stabilized.
- The patient is able to floss.
- Cosmetics are enhanced.
- Future dental costs are decreased.²

Once a treatment plan is selected, the sequence of treatment must be determined. Many options exist, and there is no 1 correct sequence in implant treatment planning. Questions must be answered

prior to performing any implant treatment, and they include, but are not limited to, the following:³

1. When do you place the implant: immediately, 2-months post-extraction, or 6-months post-extraction?
2. Is bone grafting needed?
3. What do you graft with: autograft, allograft, synthograft, or xenograft?
4. When do you graft: at extraction, 2-months post-extraction, or at the time of implant placement?
5. Is it done as a single stage or 2-stage procedure?
6. How many months do you wait for osseointegration?
7. When do you perform second-stage surgery?
8. How long thereafter do you begin the restoration process?
9. Is a provisional restoration needed?
10. If a provisional is used, how long do you keep the patient in a temporary?

The scope of this article cannot adequately answer all of these questions. Rather, 1 case (e.g., the extraction and replacement of a single hopeless central incisor with a dental implant) will demonstrate the options that were chosen to achieve an esthetic restoration. The replacement of a single tooth implant is one of the greatest challenges in restorative dentistry.⁴ The rationale for these decisions will be explored.

CASE PRESENTATION

The patient presented with a failing endodontically treated central incisor (Figure 1). The apicoectomy failed, and the tooth had an acute abscess and a fistula. Radiographically, she presented with a mutilated, shortened root (Figure 2). She expressed high cosmetic demands and refused to have her teeth prepared for a 3-unit bridge, or wear a removable partial denture as a permanent solution.

The treatment plan was as follows:

1. Extract, bone graft and provisionalize.
2. Heal for 2 months.
3. Place dental implant.
4. Heal for 2 months.
5. Expose implant and place a temporary healing abutment.
6. Perform guided gingival growth (non-surgical gingival graft).
7. Place permanent abutment and provisionalize.
8. Modify the temporary to achieve soft tissue maturation.
9. Take final impressions.
10. Deliver the final restoration.

Extraction and Grafting

Step 1 requires an atraumatic extraction of the central incisor. The extraction site was degranulated. All soft issue was removed in order to favor the in-growth of new bone. A freeze-dried mineralized or demineralized bone graft was placed into the socket, and a bovine collagen plug was placed and closed with resorbable sutures (Figure 3).

The purpose of the graft is twofold: soft tissue in-growth is delayed and bone regeneration is favored; and the site plumped out, yielding a greater volume of tissue in which to place the implant in 2 months. The collagen membrane serves to maintain the graft and acts as a “poor man’s membrane” to retard epithelial down growth. While this is not the ideal form of bone regeneration, it does yield an increased amount of bone, especially in enclosed extraction site defects with intact labial plates, as seen in this patient.⁵

Heal for 2 Months

Healing was rapid once the infection was removed (Figure 4). At 2 months post-extraction, soft tissue maturation was achieved, and an adequate volume of bone existed for the placement of the implant (Figure 5). Note that the papillae adjacent to the extraction site were present despite the absence of contact points. This is due to sufficient bone to support the soft tissue. Delaying implant treatment for 2 months also allowed for

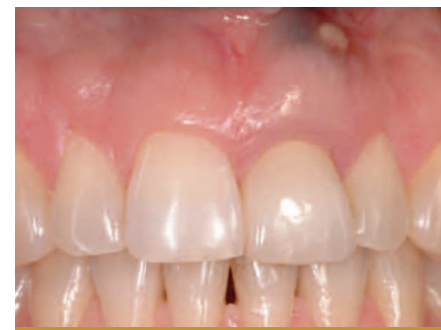

Figure 1 Initial presentation. Tooth # 9, the left maxillary central incisor, has a fistula due to a failing apicoectomy. Note the discolored gingival tissues.

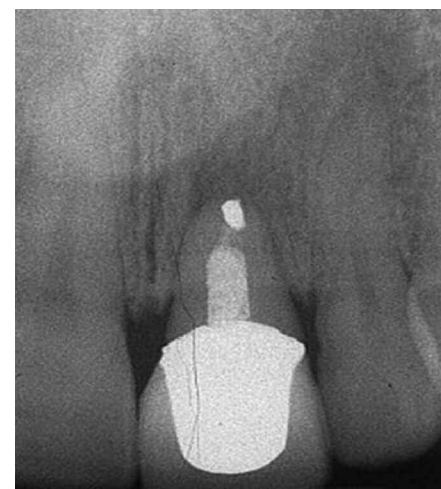

Figure 2 Radiograph of the failed apicoectomy. Truncated root and apical radiolucency are evident. The prognosis is hopeless.

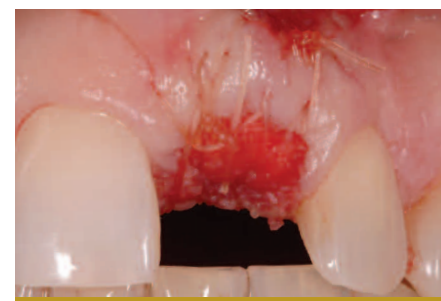

Figure 3 The tooth was extracted atraumatically. Following degranulation, freeze dried demineralized bone allograft was placed with a bovine collagen plug. The collagen helped contain the graft and served as a barrier membrane, as well as a hemostatic agent.

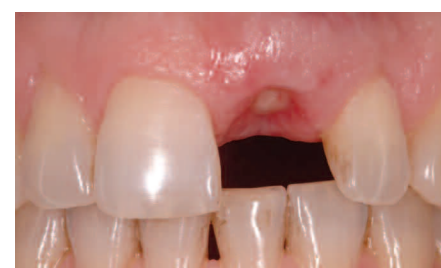

Figure 4 Two weeks post-extraction. Excellent healing and formation of anatomy to support the future implant is evident.



Michael K. Sonick, DMD

*Diplomate, American Board of Periodontology
Private Practice of Periodontics and Dental Implants
Fairfield, CT
Email: boomerdent@aol.com*

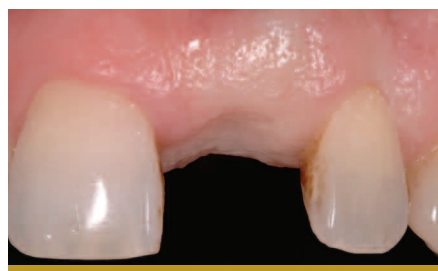

Figure 5 Healing 2 months following extraction. Note retention of papilla. Labial gingival contour has been preserved.

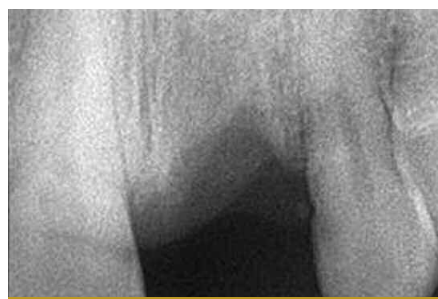

Figure 6 Radiograph at 2 months following extraction, the day of implant surgery. Bony healing appears to be proceeding nicely.

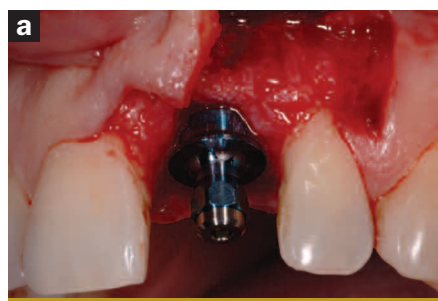


Figure 7a Labial view of the flap design and implant placement. Vertical incision was made 1 tooth distally on the interradicular bone at a right angle to the bone. The vertical incision connected horizontally at a right angle at the level of the gingival sulcus. Note the 3-dimensional position of the implant. It is slightly distal and 3 mm from the anticipated dento-gingival junction.

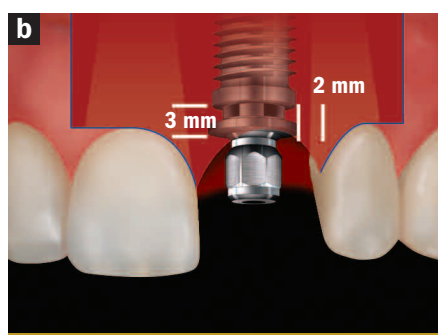


Figure 7b The incision design began 1 tooth mesial and distal to the implant site with a vertical incision that extended from the alveolar mucosa to the height of gingival contour. It extended intrasulcularly to the palatal line angles of both teeth and connected horizontally across the palate. Note the implant position is 3 mm from the anticipated dento-gingival junction and 2 mm from the adjacent teeth.

soft tissue maturation. Since an immediate implant was not performed, primary closure at the time of extraction was not necessary. Therefore, a free gingival graft was not necessary, and there was no distortion of the gingival architecture in an attempt to achieve primary closure.

Dental Implant Placement: Incision Design and Implant Alignment

The radiograph taken at 2 months post-extraction (Figure 6) revealed adequate bone in a mesial-distal and occlusal-apical direction. Bony fill was intimated in the space previously occupied by the tooth root. Given the excellent healing response of the patient, it was decided to proceed with dental implant placement.

The incision design enabled visualization of the buccal plate, without causing gingival recession over the adjacent teeth or papillary loss. A vertical incision was made over the interradicular bone, 1 tooth distal to the implant site (Figures 7a and 7b). A sharp incision was made perpendicular to the bone, extending from the alveolar mucosa to the height of gingiva of the adjacent tooth. A secondary incision began at a right angle to the vertical incision and continued into the sulcus of the tooth adjacent to the implant site. The incision was carried interproximally into the sulcus to the palatal line angle of the tooth. At the palatal line angle, the incision made a 90° turn to connect horizontally with the palatal line angle of the other tooth adjacent to the implant site (Figure 8). The incision was carried intrasulcularly through the interproximal and buccal sulcus. If necessary, a second vertical incision could have been made in the same place on the contralateral side. This would only be necessary when extensive bone grafting, visualization, and reflection are required.

Following completion of the incision to bone, a full-thickness flap was reflected buccally. Full-thickness flap reflection was necessary to visualize bony anatomy. Without flap reflection, fenestrations and dehiscences go undiagnosed, leading to less bone-to-implant contact. The opportunity to graft these areas at implant surgery is lost if a flap is not elevated. It is the author's opinion that flapless surgery is difficult and rarely indicated because it "handcuffs" the surgeon and frequently results in less than optimal regenerative treatment.

Implant placement requires a 3-dimensional mindset: mesial-distal, buccal-palatal and occlusal-apical.^{6,7}

Mesial-distal

The gingival zenith (i.e., most apical point of gingival tissue) of the maxillary central incisors is located distal to the long axis of the tooth.⁸ Therefore, placement of the maxillary central incisor is slightly distal to the midline of the tooth. Also, the nasal palatine foramina frequently dictates distal placement to avoid hitting the nerve. The clinician should attempt to keep the implant 1.5 mm to 2.0 mm from adjacent teeth (Figures 7a, 7b, and 8) so that bone may be preserved, leading to retention of the papillae.^{7,9}

Buccal-palatal

Ideal implant placement is slightly palatal to the palatal-incisal line angle (Figure 8). This creates a proper buccal emergence

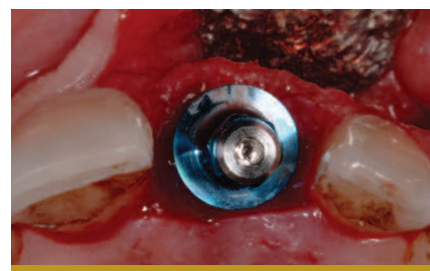


Figure 8 Occlusal view of implant placement. The implant is slightly palatal to the palatal incisal line angle so that proper emergence profile is achieved. Note the palatal incision to preserve labial tissue. Labial plate of bone has also been preserved by judicious extraction and grafting procedure.

profile. If the implant is angled palatal to this line, a ridge lap restoration may be necessary. Conversely, angling the implant too labially will result in a loss of labial gingival height and an uneven gingival margin.

Occlusal-apical

Ideal position is 3 mm to 4 mm from the "anticipated" dento-gingival junction (Figures 7a and 7b).¹⁰ This provides room to develop a proper emergence profile, or running room. Deeply placed implants are difficult to clean and may trap debris or excess cement. Shallow implants are at risk of exposure and may not allow adequate space for a properly formed restoration.

Second-stage Surgery

The implant was allowed to heal for 2 months before exposure. Second-stage surgery presents the surgeon with an opportunity to increase tissue thickness, increase keratinized gingiva and provide proper ridge contour. The incision connected the interproximal-palatal line angles of the adjacent teeth and extended interproximally (Figures 9a, 9b, and 10). This allowed the flap to be raised buccally, creating additional gingival tissue without the need for a gingival graft. A titanium temporary healing abutment was placed, and the gingiva was pulled coronal to the abutment and secured with 2 resorbable (gut) sutures (Figure 11).

Guided Gingival Growth

Titanium is "gingiva loving." Gingiva will grow to completely cover a titanium temporary healing abutment if placed slightly coronally (Figure 12). This technique is used when gingival tissue is desired (Figures 11 and 12). The author has called this a "non-surgical gingival graft" because the body creates additional gingiva without the need for performing gingival surgery. A certain amount of recession is anticipated the first year after the implant restoration.¹¹ Therefore, it is recommended to over build up the gingival tissue by 25%.¹² It is always easier to subtract than to add.

Permanent Abutment Placement and Provisionalization

Four weeks after uncovering the implant and "non-surgical gingival grafting," an

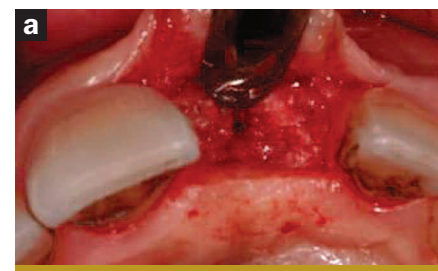


Figure 9a Implant exposure and second-stage surgery. Initial incision was made from palatal line angle to palatal line angle of the adjacent teeth. Note the volume of gingival tissue that is displaced labially, allowing for additional gingival augmentation. Note the amount of bone covering the dental implant.

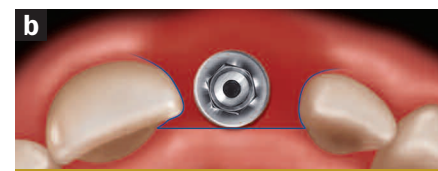


Figure 9b Incision for second-stage surgery was palatal connecting the palatal line angles of the teeth adjacent to the implant site. It then extended intrasulcularly to the buccal line angles of the teeth. The flap was then reflected labially and created a volume of tissue to be moved labially, which added additional bulk to the labial profile of the implant.

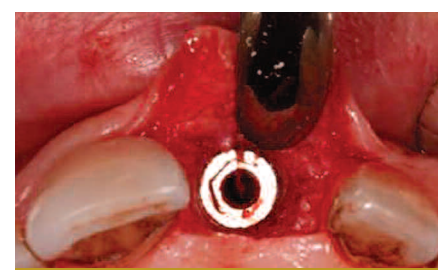


Figure 10 Occlusal view of implant at second-stage surgery after removal of the cover screw and bone profiling.

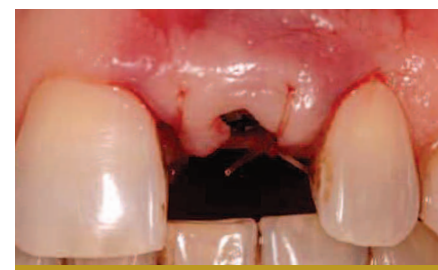

Figure 11 Suturing with gut during second-stage surgery after placement of the titanium temporary healing abutment. Gingiva is placed labially and coronally elevated over the temporary healing abutment to achieve even more gingival growth (e.g., a non-surgical gingival graft).

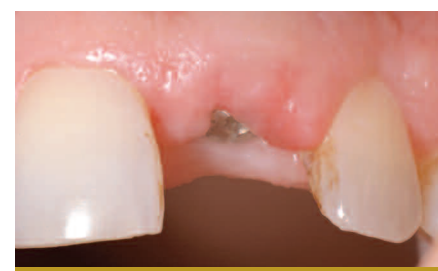

Figure 12 Two weeks post-exposure, the temporary healing abutment is almost completely covered by the gingiva. Additional gingival augmentation has been achieved labially and coronally.

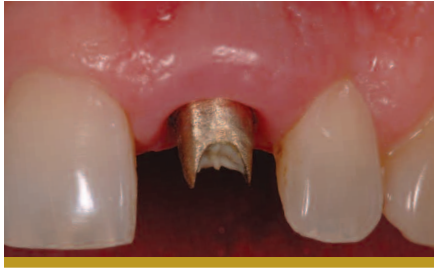

Figure 13 A permanent abutment has been fabricated. Note the labial gingival profile. Augmentation makes it appear as if there is a root prominence.

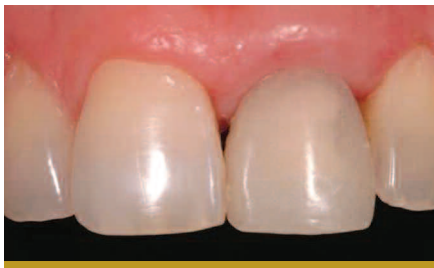

Figure 14 Immediate acrylic provisionalization of the permanent abutment. Papillae have not yet formed between teeth #8 and #9 and #9 and #10.

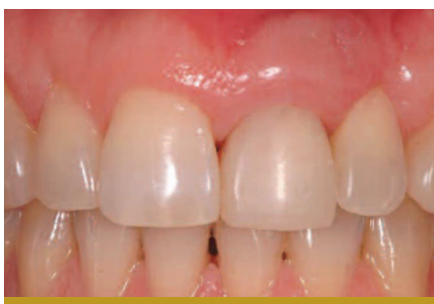

Figure 15 The provisional restoration has been in place 3 weeks. Note that the papillae are almost completely formed. The patient is almost ready for the final impression.

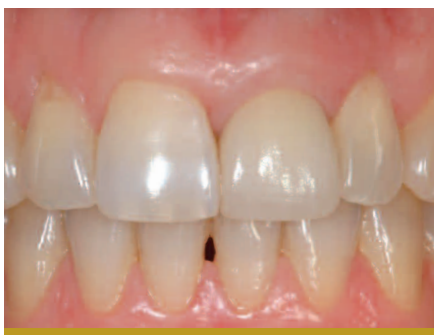

Figure 16 Final implant restoration of tooth #9, the maxillary left central incisor. Compare to Figure 1. Note gingival harmony, papillae reformation, absence of the fistula, and improvement of the color of the gingiva.

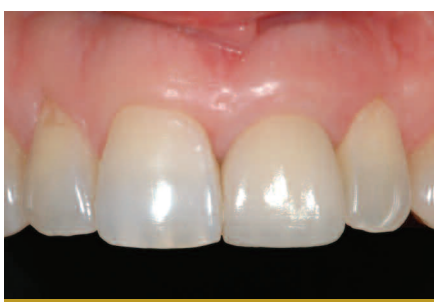

Figure 17 Final implant restoration of tooth #9. Restoration courtesy of Dr. Ira Novsam, Westport, CT.

implant level impression was taken, and a gold GingiHue™ Post (Implant Innovations Inc, Palm Beach Gardens, FL) was fabricated (Figure 13). A provisional restoration was made and cemented with temporary cement (Figure 14).

Modification of the Temporary to Achieve Soft Tissue Maturation

All implants in the esthetic zone are provisionalized, which enables the clinician to refine the esthetics prior to fabricating the final restoration. The patient also has the opportunity to approve the restoration at this time. Acrylic can be added or subtracted in an attempt to guide the formation of the papillae and develop the proper emergence profile. A papilla will form if the contact point of the provisional is within 4 mm to 5 mm of the alveolar bone (Figure 15).^{7,13} It is not uncommon to keep the patient in the provisional for 3 months before the final impression is made.

Delivery of the Final Restoration

The final restoration was a recapitulation of the provisional restoration. A comparison of the final restoration to the initial tooth revealed little difference in shape and soft tissue architecture (Figures 1, 16, and 17). One month after the placement of the final restoration, excess labial gingiva was seen on the implant restoration when compared to the contralateral natural central incisor (Figures 16 and 17). At 1 year, if the patient is not satisfied with the excess gingival tissue, it can be easily removed to achieve symmetry.

CONCLUSION

This case serves as a guide by which to perform an ideal esthetic maxillary central incisor implant restoration. The concepts provided are proven and supported by both clinical experience and evidence-based literature. However, there are many treatment alternatives available today that would have achieved a similarly satisfactory esthetic result, and there are advantages and disadvantages to each. Each treatment scenario presents unique challenges and opportunities for clinicians to serve our patients with ideal esthetic, functional and long-lasting implant dentistry. It is up to the individual clinician to explore the various treatment options and decide which works most predictably and easily so that patients will be better served.

REFERENCES

1. Adell R, Eriksson B, Lekholm U, et al. Long-term follow-up study of osseointegrated implants in the treatment of totally edentulous jaws. *Int J Oral Maxillofac Implants.* 1990;5(4):347-359.
2. Priest, G. The economics of implants for single missing teeth. *Dental Economics.* 2004;94(5):130-8.
3. Sonick M. Bone sculpting to achieve papilla regeneration around dental implants. *Contemp Esthet Restor Pract.* 2002;6(6):46-53.
4. Jansen CE, Weisgold A. Presurgical treatment planning for the anterior single-tooth implant restoration. *Compend Contin Educ Dent.* 1995;16(8):746-61.
5. Fugazzotto P. Treatment options following single-rooted tooth removal: a literature review and proposed hierarchy of treatment selection. *J Periodontol.* 2005;76(5):821-31.
6. Sonick M. Hard and soft tissue regeneration for implants in the esthetic zone. *Contemp Esthet Restor Pract.* 2001;5(10):64-76.
7. Grunder U, Gracis S, Capelli M. Influence of the 3-D bone-to-implant relationship on esthetics. *Int J Periodontics Restorative Dent.* 2005;25(2):113-19.
8. Rufenacht CR. *Fundamentals of Esthetics.* Chicago: Quintessence Pub Co. 1990;127.
9. Esposito M, Ekkestubbe A, Grondahl K. Radiographic evaluation of marginal bone loss at tooth surfaces facing single Branemark implants. *Clin Oral Implants Res.* 1993; 4(3):151-7.
10. Parel S, Sullivan D. *Esthetics and Osseointegration.* Osseointegration Seminars, Inc. Dallas: Taylor Publishing Company; 1989.
11. Small PN, Tarnow DP. Gingival recession around implants: a 1-year longitudinal prospective study. *Int J Oral Maxillofac Implants.* 2000;15(4):527-32.
12. Jovanovic SA, Paul S, Nishimura R. Anterior implant-supported reconstructions: a surgical challenge. *Pract Periodontics Aesthet Dent.* 1999;11(5):551-8.
13. Tarnow DP, Cho SC, Wallace SS. The effect of inter-implant distance on the height of inter-implant bone crest. *J Periodontol.* 2000;71(4):546-9.