

# Two-stage esthetic crown lengthening

Author\_Michael Sonick, DMD, Stephen Rothenberg, DMD, and Debby Hwang, DMD

**\_A smile that is perceived as unattractive mars confidence, sociability and self-regard.** For some patients, the lack of visual appeal stems in large part from a gummy smile, which a layperson begins to consider disharmonious when there is 3 to 4 mm of gingiva displayed.<sup>1</sup> Management of such a complaint often entails both periodontal and restorative therapy, if not also orthognathic surgery and facial plastic procedures.

The following report showcases two-stage esthetic crown lengthening and prosthetic rehabilitation for the treatment of a gummy smile.

## \_Treatment plan

- Consult with oral and maxillofacial surgeon regarding orthognathic surgery
- Consult with facial plastic surgeon regarding lip lowering therapy
- Consult with restorative dentist regarding ideal tooth shape setup and fabrication of surgical guide
- Two-stage esthetic crown lengthening from tooth #4 to #13
- **First stage:** osseous recontouring
- Six-week healing period
- **Second stage:** gingivectomy
- Three-month healing period
- Final porcelain veneer restorations for teeth #4 through #13
- Delivery of maxillary occlusal bite guard

## \_Treatment plan rationale

Ideal treatment for the patient with vertical maxillary excess embraces a host of dental and medical specialties. In such a case as this, in which the patient demonstrates up to 7 mm of gingival display, LeFort I maxillary impaction may further refine results if conventional crown lengthening insufficiently elevates the periodontal margin, creates an unacceptable crown-to-root ratio

## \_Patient history

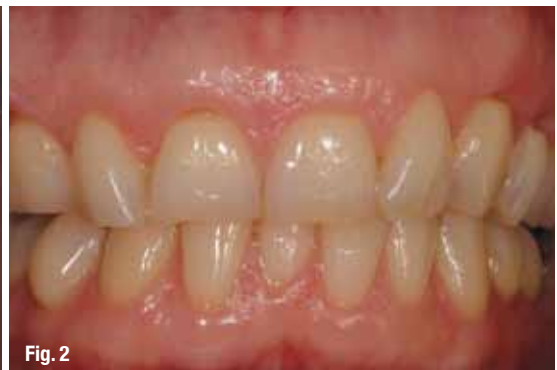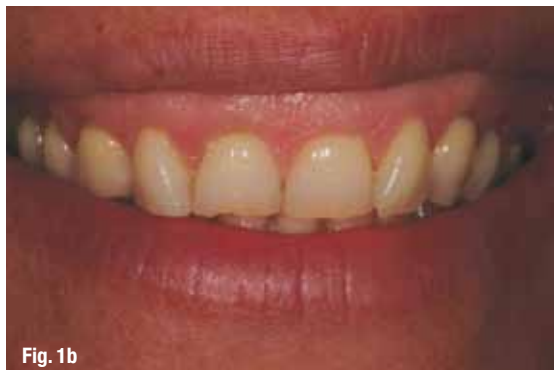A medically and periodontally stable 40-year-old female presented with excessive, asymmetric gingival display of 5 to 7 mm upon smiling, short clinical crowns and incisal wear from tooth #4 to #13 (Figs. 1, 2). Due to attrition and the relationship between the dentition and periodontal drape, the anterior teeth appear square-shaped and "masculine."

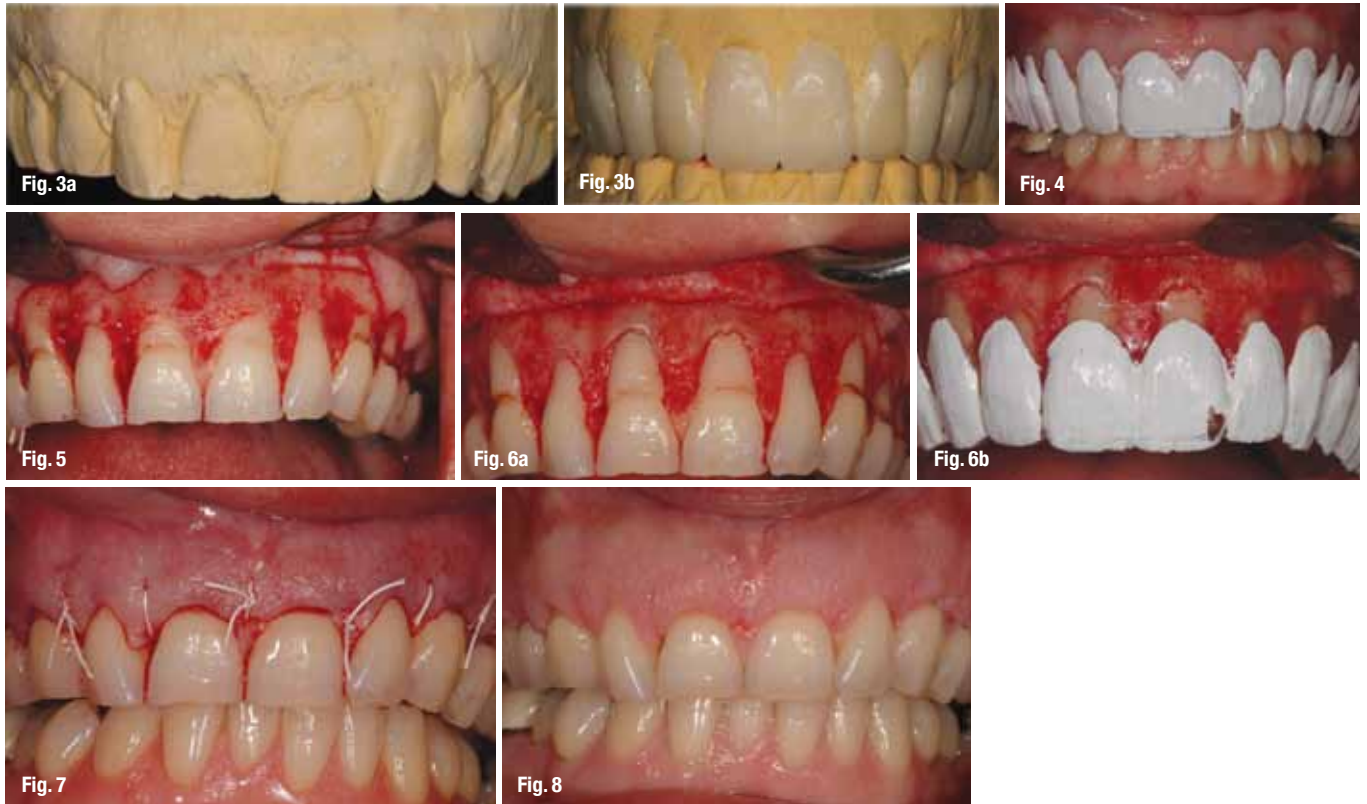Diagnoses included: (1) Coslet Type IA altered passive eruption, evidenced by a wider-than-customary dimension of keratinized gingiva and an alveolar crest at least 1.5 apical to the cemento-enamel junction (CEJ); and (2) vertical maxillary excess.<sup>2,3</sup> The patient also shows a thick tissue biotype.

**Fig. 1a** Initial facial presentation of patient who exhibits a gummy smile (up to 7 mm of soft-tissue display) and vertical maxillary excess. (Photos/Provided by Dr. Michael Sonick, et al.)

**Fig. 1b** Initial view of maxillary anterior teeth upon smiling. The clinical crowns appear short and demonstrate attrition.

**Fig. 2** Excessive keratinized gingiva, a thick soft-tissue biotype and asymmetric gingival contours exist.





or precludes achievement of a natural-seeming emergence profile due to exposure of excessive radicular structure.<sup>3</sup>

Likewise, neuromuscular relaxation of the upper lip by botulinum toxin type A (BTX-A) depresses the lip, and thus masks any mucosal surplus left after periodontal surgery.<sup>4</sup>

As the patient declined orthognathic and facial plastic therapy, the treatment rendered to alleviate her gummy smile and re-establish tissue and dental symmetry included a two-stage crown lengthening procedure followed by delivery of porcelain veneers from tooth #4 to #13.

A biphasic crown lengthening approach minimizes the 1 to 3 mm coronal gingival shifts common after one-stage procedures detected especially in patients with thick soft-tissue biotypes (such as the patient featured in this report).<sup>5</sup>

By first reshaping only the osseous crest and letting healing commence, it is possible to correct any coronal rebound of the soft tissue seen after healing at the second, gingivectomy-only, surgery.

Once the attachment apparatus fully remodels post-gingivectomy, which takes roughly three months, final restorations may be cemented.

### Restorative consult

From the diagnostic models, the patient's prosthodontist created an ideal dental wax-up, upon

which a vacuform matrix was applied to generate a surgical guide (Figs. 3, 4).

### Osseous recontouring (first stage)

The first stage of biphasic crown lengthening of teeth #4 through #13 involved only osseous resection. The patient took 0.25 mg oral triazolam and 600 mg ibuprofen one hour before surgery. Anesthesia with 2 percent lidocaine with 1:100,000 epinephrine and 0.5 percent bupivacaine with 1:200,000 epinephrine was given via local infiltration.

A buccal sulcular incision was made extending from tooth #4 to #13, and vertical incisions were dropped at the mesio-buccal and disto-buccal line angles of teeth #4 and #13. A full-thickness flap was elevated (Fig. 5).

Osteotomy was performed using an Ochsenbein chisel, carbide finishing bur and Neumeier bur to position the alveolar crest at least 3 mm from the anticipated restorative margin at each site, as verified by the surgical guide (Fig. 6).

The bone was gradualized such that no sharp edges or bulbous areas existed, and positive architecture was preserved.

The flaps were replaced and sutured in sling fashion with 4-0 expanded polytetrafluoroethylene (ePTFE) (Fig. 7). The gingival height and shape post-surgery appeared similar to that found before surgery, even 10 days after intervention (Fig. 8).

**Fig. 3a** The maxillary diagnostic model.

**Fig. 3b** Ideal wax-up created on the diagnostic model.

**Fig. 4** Surgical guide in place in the mouth. The ideal tooth contours are shaded in white.

**Fig. 5** Initial full-thickness flap reflection at first stage surgery. Note the apical level of the alveolar crest compared to the cemento-enamel junction.

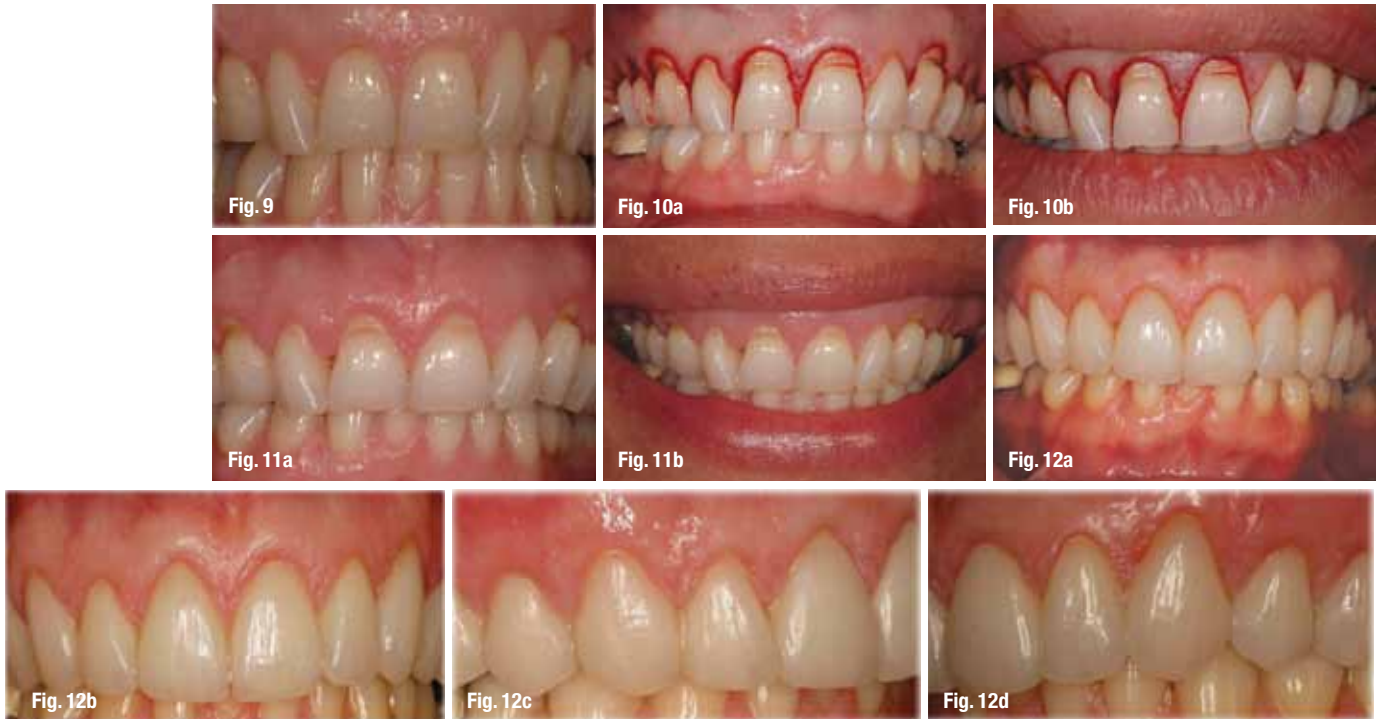**Fig. 6a** Final bone contours after osteotomy.

**Fig. 6b** The final osseous contour lies at least 3 mm from the anticipated restorative margins, as outlined by the surgical guide.

**Fig. 7** Sling sutures in place after osseous reshaping. Note the similarity in gingival height and morphology between pre-surgical and post-surgical views.

**Fig. 8** Healing 10 days after first stage crown lengthening. The periodontal level still approximates the initial presentation.

**Fig. 9** Healing six weeks after first stage of crown lengthening.



**Fig. 10a**\_Frontal view immediately after second stage gingivectomy.

**Fig. 10b**\_Positional relationship between the lip and gingival margin immediately after second stage gingivectomy.

**Fig. 11a**\_Frontal view four weeks after second stage gingivectomy.

**Fig. 11b**\_Positional relationship between the lip and gingival margin four weeks after second stage gingivectomy.

**Fig. 12a**\_Frontal view of final veneers (#4 through #13) three months after gingivectomy.

**Fig. 12b**\_Central view of final veneers (#6 through #11) three months after gingivectomy.

**Fig. 12c**\_Right lateral view of final veneers (#4 through #8) three months after gingivectomy.

**Fig. 12d**\_Left lateral view of final veneers (#9 through #13) three months after gingivectomy.

### Gingivectomy (second stage)

Once the soft tissue resettled six weeks post-osteotomy (Fig. 9), the second stage of biphasic crown lengthening of teeth #4 through #13 was executed. The patient was sedated and anesthetized as above.

A definitive external bevel gingivectomy of teeth #4 through #13 was performed with a #15 scalpel utilizing the surgical template to delineate the desired tooth contours (Fig. 10). The papillae were left intact and no sutures were required. Healing four weeks after the gingivectomy revealed a harmonious gingival drape (Fig. 11).

### Final prosthetics

Placement of final veneers on teeth #4 through #13 occurred three months post-gingivectomy (Fig. 12). An occlusal bite guard was delivered to protect the restorations. In order to correct lip line asymmetry and further diminish gingival display, neuromuscular lip correction (lowering) with BTX-A was reconsidered, but the patient did not pursue treatment.

Six years after veneer placement, the patient remained satisfied with the functional and esthetic result achieved solely through periodontal surgery and prosthetic rehabilitation (Figs. 13, 14).

### Postoperative instructions

After each surgical procedure, the patient was

instructed to take 600 mg of ibuprofen every four to six hours, hydrocodone 7.5 mg/acetaminophen 750 mg every four to six hours as needed for pain and 100 mg of doxycycline a day for 10 days.

The patient was instructed not to brush at or near the surgical site but instead to rinse with 0.12 percent chlorhexidine or warm saline twice daily. The patient was also directed not to chew in the affected area for at least two weeks. Suture removal occurred at 10 to 14 days post-surgery.

### References

1. Kokich VO, Kokich VG, Kiyak HA. Perceptions of dental professionals and laypersons to altered dental esthetics: asymmetric and symmetric situations. *Am J Orthod Dentofacial Orthop* 2006;130(2):141-51.
2. Coslet JG, Vanarsdall R, Weisgold A. Diagnosis and classification of delayed passive eruption of the dentogingival junction in the adult. *Alpha Omegan* 1977;70(3):24-8.
3. Garber DA, Salama MA. The aesthetic smile: diagnosis and treatment. *Periodontol* 2000 1996;11:18-28.
4. Polo M. Botulinum toxin type A (Botox) for the neuromuscular correction of excessive gingival display on smiling (gummy smile). *Am J Orthod Dentofacial Orthop* 2008;133(2):195-203.
5. Sonick M. Esthetic crown lengthening for maxillary anterior teeth. *Compend Contin Educ Dent* 1997;18(8):807-12, 14-6, 18-9; quiz 20.

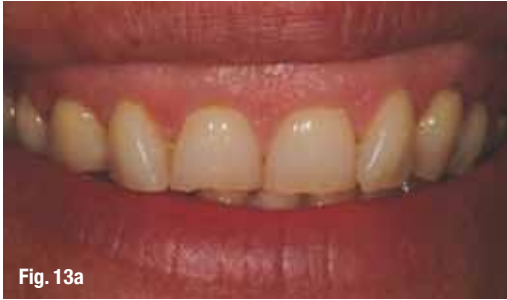

Fig. 13a

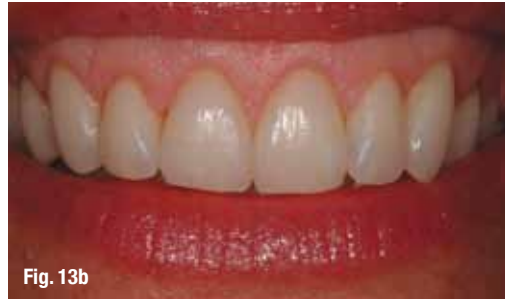

Fig. 13b

Fig. 13a\_Smile pre-treatment.

Fig. 13b\_Smile six years post-treatment.

Fig. 14\_Facial view six years post-treatment.



Fig. 14

\_about the author


cosmetic  
dentistry



*Periodontal surgeon:* Michael Sonick, DMD

*Restorative dentist:* Stephen Rothenberg, DMD

Dr. Michael Sonick is a full-time practicing periodontist and implant surgeon in Fairfield, Conn. He is on the editorial boards of many journals and is co-editor of the textbook "Implant Site Development." He is currently a guest lecturer at New York University School of Dentistry and is director of Sonick Seminars, in Fairfield, Conn. You may contact Dr. Sonick at [mike@drsonickdmd.com](mailto:mike@drsonickdmd.com).



Learn DR. BERLAND'S BIOMIMETIC APPROACH  
and improve your patient care & dental practice

SAVE your patient's TEETH, TIME & MONEY

Order the Same-Day Inlay/Onlay CD today!


\$44.00

all-inclusive


Earn 8 C.E. credits

Call 214.999.0110

BEFORE



AFTER



Dr. Lorin Berland has been internationally recognized for his expertise in cosmetic dentistry. He is a recipient of the AACD Award for Outstanding Contributions to Cosmetic Dentistry. Dr. Berland founded Berland Dental Arts, a multi-specialty group practice in Dallas, Texas.

LEARN MORE at [berlanddentalarts.com/dentalprofessionals](http://berlanddentalarts.com/dentalprofessionals)

AD